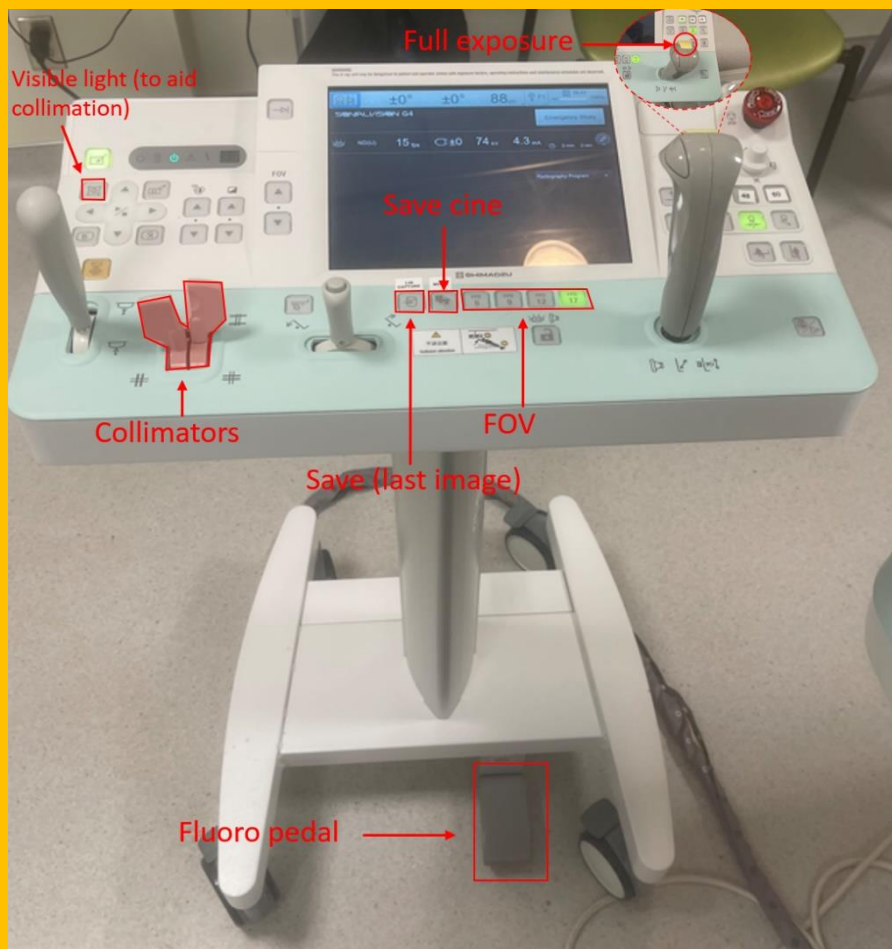


Peds Fluoroscopy Cheat Sheet

Please see Fluoroscopy Examples (Dr. Naheedy) document on RadRes for a detailed explanation with images

VCUG:

1. Early bladder filling (**AP - supine**)
2. Maximal bladder distension → **Bilateral Oblique views** +/- **AP**
3. Voiding → **oblique** in males, **AP** in females
4. Consider cycling if less than 1-year-old to improve sensitivity
5. Post-void → **AP full-exposure** including bladder and kidneys



Esophagram:

1. **AP + lateral views** of the entire esophagus

Upper GI:

1. Esophagram
2. Stomach & duodenum
 - **Supine lateral view** → to show opacification of C-sweep (2nd and 3rd portions of duodenum)
 - **AP view** → follow the bolus of contrast which should cross midline and course superiorly to the ligament of Trietz.

