Intro to Neuroradiology MRI

Luke Wojdyla, DO

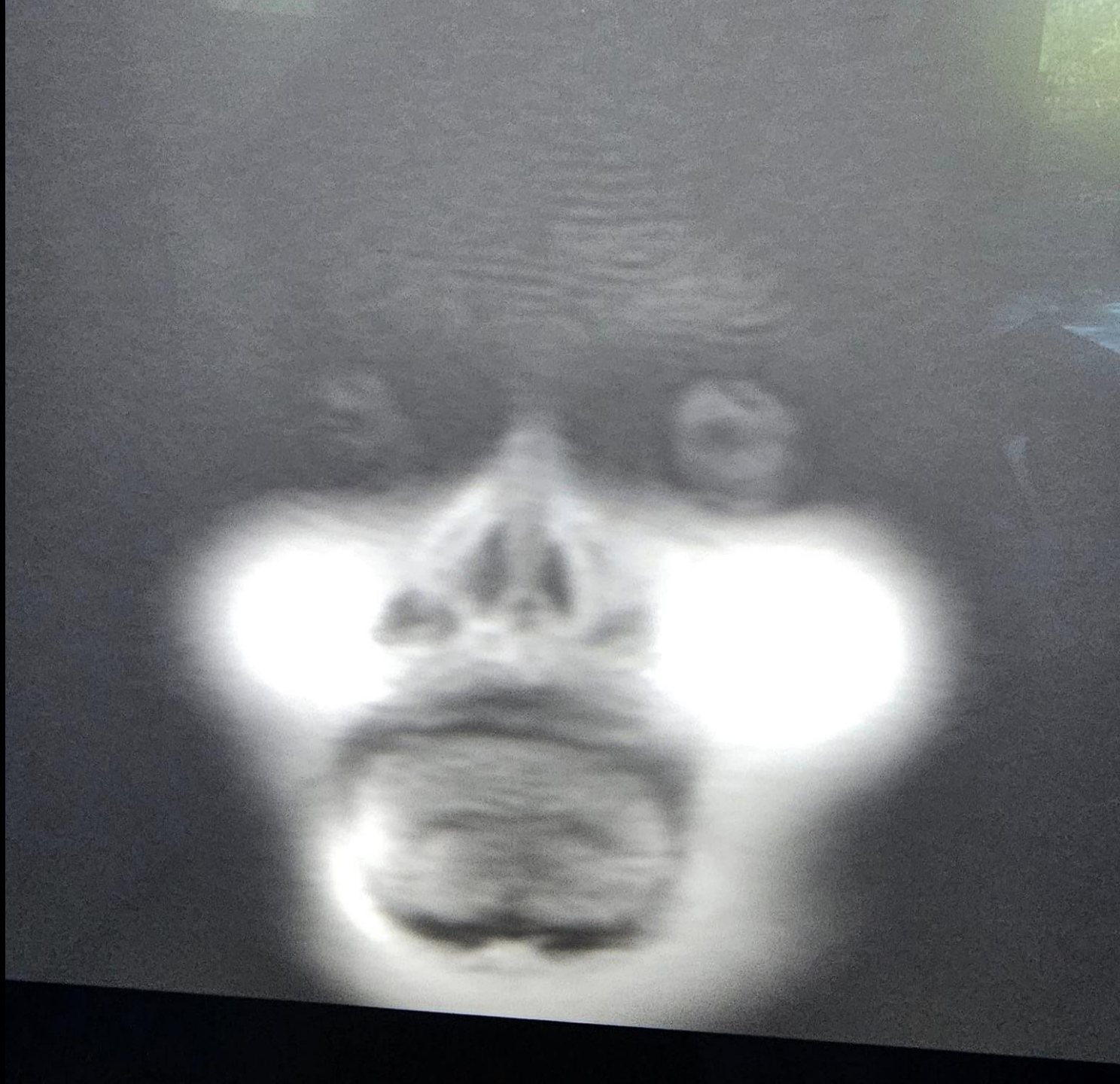

- Night Float Protocolling Cheat Sheet
- Techniques
- MRI protocols
- Magnets
- Cases

Night Float Protocolling Cheat Sheet

Table of Contents

Brain/Head:

- “Brain WO”
  - Most patients with the indication of "stroke", "TIA", "AMS", "focal neurologic deficits”
- "Acute Stroke”
  - Only when the "neuro stroke" team orders it (most “stroke” indications should instead be “Brain WO” above). Abbreviated protocol for patients eligible for intervention. Ordering team coordinate with the MRI techs, potentially pulling other patients off the scanner. No discussion b/t stroke team and radiologist needed, but rads can call MRI to give them heads up
- "Brain Tumor"
  - Primary CNS neoplasms work ups, such as glioblastoma, medulloblastoma (not meningioma!)
- “Brain mets”
  - Intracranial metastases, infection
- Brain mass status post resection
  - For brain masses in the immediate post-operative period (24-72 hours), a full “Brain Tumor” protocol is not necessary. There is no prebuilt “epic” protocol button for this, but you can choose “Brain Mets” sequence and add any additional sequences requested by ordering (eg, T2 CUBE)
- “Ant Skull Base + Sella”
  - Choose for all “MRI Brain + Sella” orders, all pre-op or immediate post-op studies for sella or anterior skull base masses.
  - Note: “MRI Sella” protocol is a distinct protocol appropriate for Brain and Sella orders to evaluate for pituitary microadenoma or cases that are NOT for preoperative evaluation.
  - Pituitary apoplexy should be MRI Sella
- “MS Brain” +/- contrast
  - Suspected demyelination (MS, NMO, MOGAD, ADEM)
  - MRI brain, orbits, cervical spine, and thoracic spine may all be appropriate depending on scenario. If concerned for an initial or acute (exacerbation), contrast may be appropriate. Can generally just defer these to whatever neurology wants at the given time.

Spine

- Contrast not needed for trauma or degenerative myelopathy. Contrast is useful for infection, sometimes when evaluating the post-operative spine (complications), neoplasm, and sometimes demyelination (MS).
- Non-contrast spines are often auto-protocolled, but techs may sometimes still ask you for guidance. In cervical spine there are 2 trauma protocols, one called a ”CCJ” (craniocervical junction) and the other “trauma”. ”Cervical CCJ” offers a dedicated look at the occipiut-C1-C2 complex, specifically to assess for ligamentous injuries, but takes longer to do. ”Cervical Trauma” can be used if injury on CT doesn’t include CCJ,
- “Spine Survey” (a modified combined Cervical, Thoracic, and Lumbar spine WO/W) should be used for metastases, non-localized infection, and acute myelopathy/cord compression. Not infrequently, ortho/neurosurg wants a dedicated look at one section (eg, dedicated lumbar spine) AND screen the rest of the spine. In this case, recommend speaking with technologists, can adjust field of view on spine survey so that the entire Cervical and Thoracic spine are included in the upper portion, and the lower portion is just the lumbar spine with added pre-contrast axial images (for lumbar spine, ax T2 and ax T1). Or can just do dedicated Cervical, Thoracic, and Lumbar spine WO/W, but many patients will struggle tolerating being in the scanner that long

MRA:

- For Brain, non-contrast are sufficient for intracranial aneurysm screening and LVO detection (eg, time of flight and phase-contrast techniques)
- For neck, specifically add “T1 fat-saturated black blood” sequence (a non-contrast technique) to assess for dissection
- Contrast useful for more accurate vessel lumen assessment (especially in the neck) for high-grade carotid stenosis, dissections, and aortic arch pathology, and can also be useful to characterize treated/coiled aneurysms to look for residual filling
- For aneurysms after surgical clipping, CTA is superior.
- For aneurysms after endovascular coiling, MRA is superior.

MRV

- For venous sinus thrombosis, contrast-enhanced is **strongly** preferred (push for this). Exception is pregnant patients, can only do non-contrast.

Table of Contents

Techniques/Abbreviations

1.5 vs 3 T

ASL: Arterial Spin Labeling

Black Blood T1 Fat-Saturated (dissection protocol)

BRAVO: Brain Volume Imaging

Brainlab: Surgical navigation system

Chemical Shift Fat Suppression

CISS (Constructive Interference in Steady State)

Contrast Enhanced Techniques

CUBE: Volumetric Isotropic Fast Spin Echo

DSC: Dynamic susceptibility contrast

DWI: Diffusion-Weighted Imaging

FIESTA: Fast Imaging Employing Steady-State Acquisition

FLAIR: Fluid Attenuated Inversion Recovery

FLEX: Fast Leveraged Excitation

FrFSE: Fast Recovery Fast Spin Echo

FSE: Fast Spin Echo

FSPGR: Fast Spoiled Gradient-Recalled

FLASH: Fast Low Angle Shot (FLASH, Siemens)

InHance 3D Velocity: 3D phase contrast MR angiography

LAVA: Liver Acquisition with Volume Acceleration

MARS: Metal Artifact Reduction Sequences

MSDE: Motion-Sensitized Driven Equilibrium

MERGE: Multi-Echo Recombined Gradient Echo

MP-RAGE: Magnetization-Prepared Rapid Acquisition Gradient Echo

MUSE: Multiplexed Sensitivity-Encoding

PROPELLER (PROP): Periodically Rotated Overlapping Parallel Lines with Enhanced Reconstruction

SPACE: Sampling Perfection with Application-optimized Contrasts using different flip angle Evolutions

STIR: Short TI Inversion Recovery

SWAN: Susceptibility-Weighted Angiography

TIRM: Turbo Inversion Recovery Magnitude

TOF: Time of Flight

TRICKS: Time-Resolved Imaging of Contrast Kinetics

VIBE: Volumetric Interpolated Breath-hold Examination

Table of Contents

UCSD Magnets

- ACTRI
  - 3T GE Signa
- CTIPM1 MR0OW4
  - 3T GE Signa
- EC
  - 1.5T Siemens Symphony
- El Centro Regional Medical Center
  - 1.5T GE Artist
  - 1.5T GE HDxt
- HC MR3
  - 1.5T GE Signa (HDXT?)
- HC MR4
  - 3T GE Discovery
- HC HCOPCANMR1
  - 3T Canon Galon
- McG OPP 1
  - 3T Siemens Magnetom Vida
- McG OPP 2
  - 3T Siemens Magnetom Vida
- KOP MR1
  - 3T GE Signa Premier
- KOPMR2
  - 3T GE Signa Premier
- La Jolla (URLJ)
  - 1.5 T GE Signa HDXT
- TH TMR
  - 1.5T GE Signa (HDXT?)
- TH Mobile
  - 1.5T Siemens Magnetom Aera

Table of Contents

UCSD Neuroradiology MRI protocols

Brain

- Acute Stroke
- Brain WO
- Brain +C
- Brain Mets
- Brain Tumor
- Brain epilepsy W/WO
- Ant Skull Base + Sella
- MS W/WO contrast

Vascular

- Head MRA
- Head MRV
- Neck MRA
- Spine MRA

Head and Neck

- Face
- Neck
- Sella/Pituitary
- Orbits
- IAC W/WO
- Trigeminal
- Glossopharyngeal

Spine

- C-spine WO
- C-spine CCJ
- C-spine WO/W
- C-spine MS WO/W
- T-spine WO
- T-spine Trauma
- T-spine MS WO/W
- T-spine WO/W
- L-spine WO
- L-spine trauma
- L-spine WO/W
- Spine survey

Epic button pending

- Operative planning (brain)
- CSF leak (spine)
- AVM (brain)

Techniques

Table of contents

1.5T vs 3T MRI

3T

- Advantages
  - Higher signal-to-noise ratio (SNR)
    - Better spatial resolution or faster scan times
    - Improved lesion conspicuity (e.g., small MS plaques, hippocampal detail, subtle cortical dysplasia)
    - Better advanced imaging: ASL, DTI, fMRI, spectroscopy, and high-resolution vessel wall imaging
- Disadvantages
  - More susceptible to artifacts:
    - Susceptibility (e.g., near sinuses/skull base)
    - Chemical shift, dielectric shading
  - SAR (Specific Absorption Rate) limits may restrict sequence parameters (esp. in larger patients)
  - CSF flow/pulsation artifacts are more pronounced in spine imaging
  - Implant compatibility more restrictive

1.5T

- Advantages
  - Fewer artifacts in areas prone to susceptibility (e.g., skull base, posterior fossa)
  - Better fat suppression consistency (especially with chemical fat sat)
  - Less SAR concern → greater flexibility in sequence design
  - More implant-compatible
  - Spine imaging generally more robust in challenging regions (e.g., thoracic spine)
- Disadvantages
  - Lower SNR → may need longer scan times
  - Less sensitive for small lesions, especially in brain (e.g., cortical/subcortical MS, early infarcts)
  - Lower resolution for advanced techniques (e.g., DTI tractography, ASL perfusion, MR spectroscopy)

Back to techniques

ASL

- ASL (Arterial Spin Labeling)
  - Non-contrast perfusion technique that uses RF pulses to magnetically label inflowing arterial blood as an endogenous tracer. Images are subtracted from a baseline control (no label) to quantify cerebral blood flow (CBF)
  - Used in stroke, tumor perfusion, and dAVF detection, can show hyperperfusion in AV shunting or hyperemia
  - 3D FSE readout with stack-of-spirals
  - Longer acquisition (4–6 min)

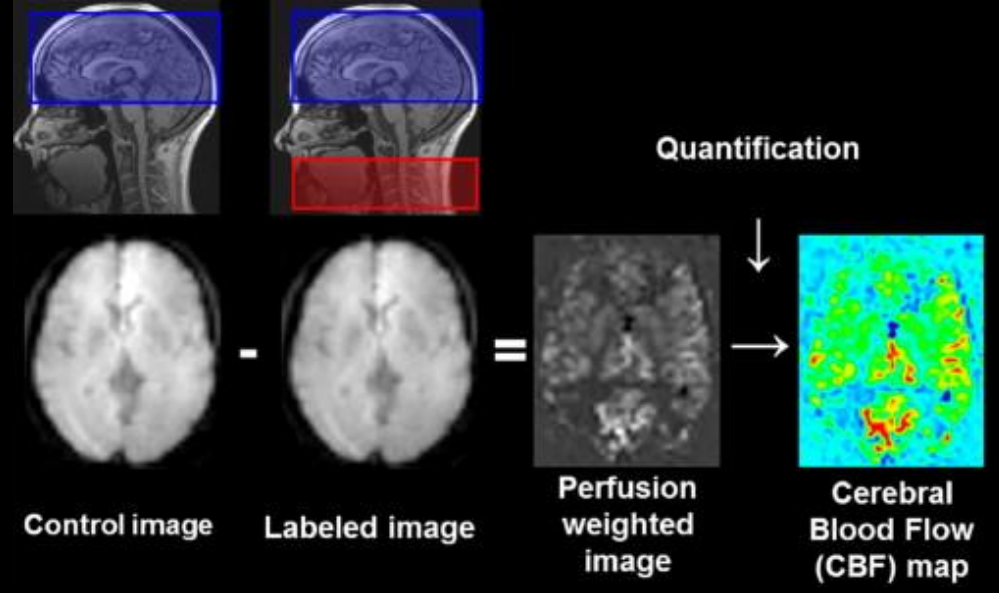

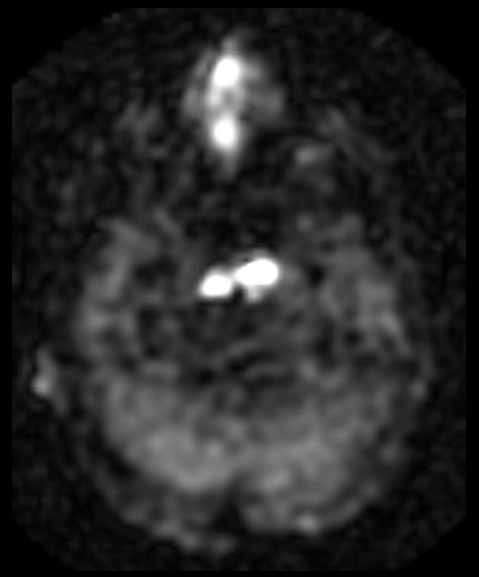

CCF

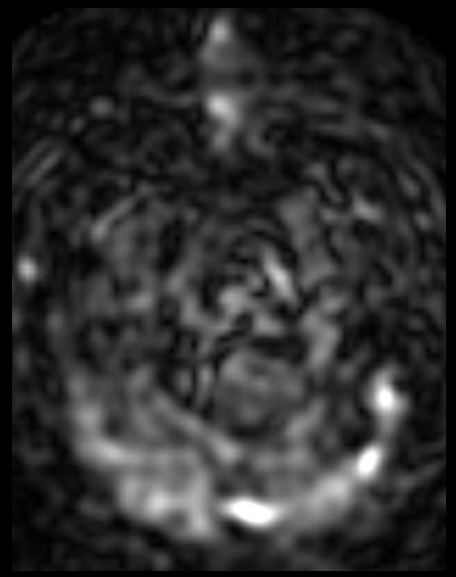

Chronic venous thrombus

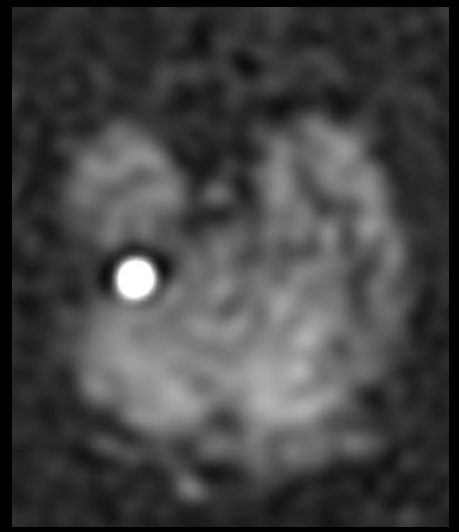

Hemangioblastoma

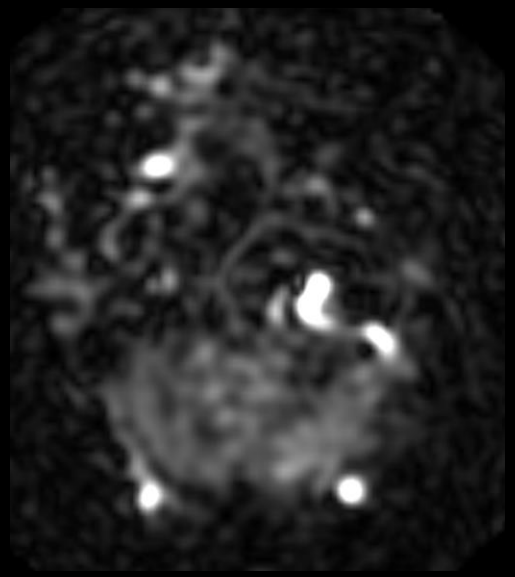

Jugular venous reflux

Back to techniques

Black blood T1 fat-saturated (MRA)

- Dissection protocol (primarily in the neck)
  - Most black blood T1 sequences are **fast spin echo (FSE/TSE)**–based
  - They use **double inversion recovery (DIR)** or **spatial presaturation bands** to suppress blood signal ("black blood")
  - Chemical shift fat saturation with a **frequency-selective saturation pulse** that targets the fat resonance
- Suppressing fat makes it easier to detect:
  - **Intraluminal thrombus**
  - **Intramural hematoma** in vessel walls (which appear T1 hyperintense)
  - **Wall thickening** or enhancement

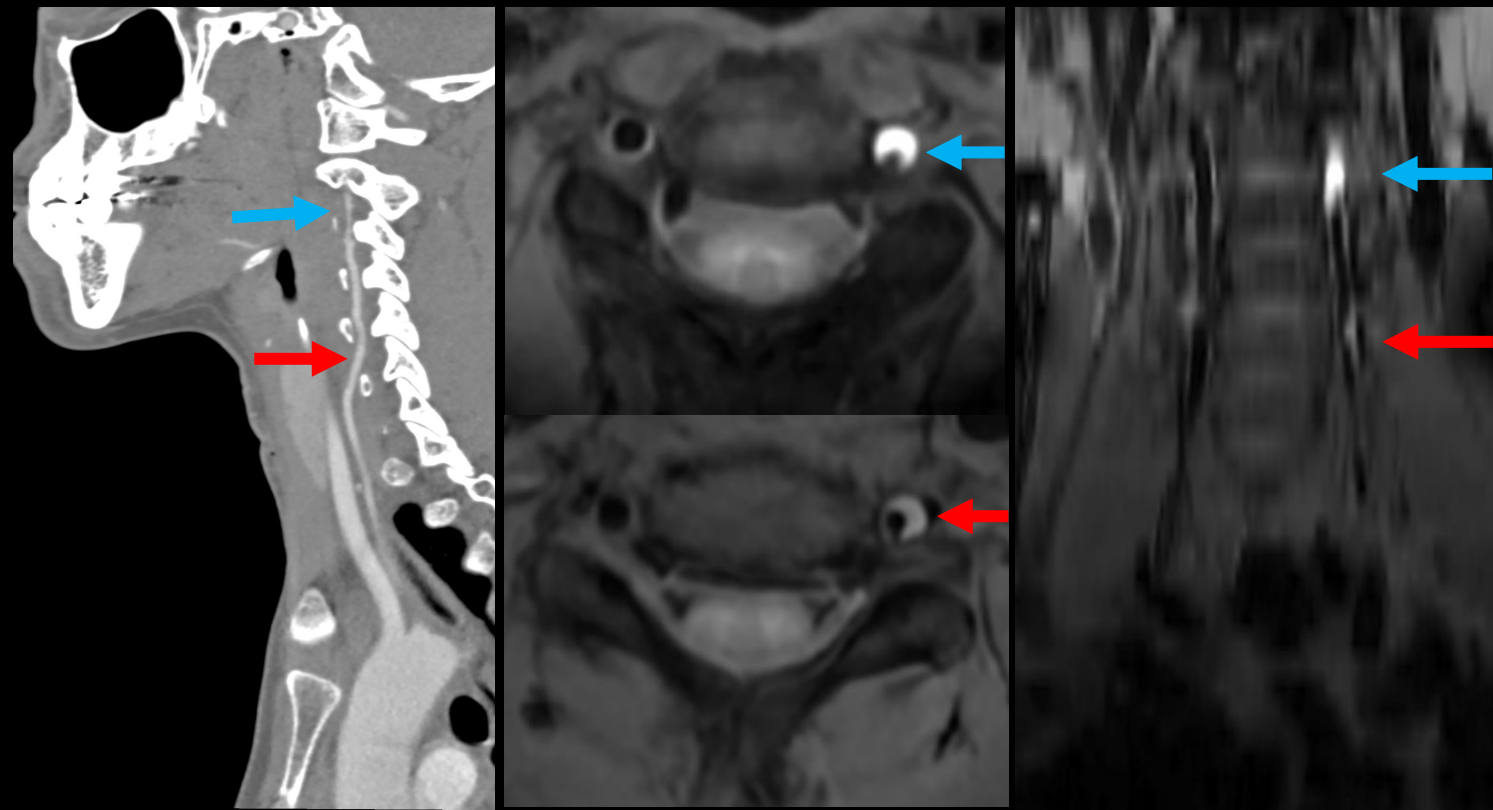

Back to techniques

Brainlab

- Surgical navigation and planning system that integrates with preoperative imaging (MRI, CT) Used to define surgical targets, trajectories, and margins
- Supports intraoperative neuronavigation
- Relies on high-resolution 3D imaging (e.g., post-contrast MP-RAGE, FSPGR, or CUBE) with complete head coverage including the nose for registration
- Often used in brain tumor resections, epilepsy surgery, and functional neurosurgery
- Some institutions use StealthStation (Medtronic) as an alternative system

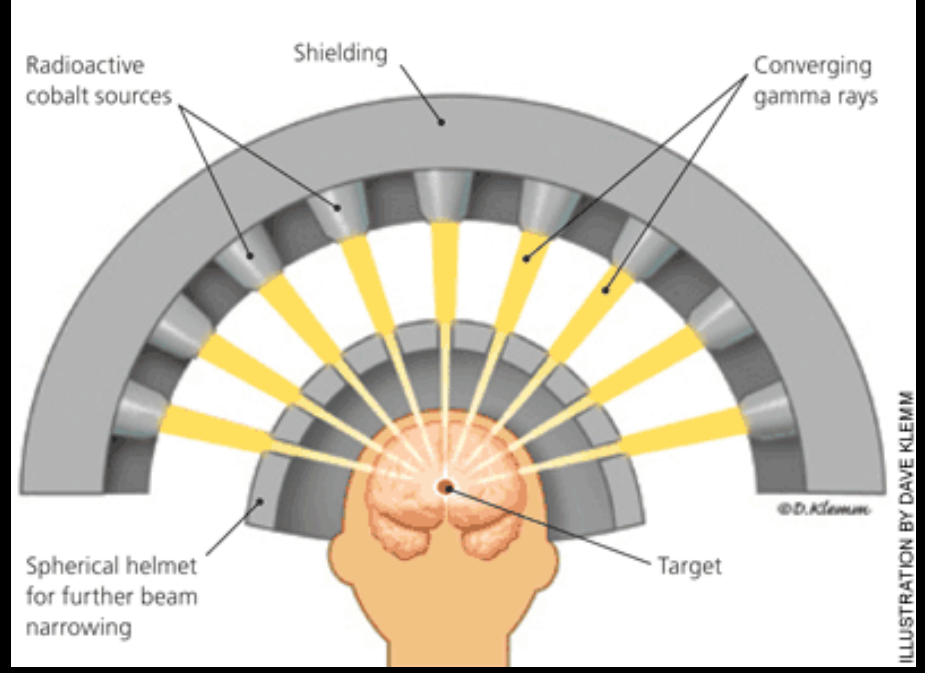

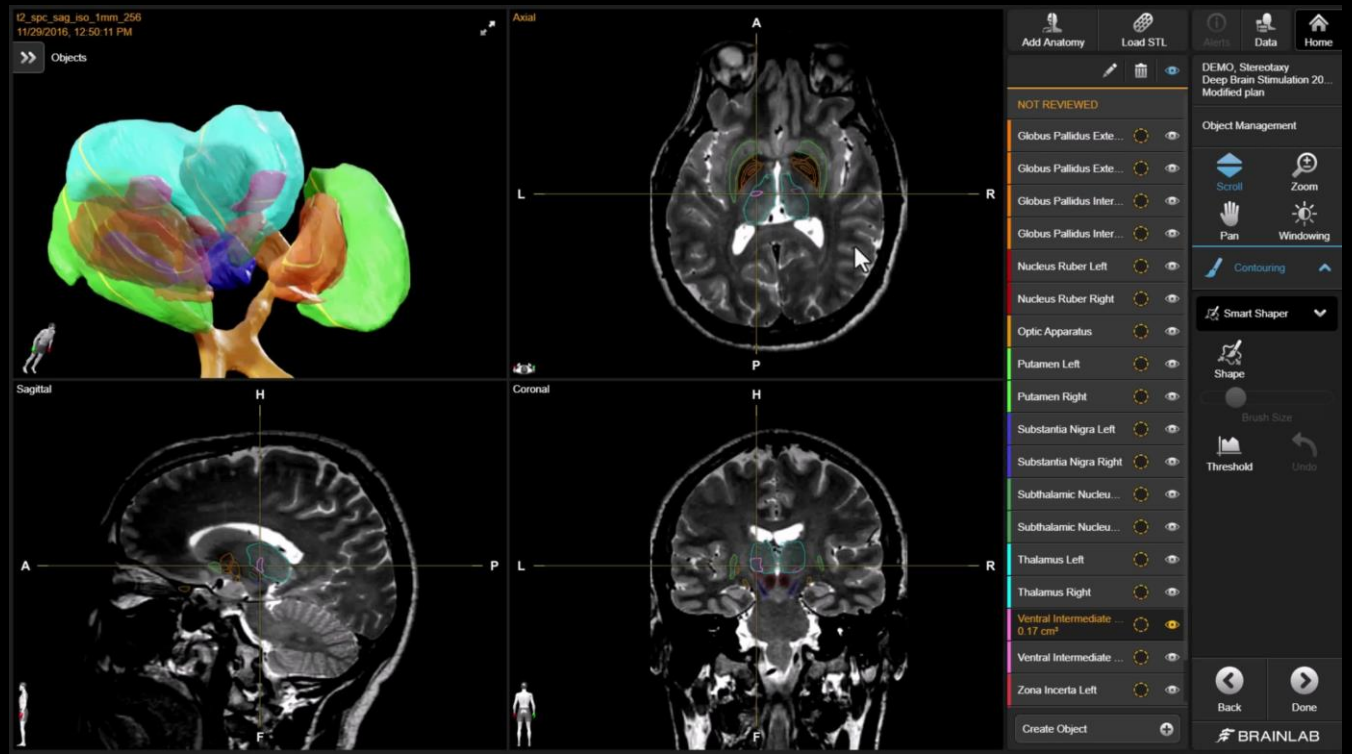

[Back to techniques]

Chemical Shift Fat Suppression

- Uses a short radiofrequency pulse tuned to the Larmor frequency of fat protons resulting in selective excitation followed by gradient spoiling, leaving only water protons to contribute to signal when the main excitation pulse is delivered shortly thereafter
- Inhomogenous fat suppression further from isocenter and around sources of susceptibility
- Compared to STIR, chemical shift fat suppression has higher SNR and is faster

Back to techniques

CUBE (GE) or SPACE (Siemens)

- 3D volumetric TSE high spatial resolution and sub-millimeter isotropic voxels
- Contrast mechanisms differ from 2D TSE due to variable flip angle refocusing pulses, phase-encoding strategy
- Can be T1-, T2-, or FLAIR-weighted
- Can be combined with fat suppression, post-contrast
- SPACE: Sampling Perfection with Application-optimized Contrasts using different flip angle Evolutions

- Advantages
  - High spatial resolution (small structures like cranial nerves)
  - Operative planning
  - Enables high-quality multiplanar reformats
- Disadvantages
  - Lower SNR compared with 2D T2 TSE
  - Higher scan time compared to 2D sequences
  - Longer acquisition time (prone to motion artifact, can be accelerated with parallel imaging techniques
  - CSF pulsation artifact

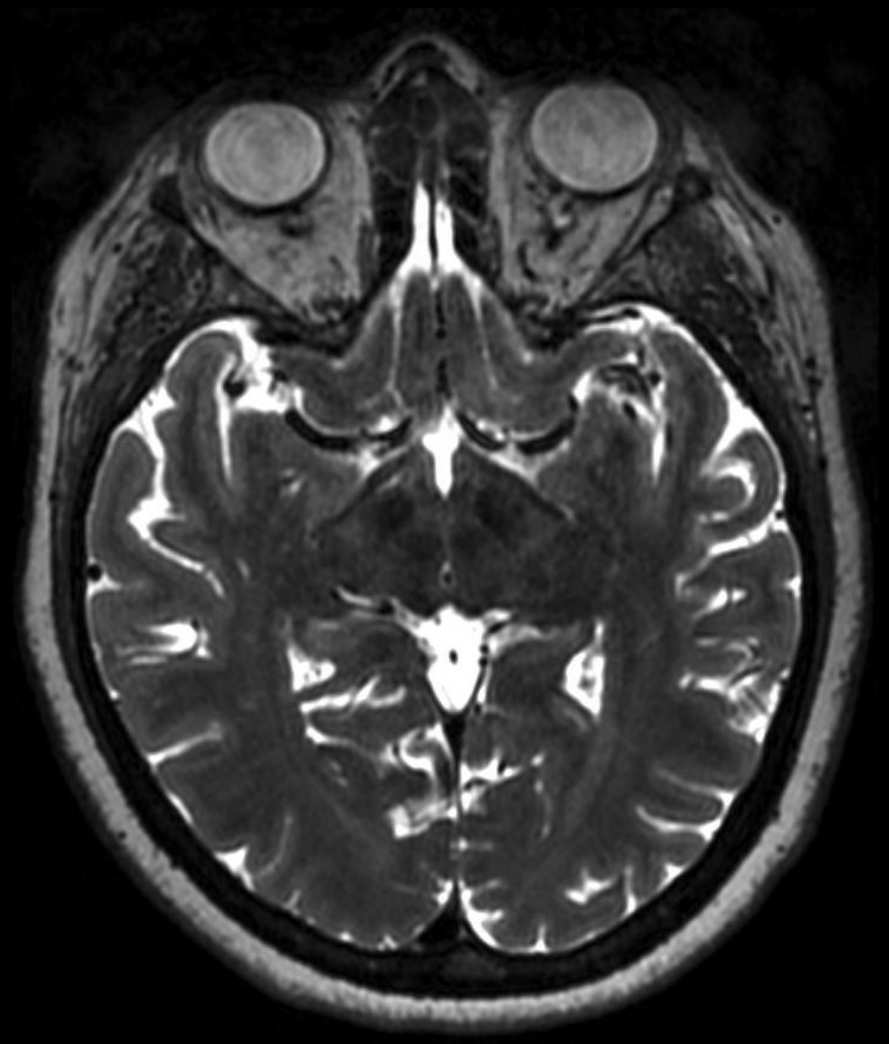

Whole brain 3D T2 CUBE

Back to techniques

FIESTA

- Contrast is T2/T1-ratio–weighted, **not pure T2**
- Slightly higher spatial resolution
- More CSF pulsation artifact
- Faster acquisition

T2 CUBE

- Contrast is true T2 weighted
- Better T2 weighting and tissue contrast
- Less CSF pulsation artifact
- Slower acquisition

FIESTA

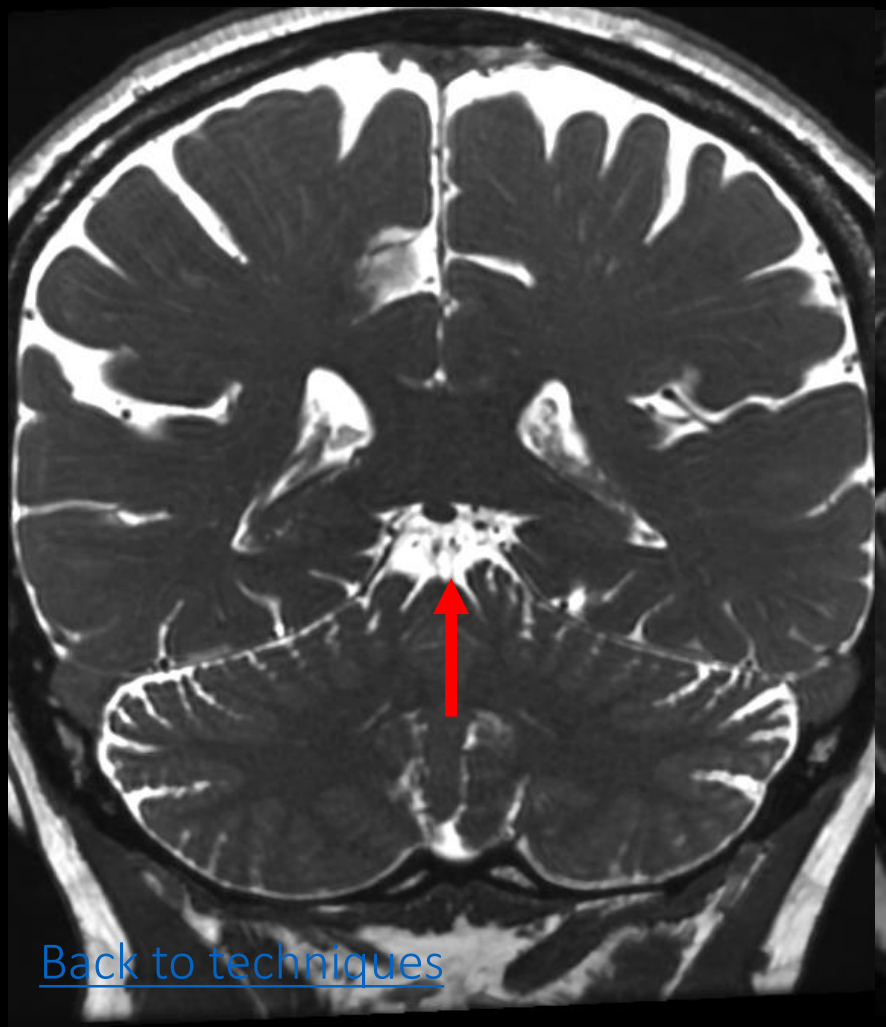

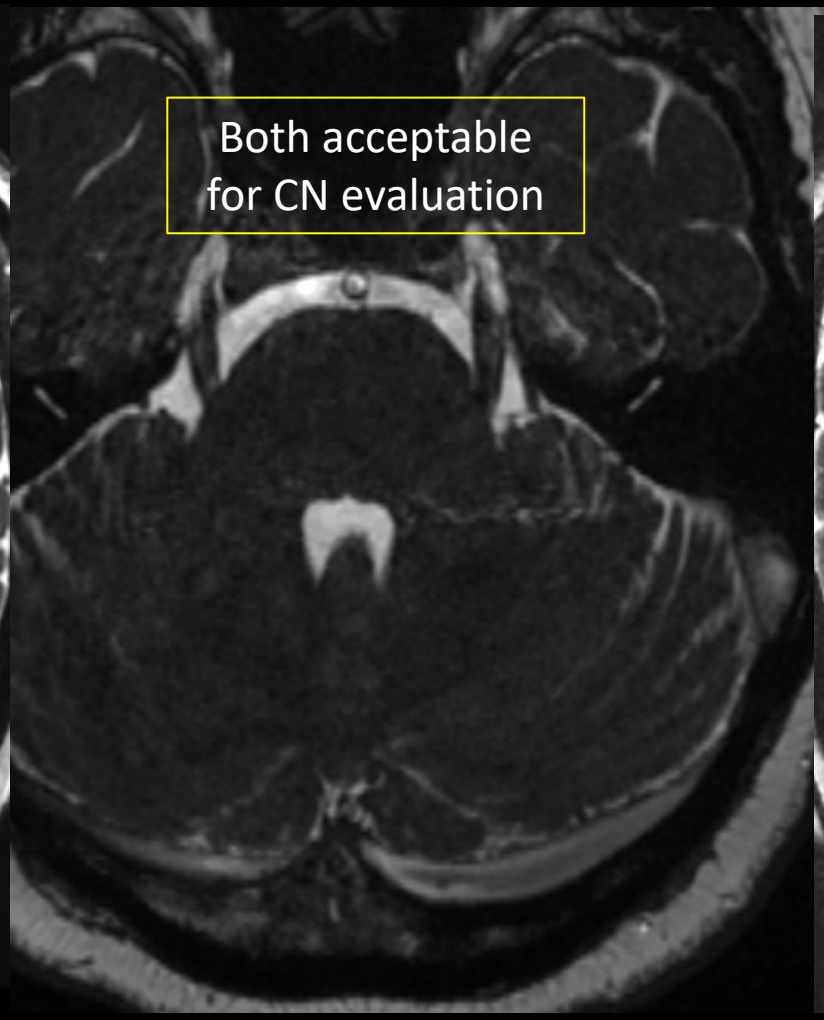

T2 CUBE

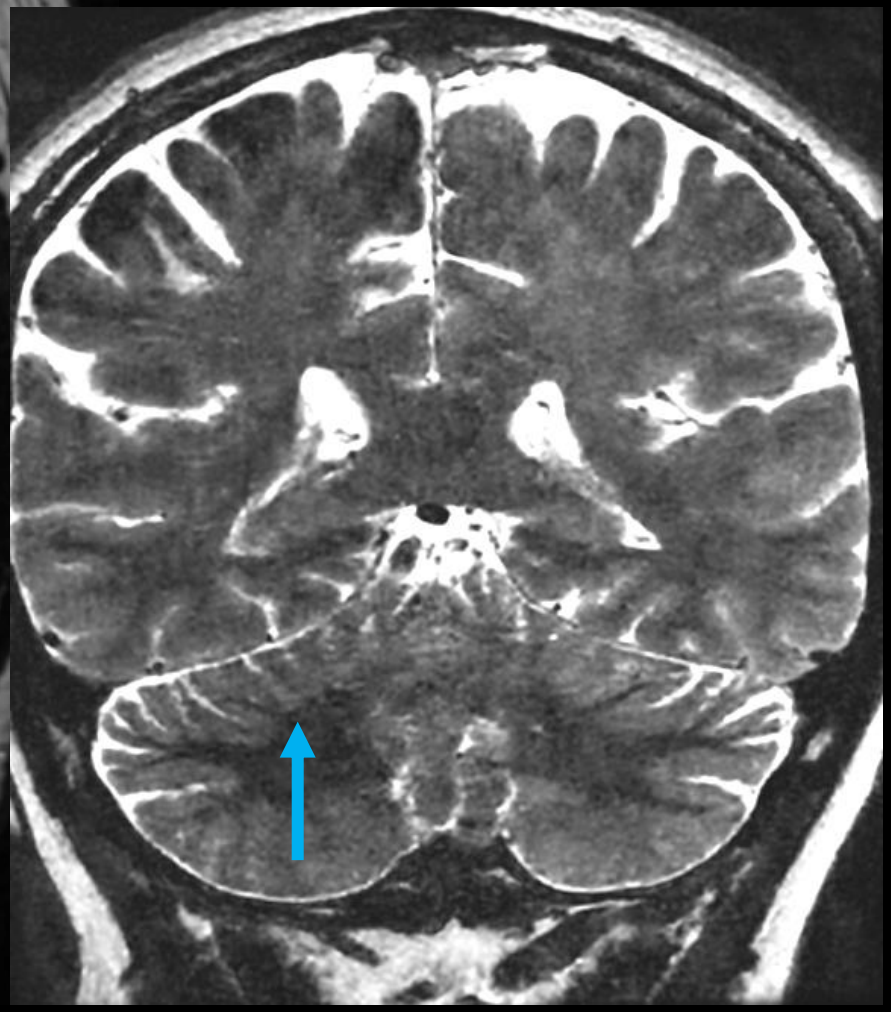

Back to techniques

DSC

- Dynamic susceptibility contrast
  - A dynamic T2*-weighted imaging technique used to assess cerebral perfusion
    - A single bolus of gadolinium contrast is rapidly injected (4–5 mL/sec)
    - As the bolus passes through the cerebral vasculature, a T2*-weighted echo planar imaging (EPI) sequence (usually every 1–2 seconds) captures the signal drop caused by susceptibility effects of gadolinium as it passes through the brain's capillary network
    - Generates quantitative perfusion maps including CBF (cerebral blood flow), CBV (cerebral blood volume), and MTT (mean transit time)
    - Requires arterial input function (AIF) selection and post-processing for map generation
  - Commonly used in stroke, tumor, and vascular imaging to evaluate perfusion deficits or hypervascularity
  - Sensitive to susceptibility artifacts (given gradient echo EPI readout)

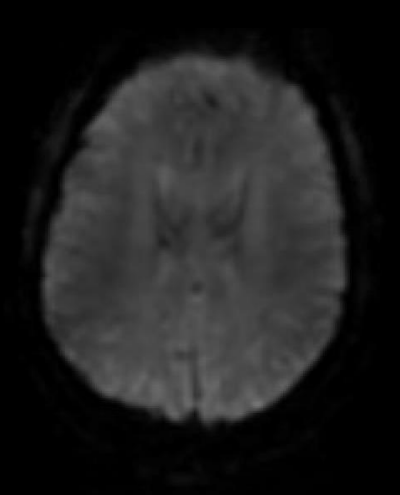

Perfusion (source)

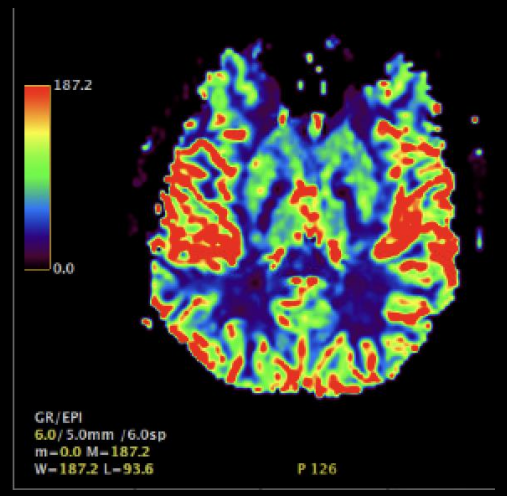

rCBV

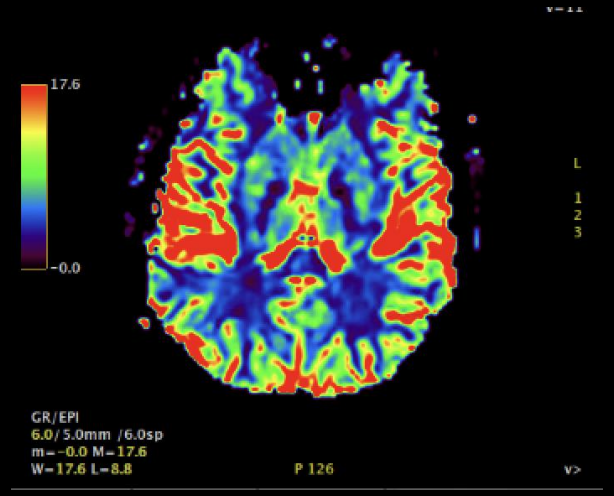

rCBF

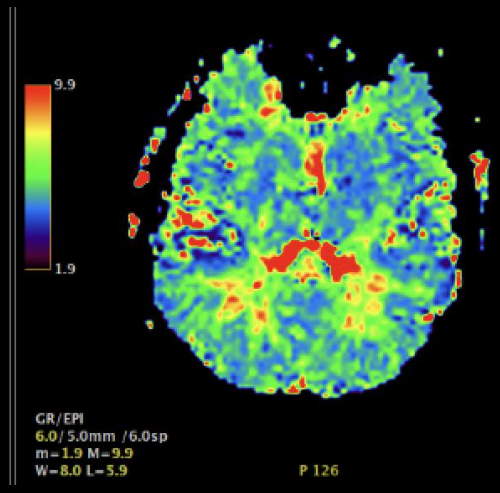

MTT

Back to techniques

DWI (Diffusion-Weighted Imaging)

- Measures the random (Brownian) motion of water molecules in 3 orthogonal dimensions
- Primarily used in stroke imaging, tumor characterization, and infection
- Single-shot spin-echo echo-planar imaging (EPI) technique
  - Spin-echo core provides diffusion contrast
  - EPI readout is gradient-echo–based, giving inherent T2* susceptibility sensitivity (can detect hemorrhage)
  - Acquires all k-space lines from one RF excitation per slice (single TR) → very fast
  - Two sets of images from the same acquisition, differing in diffusion-gradient strength (b-value):
    - Higher b values represent greater diffusion weighting relative to T2 weighting
    - Degree of diffusion weighting is determined by the amplitude and duration of applied diffusion gradients

- b0
  - Diffusion gradients off
  - Essentially a T2-weighted image. Useful to troubleshoot when other sequences are motion-degraded or not acquired (e.g., missing SWI)
- b1000 (AKA "trace," labeled “DWI” in PACS)
  - Same acquisition with strong diffusion gradients applied
- ADC (apparent diffusion coefficient)
  - Calculated, not separately acquired; a quantitative measure of diffusion (removes T2 shine-through)
- eADC (exponential ADC)
  - Further derived from ADC; qualitative, retains DWI-like appearance (restriction stays bright)

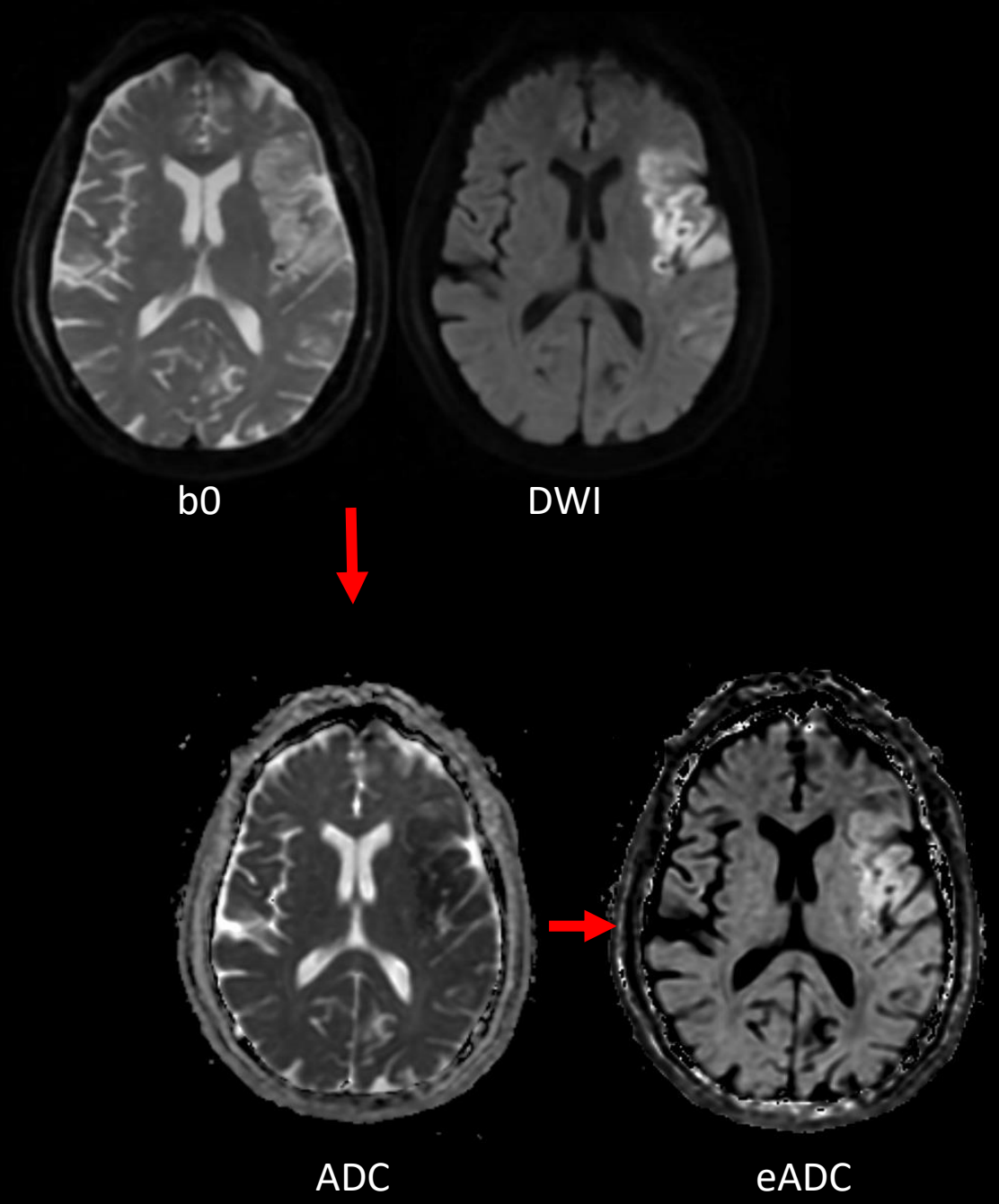

Back to techniques

DWI (Diffusion-Weighted Imaging)

- Pros
  - Extremely fast (single-shot) → motion-robust, seconds per acquisition
  - Most sensitive sequence for acute infarct — positive within minutes
  - Aids tumor grading, abscess vs necrotic tumor, cholesteatoma, epidermoid
  - b0 doubles as a T2*-sensitive backup to screen for blood products
- Limitations
  - Low spatial resolution and inherent image blur
  - Poor soft-tissue anatomic detail vs conventional sequences
  - Geometric distortion from the EPI readout
  - Sensitive to susceptibility (air–bone interfaces, metal, hemorrhage)

- Pitfalls
  - T2 shine-through
    - Hyperintensity on DWI can represent true diffusion restriction, intrinsic T2-hyperintensity also contributes to DWI signal intensity (T2 shine-through) and should not be confused for diffusion restriction
    - True diffusion restriction will exhibit DWI hyperintensity and corresponding ADC hypointensity -always confirm with low ADC
  - T2 blackout
    - Very low T2 signal can mask true restriction on b1000
  - Skull base / posterior fossa dropout and distortion near air (temporal bone, sinuses)
  - ADC is quantitative but absolute values vary with b-value and vendor/technique

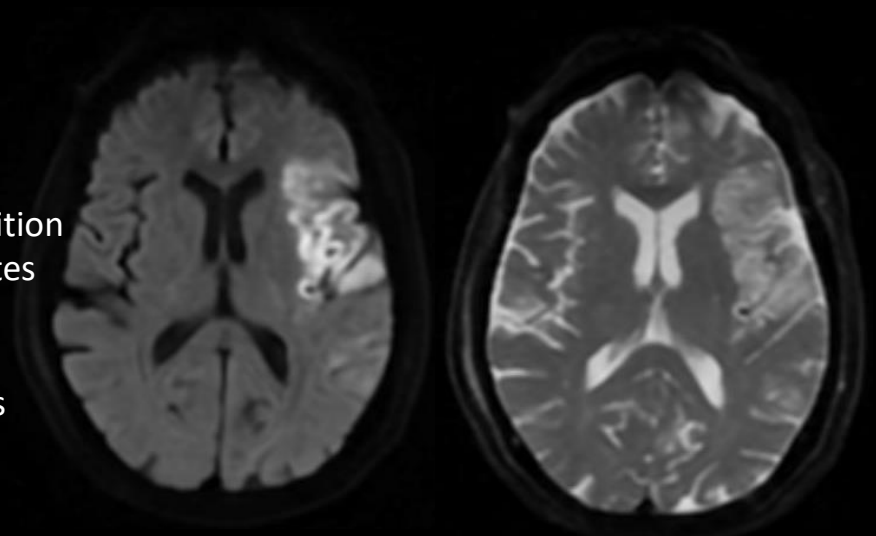

DWI B0

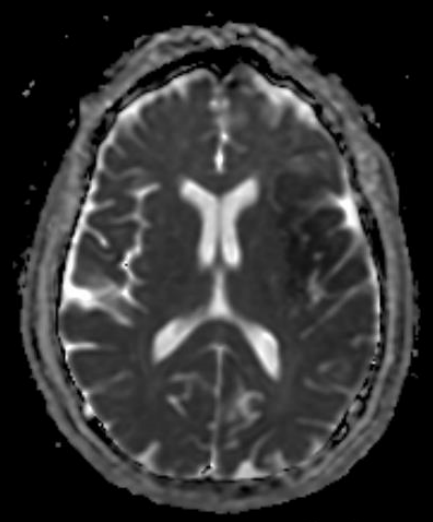

ADC

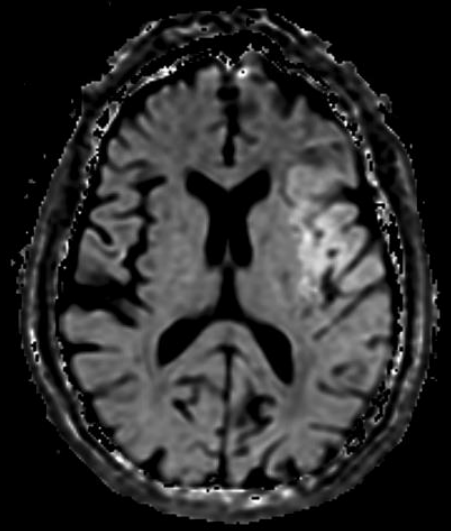

eADC

Back to techniques

DWI - Variants

- **PROPELLER**
  - Non-EPI readout (fast-spin echo), acquires multiple overlapping radial "blades" in k-space and averages them for artifact reduction.
  - Results in both higher resolution and significantly reduced motion artifacts
  - Decreased FOV offsets the increase in acquisition time
  - Lower susceptibility artifacts than ss-EPI (less distortion in air-bone interfaces like the skull base)
  - Higher SNR than standard DWI due to multiple overlapping k-space acquisitions.
  - Longer scan times than MUSE

- **MUSE (Multiplexed Sensitivity-Encoding)**
  - Multi-shot EPI sequence designed to improve resolution and reduce distortion compared to standard single-shot EP
  - Acquires data over multiple shots rather than a single shot
  - Higher resolution
  - Reduced geometric distortion (better for regions affected by susceptibility artifacts, such as the skull base and orbits)
  - Longer scan times than standard, more motion artifact

DWI MUSE

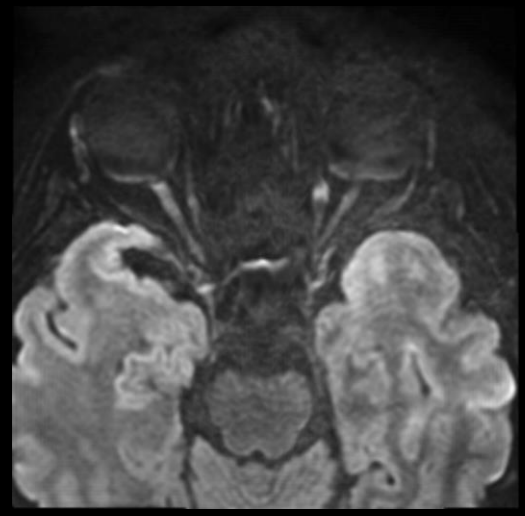

DWI PROP

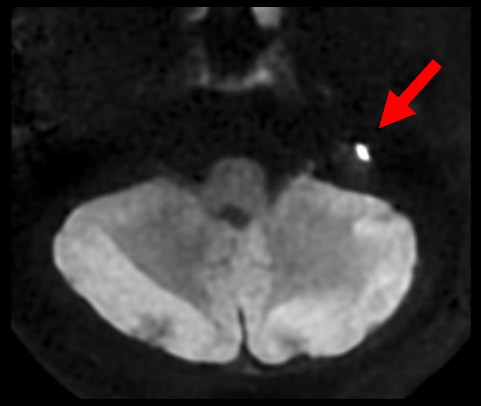

DWI (standard SS -EPI)

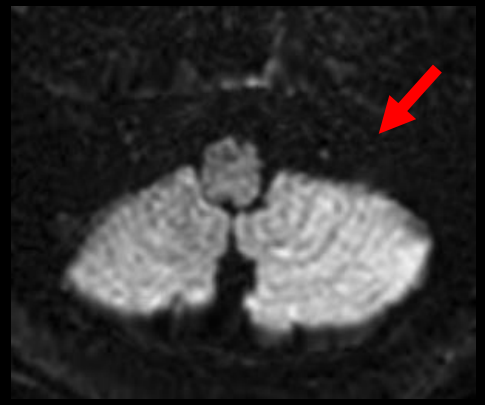

Recurrent cholesteatoma only visible on PROP



Back to techniques

FIESTA (GE) or CISS (Siemens)

- FIESTA: Fast Imaging Employing Steady-State Acquisition
- CISS (Constructive Interference in Steady State)

- Balanced Steady-state free precession (SSFP) sequence
  - Runs at very short TR/TE with a steady-state maintained by repeated RF pulses.
  - Contrast is T2/T1-ratio weighted, not true T2 — fluid and fat are bright because of their high T2/T1 ratio

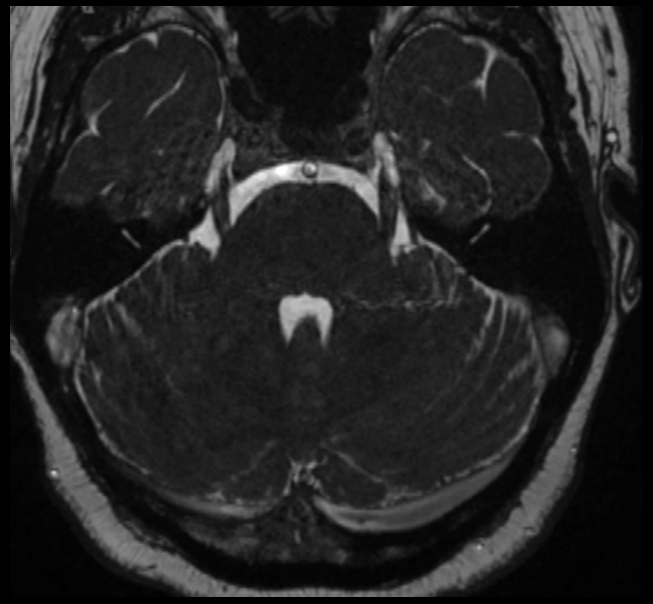

- Advantages
  - Highest SNR efficiency of any sequence (SNR per √time), signal recycled every TR
  - Very fast, motion-robust
  - Crisp delineation of small structures bathed in CSF
  - 3D isotropic

- Disadvantages
  - Banding artifacts — dark off-resonance bands, worsening at high field and with imperfect shim.
  - Susceptibility-sensitive at air–tissue interfaces (skull base, sinuses).
  - Not true T2 — poor soft-tissue-to-soft-tissue contrast, weak for solid lesion characterization.
  - Fat is bright which can obscure pathology without fat suppression

Back to techniques

FIESTA

- Contrast is T2/T1-ratio–weighted, **not pure T2**
- Slightly higher spatial resolution
- More CSF pulsation artifact
- Faster acquisition

T2 CUBE

- Contrast is true T2 weighted
- Better T2 weighting and tissue contrast
- Less CSF pulsation artifact
- Slower acquisition

FIESTA

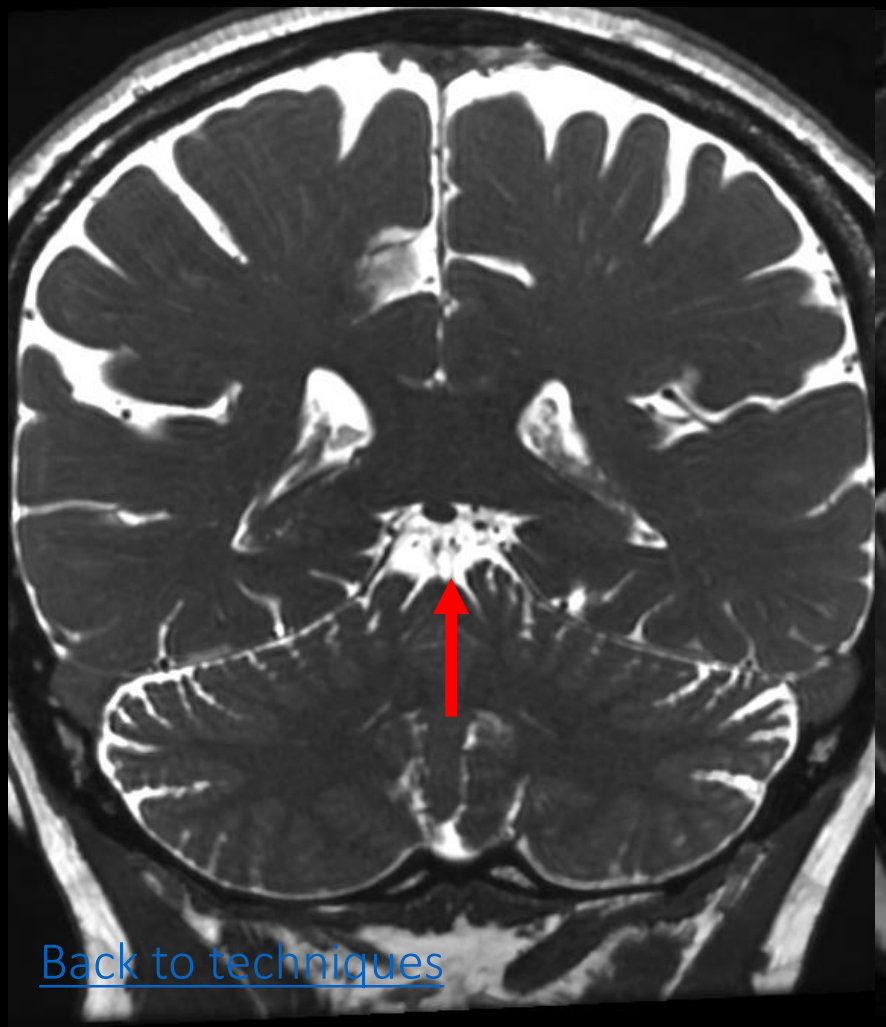

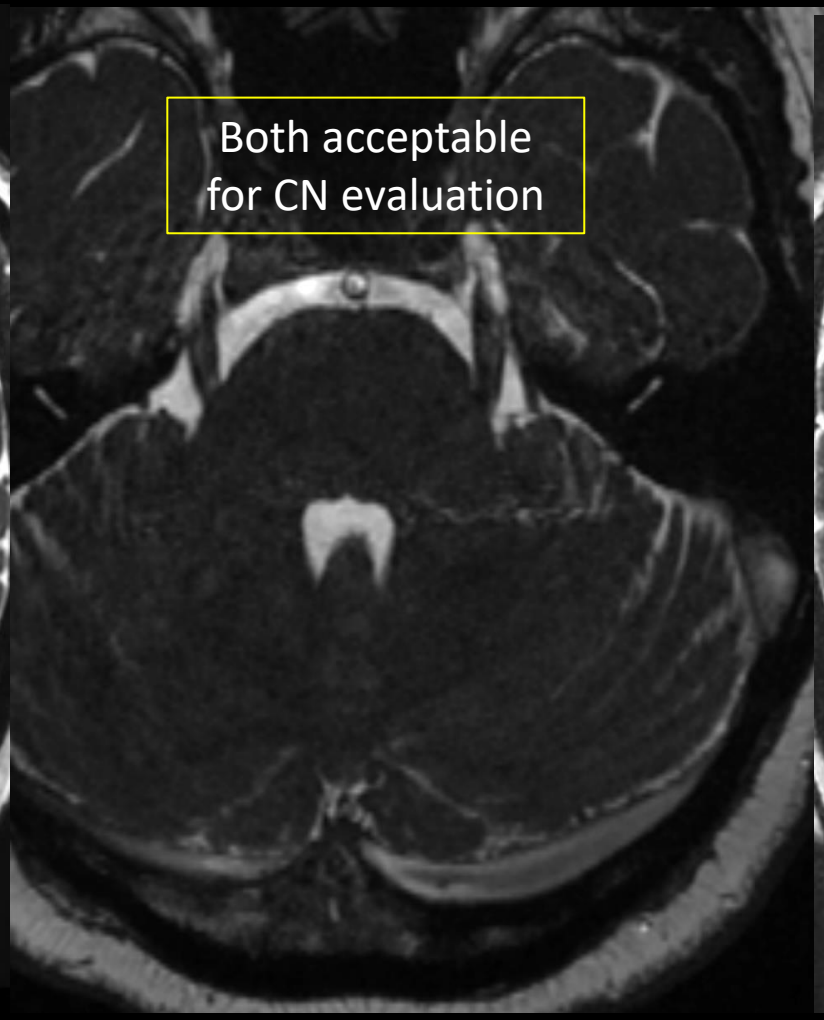

T2 CUBE

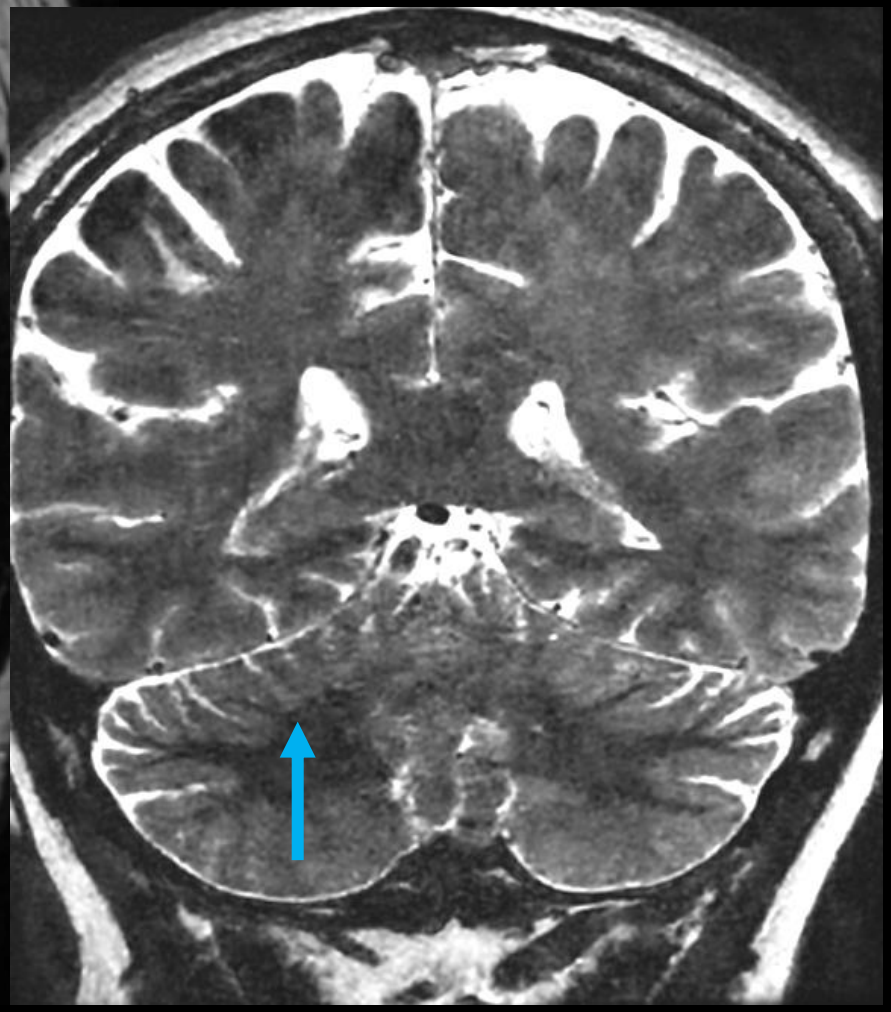

Back to techniques

FLAIR

- FLAIR (Fluid Attenuated Inversion Recovery)
  - 180 RF pulse suppresses free fluid signal (eg, CSF) at time TI (inversion time)
  - Enhances visualization of pathology like white matter lesions
  - T1 FLAIR sequences used at most 3T scanners, some sequences on 1.5 T (e.g., on 1.5T, axial T1 incorporates FLAIR, but not sagittal)

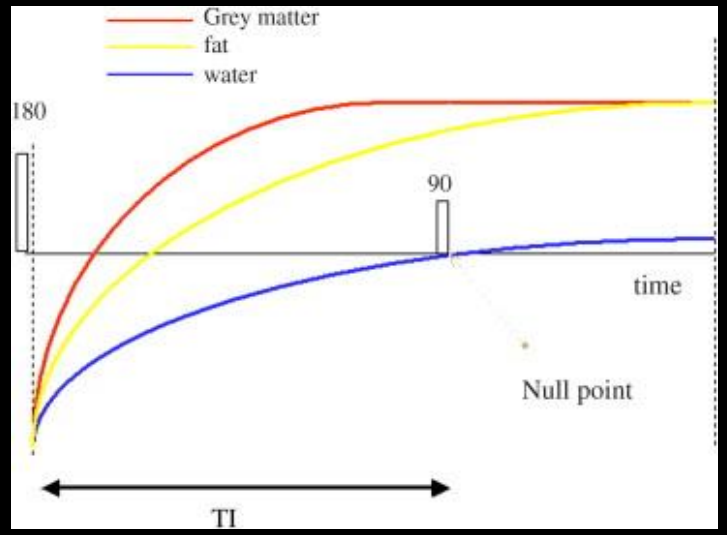

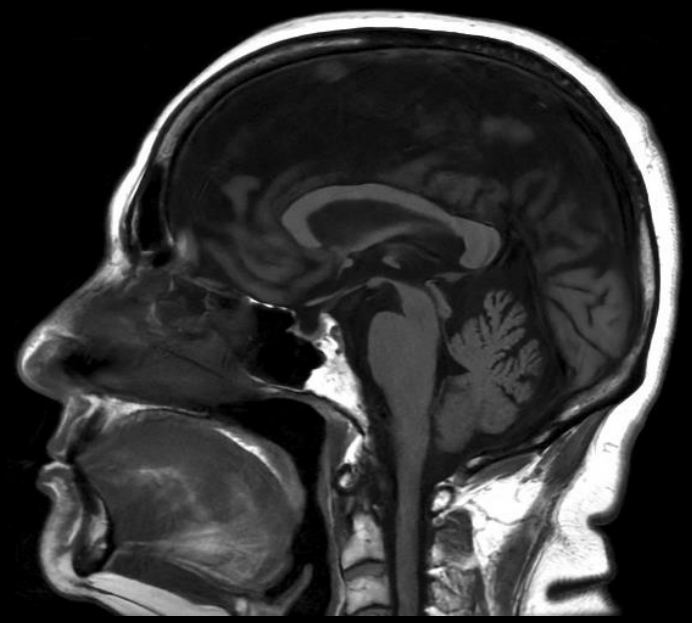

Sag T1 FLAIR

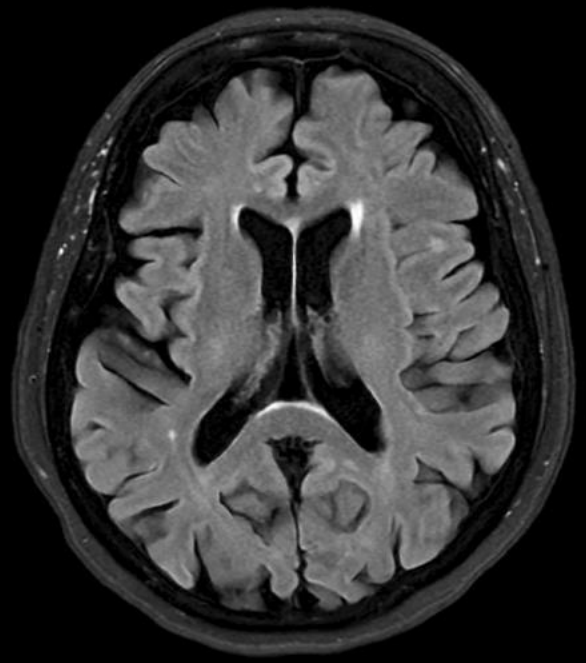

Ax T2 FS FLAIR

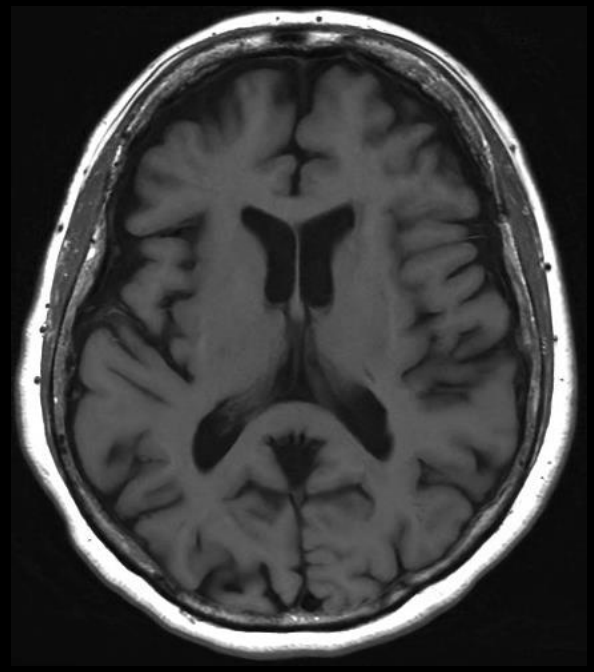

Ax T1 FLAIR

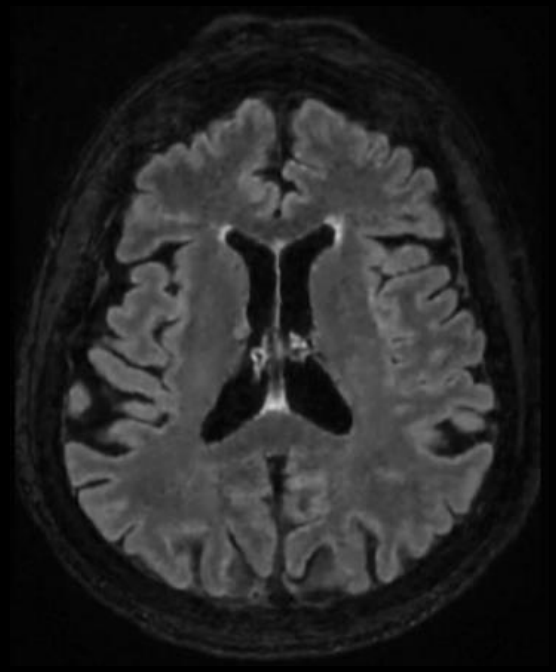

3D T2 FS FLAIR C+

Back to techniques

FLEX

- FLEX (Fast Leveraged EXcitation)
  - GE's implementation of the Dixon two-point dual-echo Dixon-based fat-water separation, producing in-phase, out-of-phase, water-only, and fat-only images
  - Can be added to various sequences
    - T1 or T2 FSE
    - GRE sequences (LAVA, TRICKS)
  - Usually replaces STIR, post-contrast T1 sequences
  - Sequence nomenclature in PACS
    - InPhase = Standard T1 or T2 weighting
    - Water only image (fat suppressed, similar to STIR)
    - Fat only image (water suppressed, can be used for trouble-shooting)

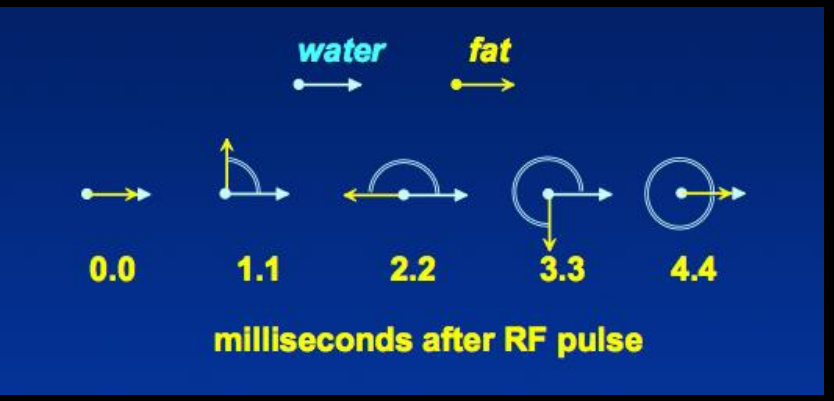

Sag T2 FLEX (Water)

Sag T2 FLEX (InPhase)

Back to techniques

FLEX

- While FLEX (Dixon-based fat-water separation) is excellent for fat suppression, it can occasionally cause **misregistration**, **fat-water swapping**, or **inhomogeneous suppression** in complex anatomy or with motion.
- The Fat-only sequences (fat is hyperintense) are often automatically sent to PACS for trouble-shooting purposes in case this occurs

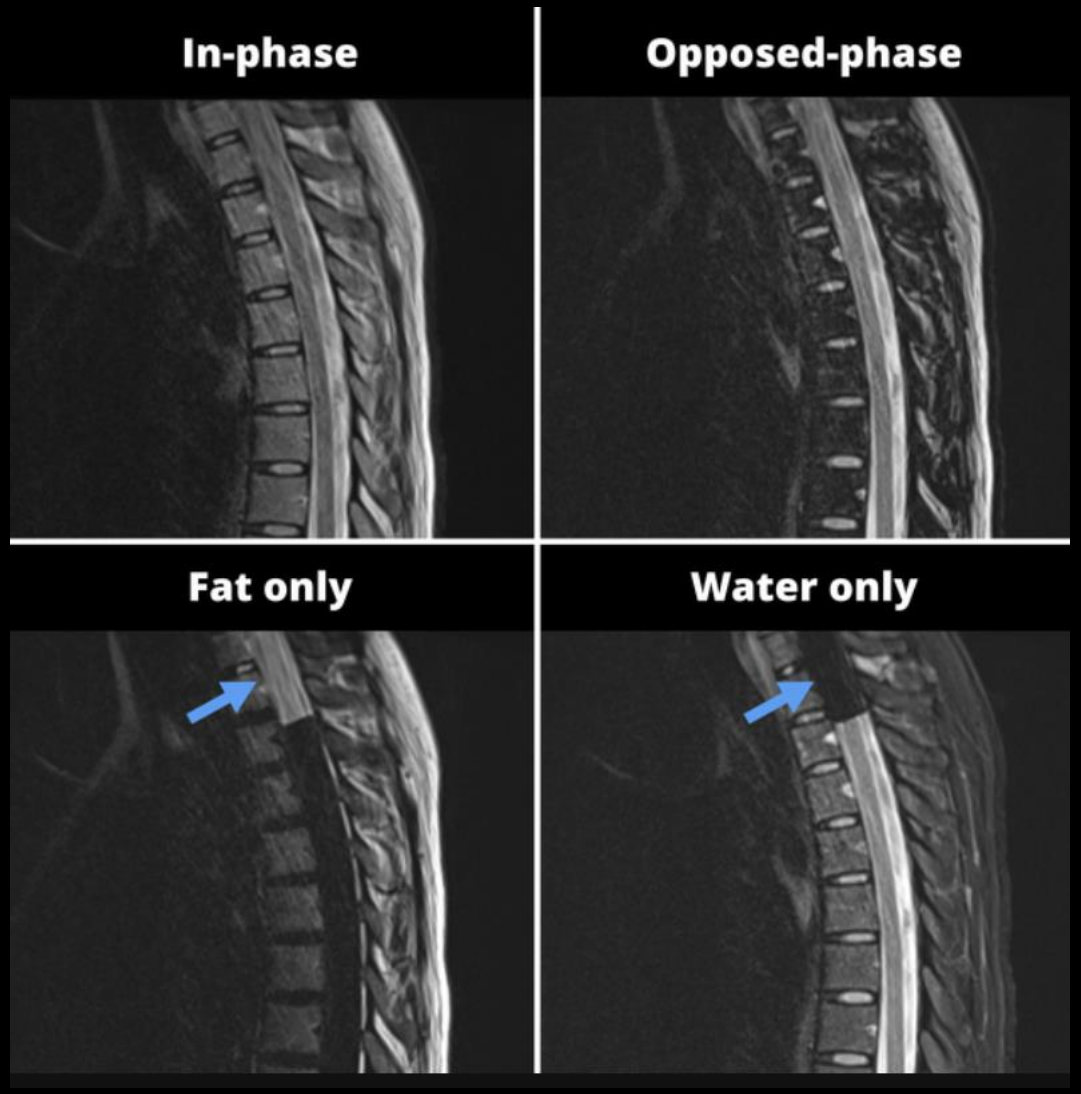

Back to techniques

FSE/TSE vs FrFSE/RST

- Fast Spin Echo (GE) or Turbo Spin Echo (Siemens)
  - ”Default” for 2D T1 and T2 spin echo sequence, simply labeled as “Ax T1” or ”Cor T2” (most 3T scanners)
  - Spin-echo sequence that acquires multiple echoes per TR, reducing scan time. After the last echo in the echo train, the spins must naturally recover back to equilibrium before the next TR. This leads to some signal loss between TRs, reducing overall image contrast for long-T2 tissues like CSF, edema, or joint fluid

- Fast Recovery Fast Spin Echo (GE) or Restore (Siemens)
  - FSE sequence with reduced signal loss due to improved recovery of longitudinal magnetization
  - A 90° fast recovery pulse is applied immediately after the last echo, forcing the remaining transverse magnetization back into the longitudinal direction. This shortens the T1 recovery time and allows the tissue to reach full magnetization faster before the next TR. As a result, fluid retains more signal and may appear brighter than in standard FSE.
  - Used in 2D T2 spin-echo sequences at 1.5T scanners

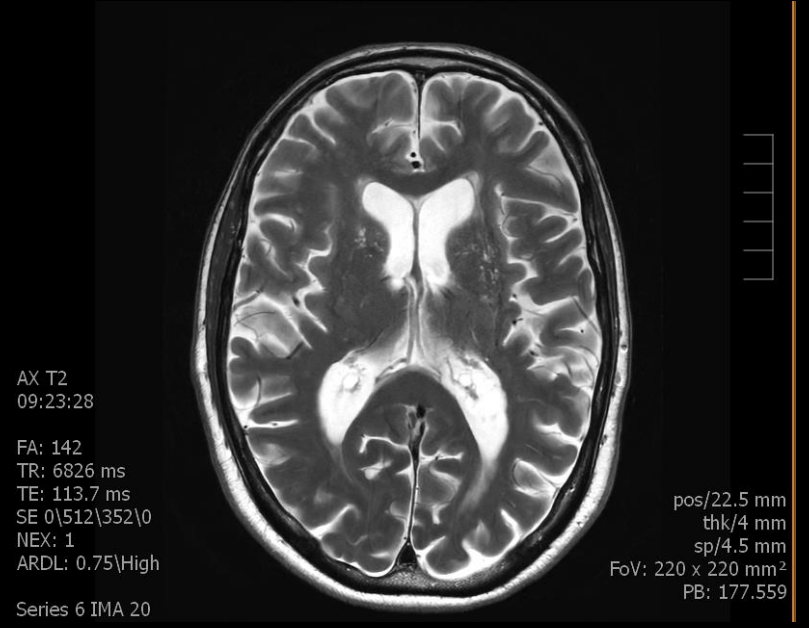

FSE

FrFSE

Back to techniques

InHance 3D Velocity

- InHance 3D Velocity
  - A non-contrast, flow-sensitive MRA technique
  - Volumetric 3D phase contrast acquisition using velocity-encoding gradients to measure flowing blood
  - Generates magnitude and phase images
  - Can be reformatted into MRA or MRV projections
  - Best for: slower flowing structures, can evaluate venous structures on MRA

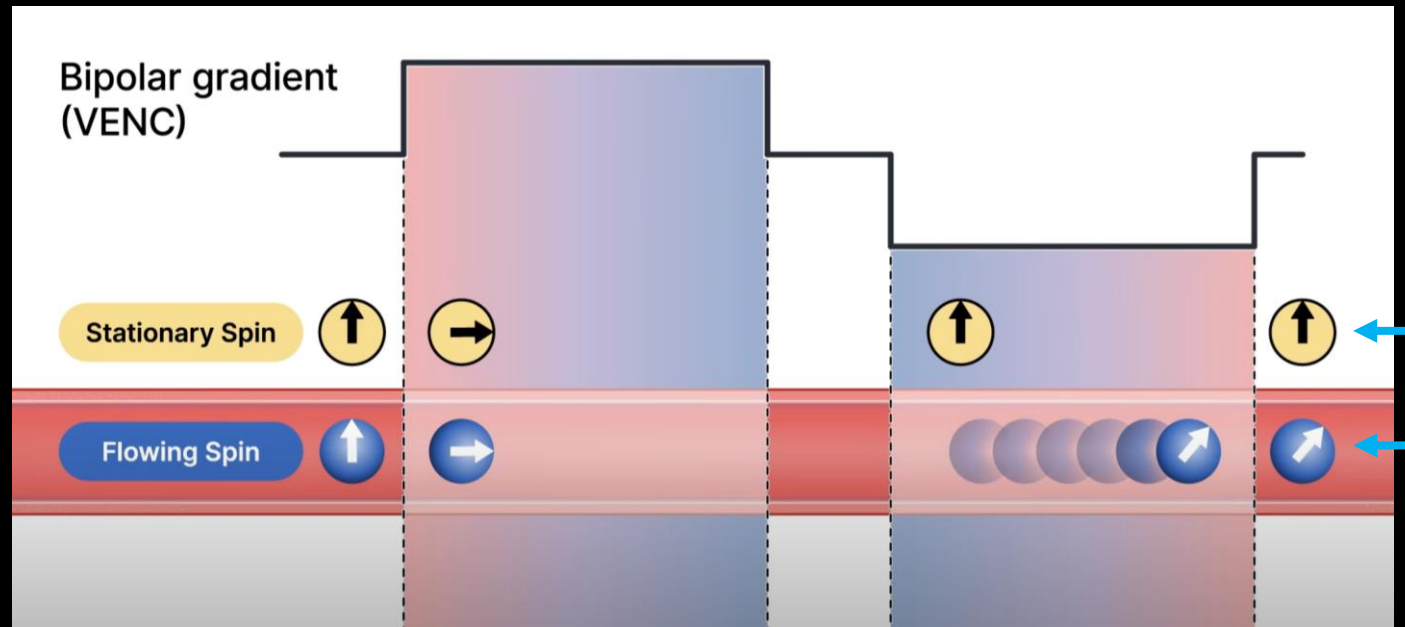

Degree of phase shift after gradient application indicates velocity

Back to techniques

MARS (Metal artifact Reduction Sequences)

- Susceptibility mismatch between metal and tissue distorts B0 → signal voids, bright "pile-up," geometric distortion (in-plane and through-plane), and failed fat suppression
- Basic strategies
  - Prefer 1.5T over 3T — artifact scales with field strength
  - Use TSE/FSE, avoid GRE —180° refocusing pulses recover susceptibility dephasing
  - Prefer STIR over chemical-shift fat-sat (fails in the inhomogeneous field near metal; STIR's inversion recovery is field-robust)
  - Swap phase/frequency direction to reposition artifact away from the cord/region of interest
  - ↑ Receiver bandwidth
  - ↓ TE, ↑ echo train length, smaller voxels/thinner slices — reduces dephasing and through-plane blur
- Dedicated MAR sequences VAT (view-angle tilting)
  - Corrects in-plane distortion
- Tradeoffs / pitfalls
  - MAR sequences cost scan time, SNR, and/or spatial resolution
  - Over-correction can blur anatomy; residual distortion still possible with large hardware

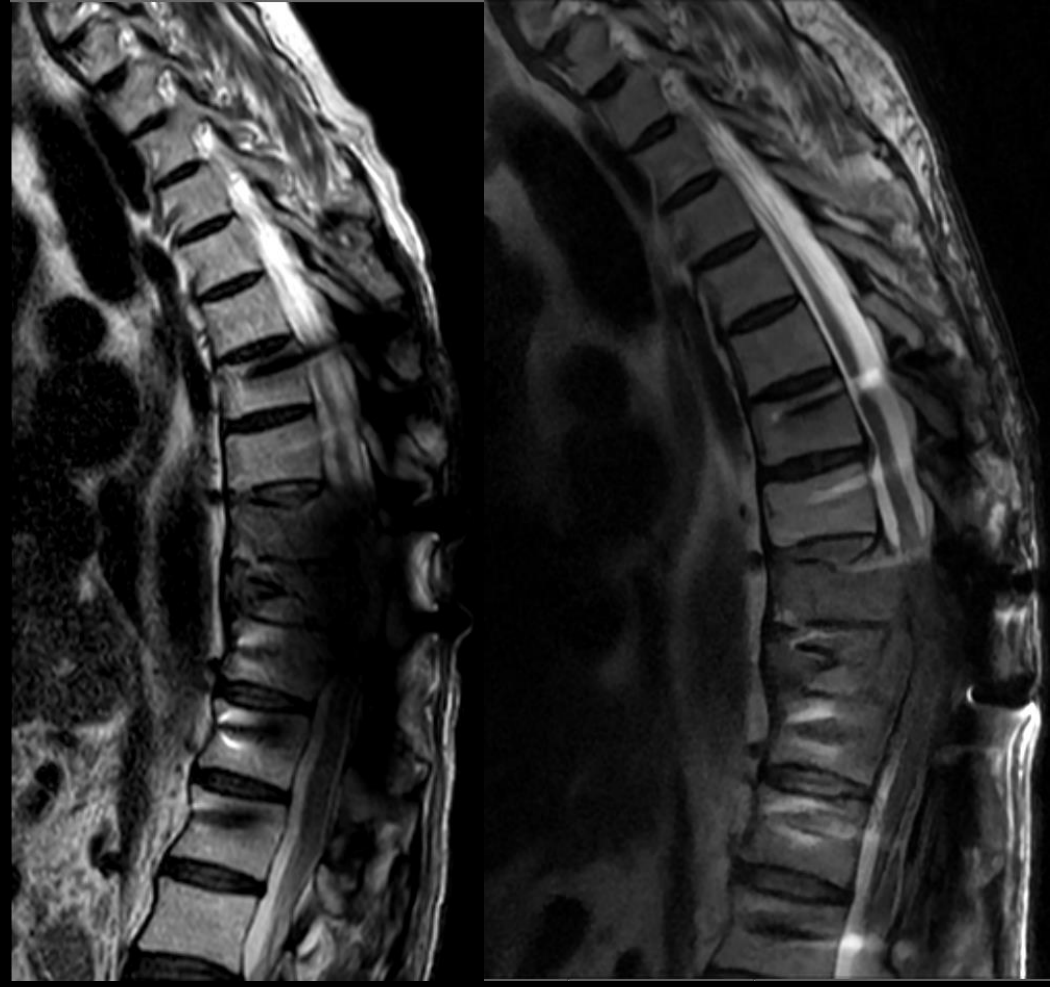

T2 T2 MARS

Back to techniques

MDSE Motion-Sensitized Driven Equilibrium

- Blood-suppression ("black-blood") nulls luminal blood so arterial wall can be assed for atherosclerotic plaque, vasculitis, dissection, and aneurysms
- Mechanism
  - A preparatory module consisting of a 90° tip-down pulse → diffusion/motion-sensitizing gradients → 180° refocusing pulse → gradients → 90° tip-up pulse
  - Flowing blood accumulates phase dispersion from the motion-sensitizing gradients and is driven to zero signal (black blood), while stationary tissue (vessel wall) is unaffected and retains signal
- Pros
  - Blood suppression is independent of flow velocity/direction — works for slow, recirculating, or in-plane flow
  - Uniform suppression over large 3D volumes
- Limitations
  - SNR penalty — preparation module introduces T2 decay during the MSDE interval, reducing overall vessel wall SNR
  - Eddy currents from the motion-sensitizing gradients → incomplete restoration, artifacts
  - Longer scan time from the added prep
  - Over-strong gradients suppress the wall itself, not just blood
  - Incomplete CSF suppression can mimic or obscure outer-wall enhancement
  - Residual slow-flow signal can mimic wall thickening or plaque

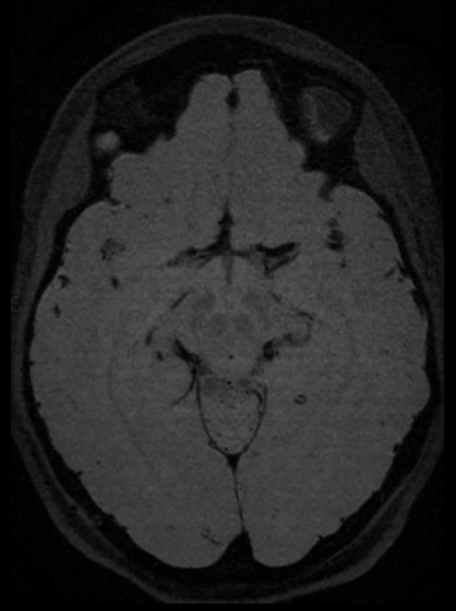

3D MSDE

3D MSDE C+

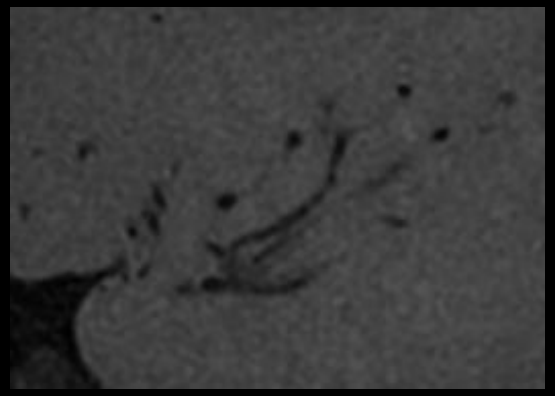

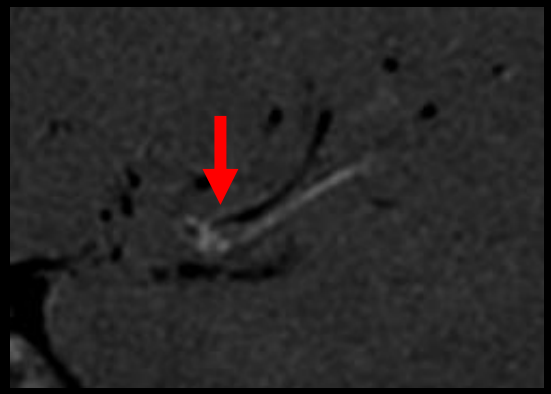

3D MSDE C+

Back to techniques

MERGE

- Multi-Echo Recombined Gradient Echo
  - A multi-echo GRE sequence
  - Combines echoes to improve SNR and contrast for evaluating vertebral endplates, disc margins, and subtle marrow pathology
  - T2* weighting enhances susceptibility effects makes it useful for detecting hemorrhage (will appear hypointense)

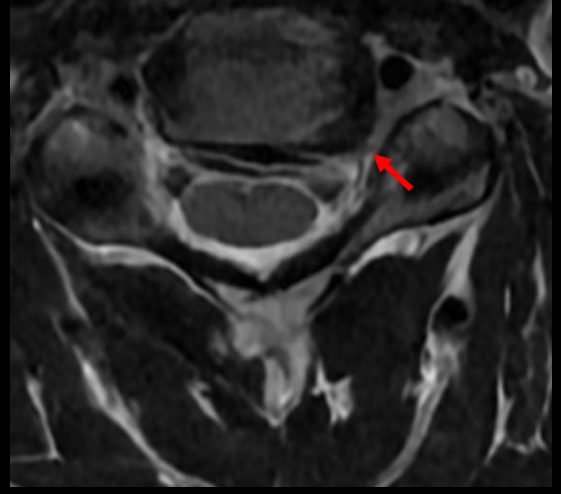

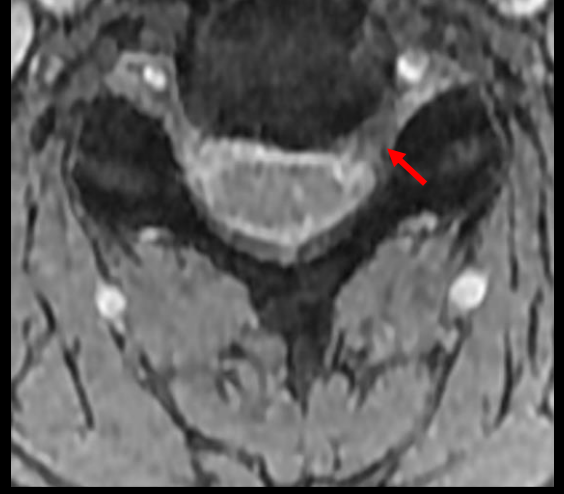

T2 hypointense structure (osteophyte vs disc) narrows neuroforamina or spinal canal, which is hyperintense on MERGE, confirming disc (not osteophyte)

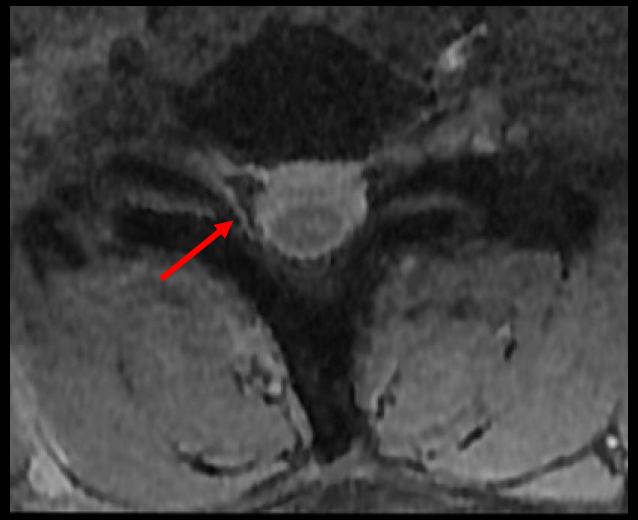

Hypointense epidural hematoma

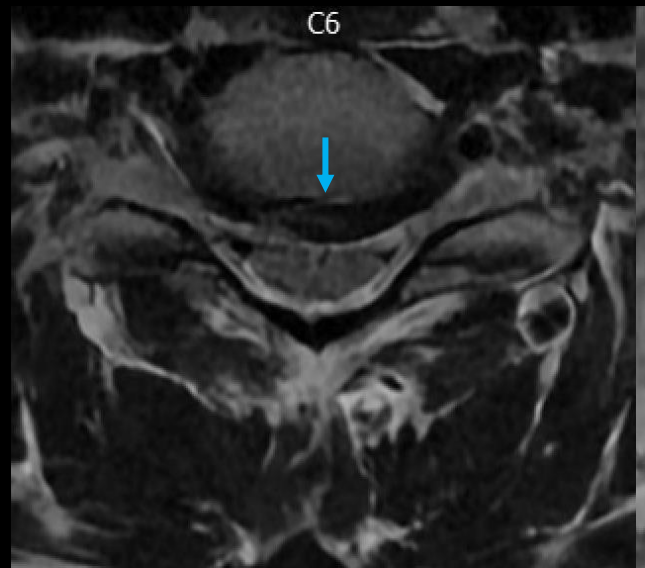

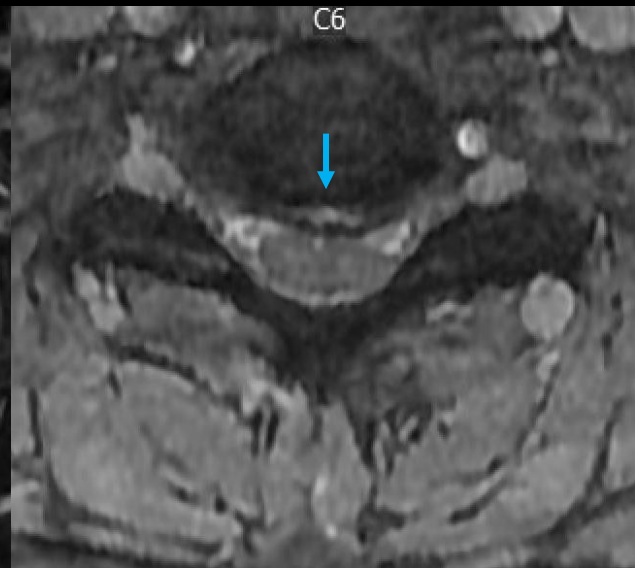

Back to techniques

T1 post-contrast: spin echo (2D) versus MP-RAGE (3D)

Spin echo (2D)

Strengths
- High contras to noise (CNR)
- Fast

Weaknesses
- Thick slices with gaps
- Pulsation artifact

MP-RAGE (3D)

Strengths
- High signal to noise (SNR)
- High spatial resolution
- Surgical navigation
- Tiny lesions

Weaknesses
- Lower contrast per voxel
- More sensitive to motion
- Slow



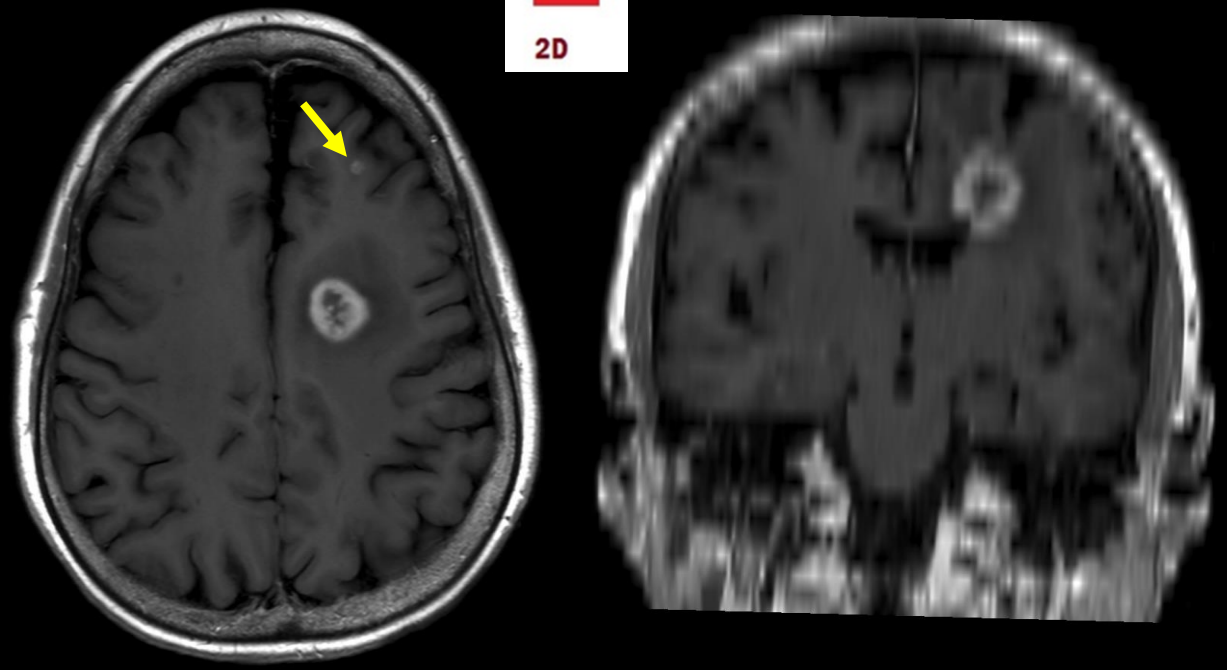

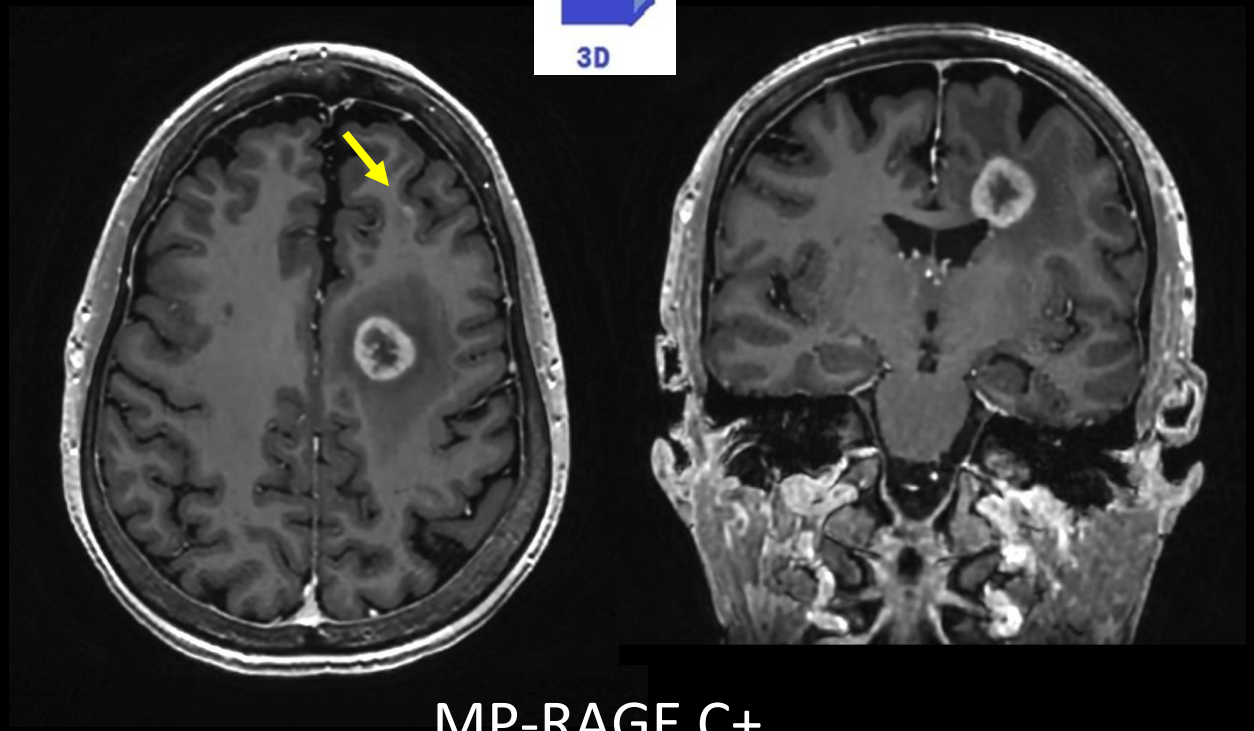

Back to techniques

T1 FSE C+

MP-RAGE C+

MP-RAGE/BRAVO

- Magnetization-Prepared Rapid Acquisition Gradient Echo (MP-RAGE, Siemens) /Brain Volume Imaging (BRAVO, GE)
  - 3D T1-weighted GRE sequence with an 180° inversion-recovery prep pulse before the GRE readout train (increasing stronger longitudinal T1 contrast)
  - Gray-white matter differentiation superior to standard T1 FSE enhance gray-white matter contrast
  - Used in structural brain imaging and pre/post-contrast studies.
  - Better contrast resolution than FSPGR/BRAVO
  - IR prep can partially suppress T1 enhancement (correlate with FSE)

FSPGR/FLASH

Fast Spoiled Gradient Echo (FSPGR, GE) / Fast Low Angle Shot (FLASH, Siemens)

- Similar to MP-RAGE, but no inversion pulse
- T1 contrast comes from short TR + low flip angle alone
- No IR results in decreased tissue contrast, but enhancement isn't suppressed

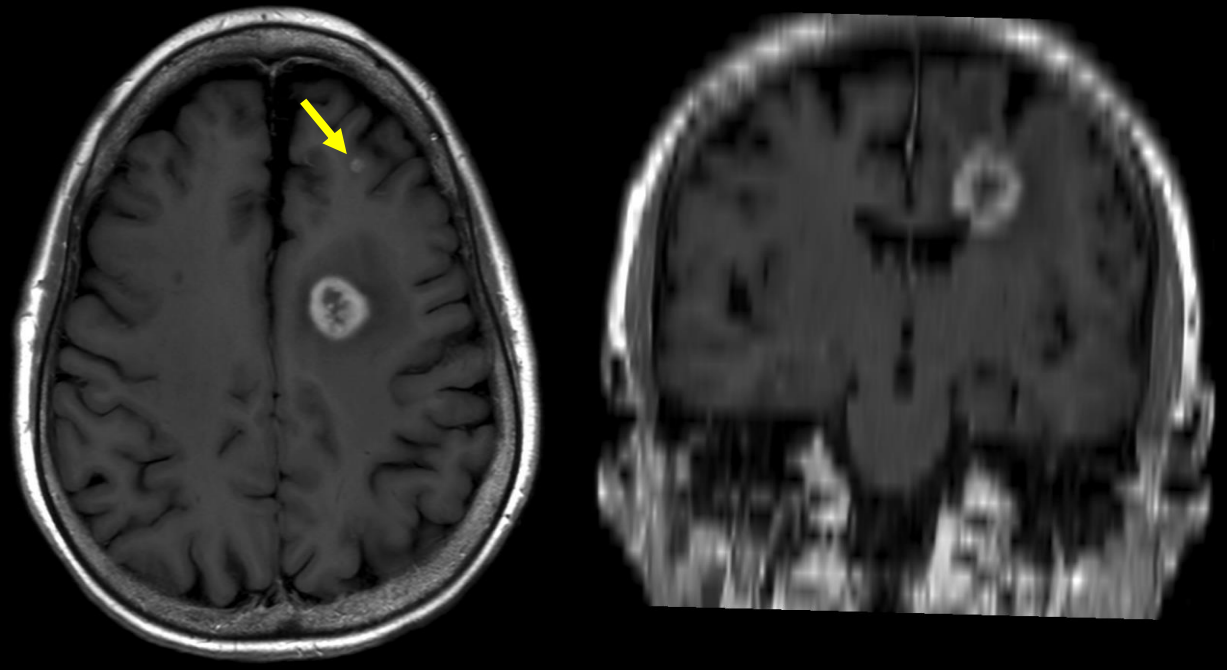

2D T1 FSE C+

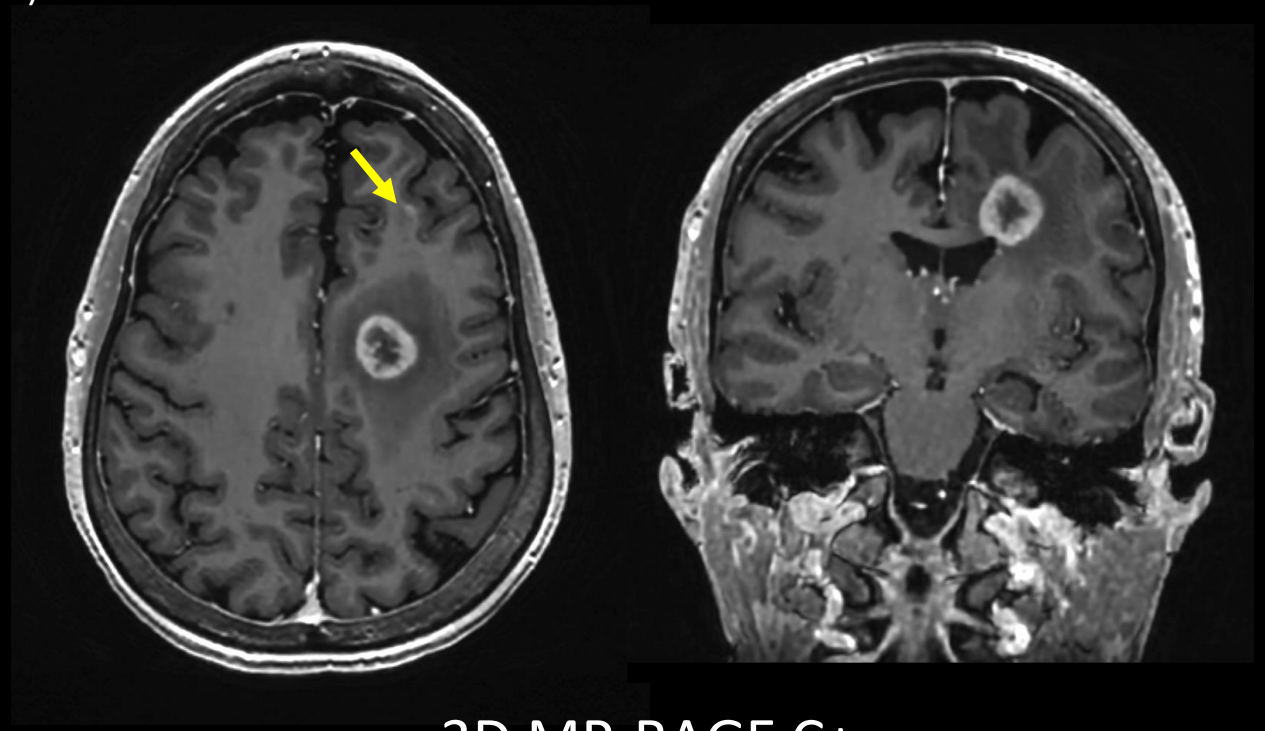

3D MP-RAGE C+

Back to techniques

Some lesions are only seen on 2D T1 spin echo

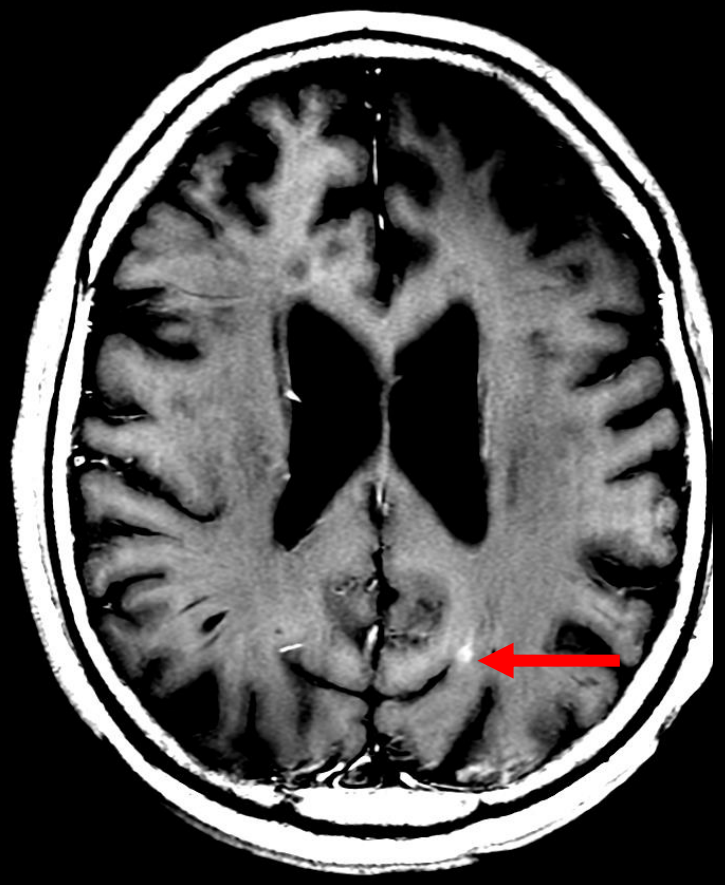

2D T1 C+

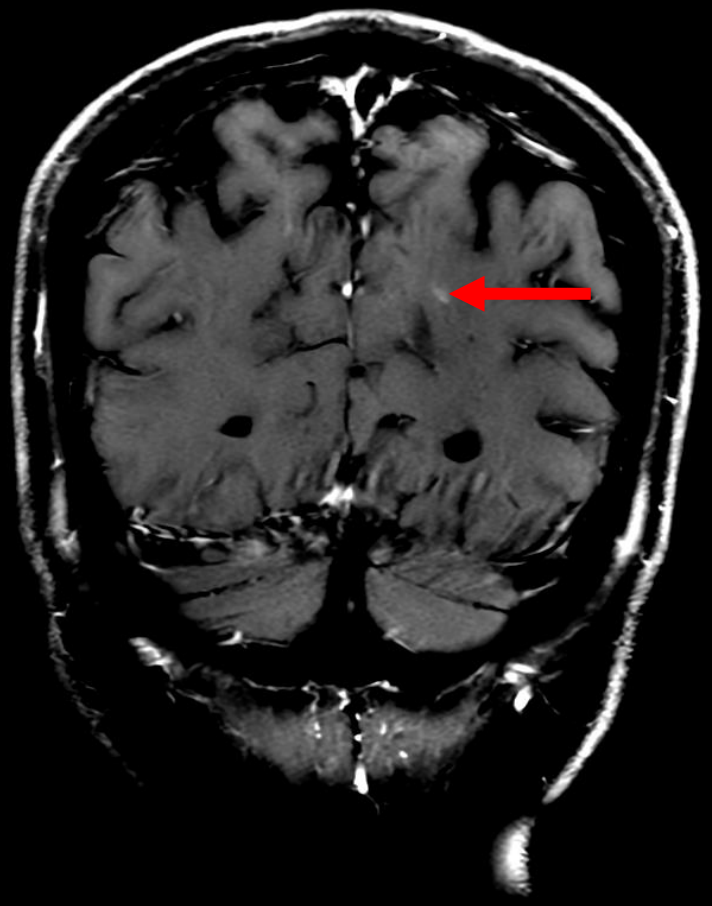

2D T1 C+

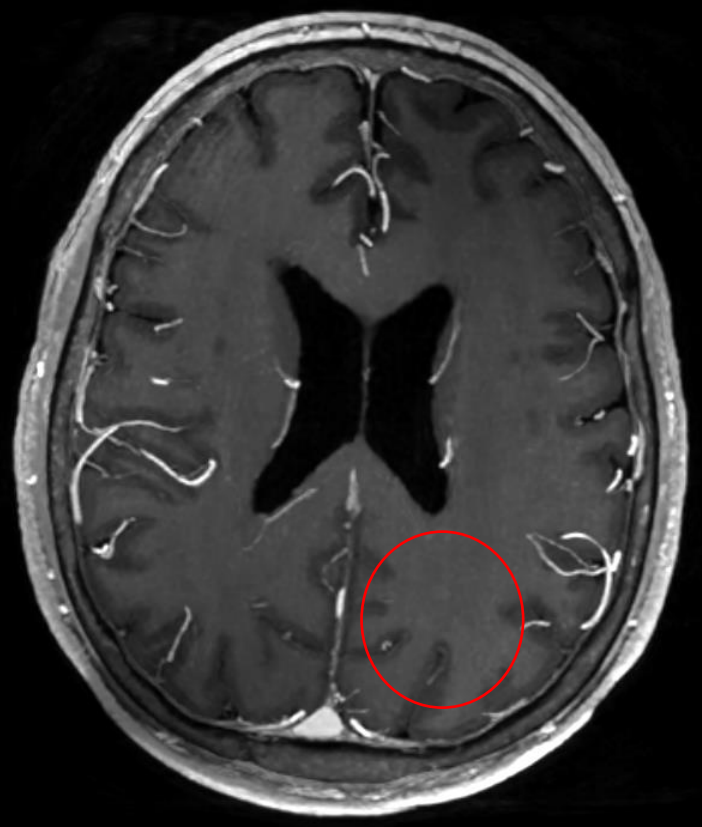

3D MPRAGE C+

…some lesions are only seen on MP-RAGE

2D T1 C+

3D MPRAGE C+

Must look at both sequences!

LAVA/VIBE

- Liver Acquisition with Volume Acceleration (LAVA, GE) and Volumetric Interpolated Breath-hold Examination (VIBE, Siemens)
- Mechanism
  - 3D gradient-echo T1-weighted sequence that uses the Dixon technique (see FLEX) to acquire in-phase and out-of-phase images in a single breath-hold
- Uses
  - Post-contrast sequences in spine, neck, body
  - Only T1-weighted, not applicable for T2 weighted images
- Pros:
  - Thin isotropic 3D
  - Fat-suppressed
  - Fast enough for breath-hold and multiphase dynamic post-contrast
- Limitations:
  - Interpolation blur
  - Lower SNR per voxel
  - Fat-sat failure
  - Susceptibility near air/metal/interfaces

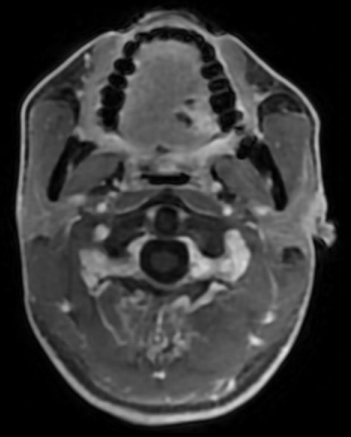

Water: Ax LAVA T1 FS C+

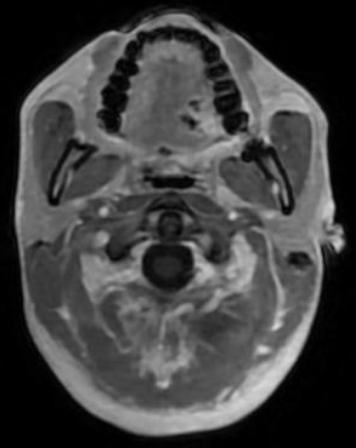

InPhase: Ax LAVA T1 FS C+

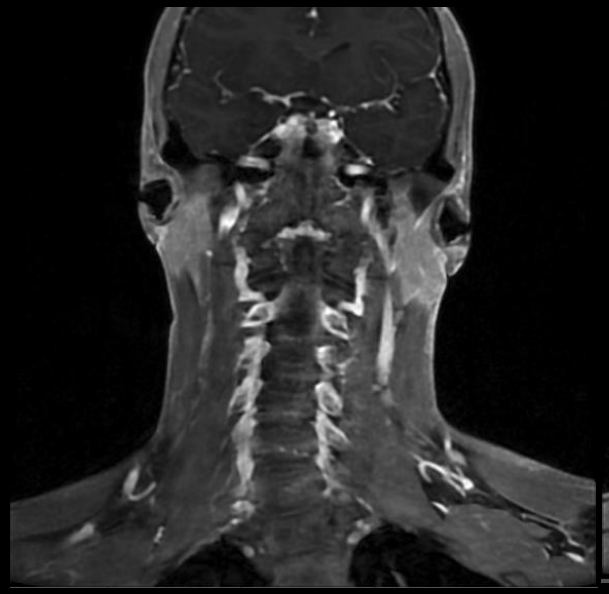

Water: Cor LAVA T1 FS C+

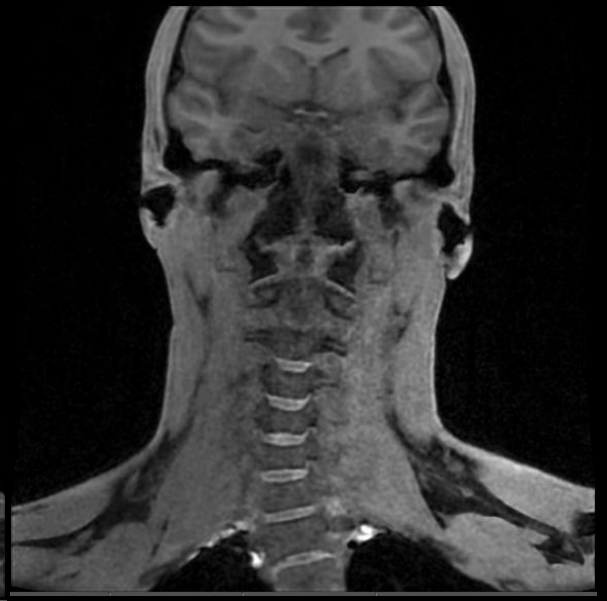

Water: Cor LAVA T1 FS

Back to techniques

Post-contrast Acquisition Timing

- T1 C+:
  - Peak T1-shortening effects of gadolinium occurs 5–10 minutes after injection
  - Imaging should be performed at peak enhancement
- T2-FLAIR C+:
  - Performed immediately after gadolinium administration while waiting for peak enhancement on T1+C sequences

Back to techniques

Post-contrast Brain protocols

Brain C+	Default
Brain Mets	Leptomeningeal (infection, mets)
Brain Tumor	Primary* brain tumor (glioma)

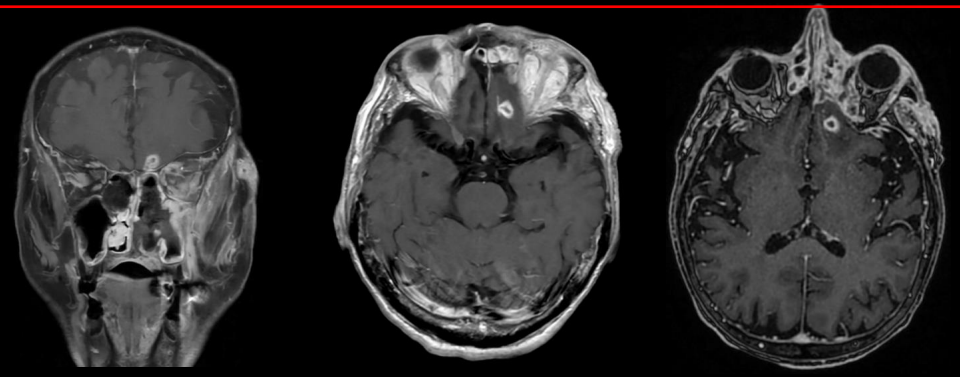

Cor T1 FS +C | Ax T1 +C | T1 MP-RAGE +C

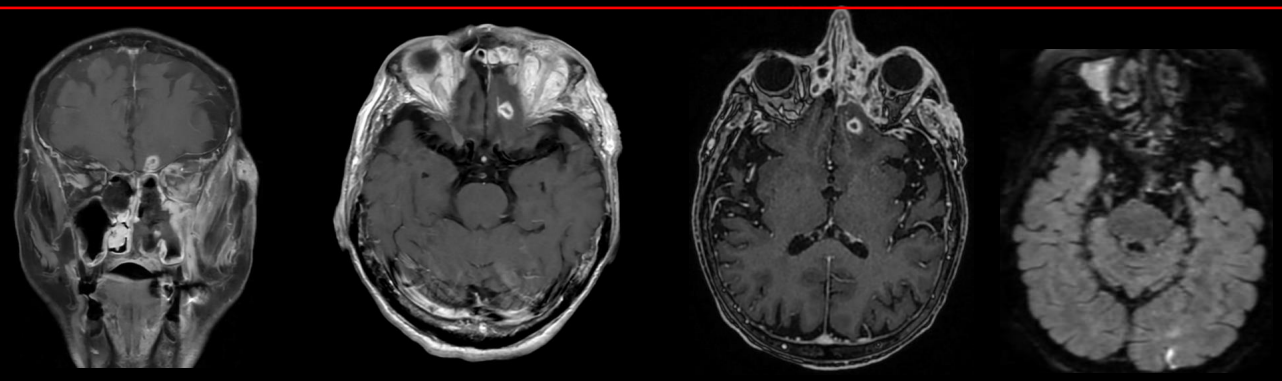

Cor T1 FS +C | Ax T1 +C | T1 MP-RAGE +C | T2 FLAIR CUBE +C

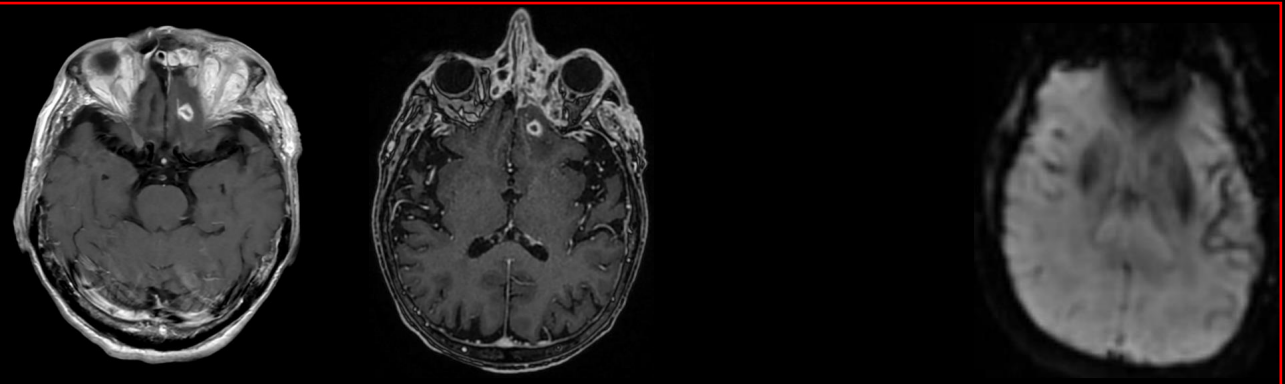

Ax T1 +C | T1 MP-RAGE +C | DSC Perfusion C+

Back to techniques

PROPELLER

- Periodically Rotated Overlapping Parallel Lines with Enhanced Reconstruction
  - Motion-resistant multi-shot fast spin-echo
  - BLADE for Siemens
  - Acquires k-space in rotating blades, reducing motion and pulsation artifacts
  - Used in both T1 and T2 FSE, DWI
  - Scan time longer than standard

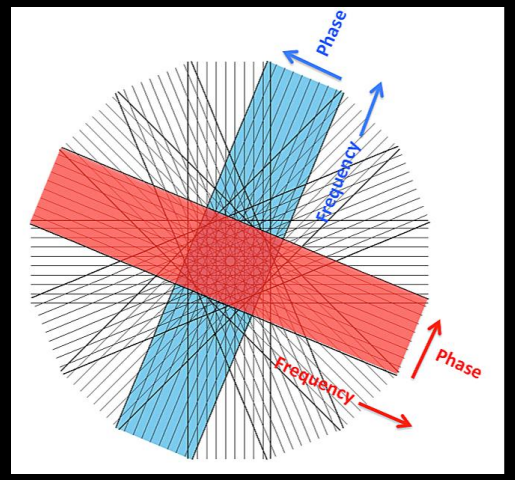

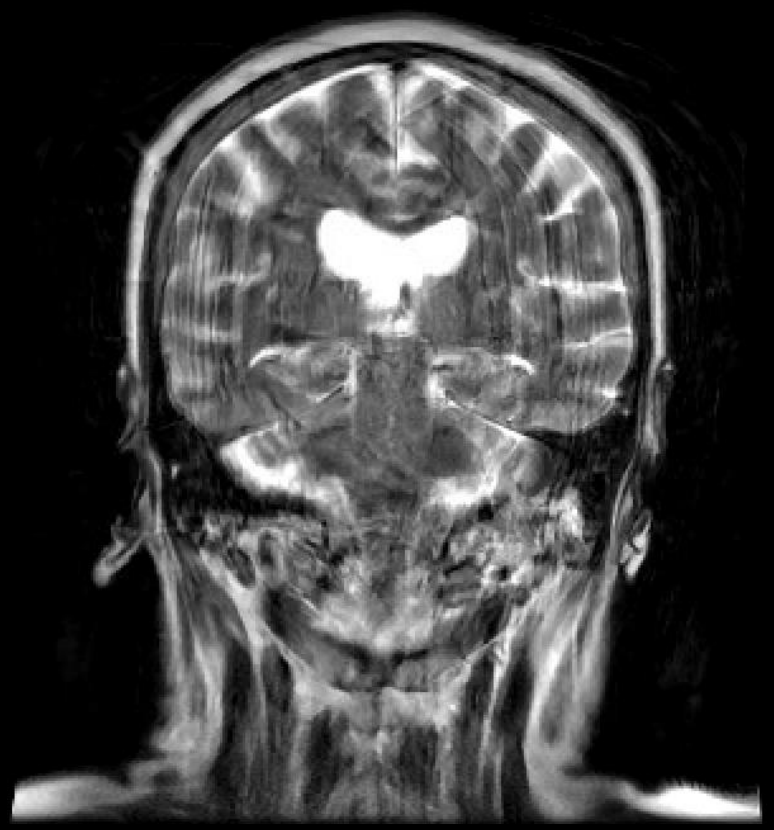

Cor T2

Cor T2 PROP

Back to techniques

STIR

- STIR (Short TI Inversion Recovery):
  - TIRM (Turbo Inversion Recovery Magnitude) on Siemens
  - Fat-suppressed T2-weighted inversion recovery sequence
  - Cannot be used post-contrast (nulls enhancement)
- STIR vs. T2 spin echo:
  - Fat Suppression Method:
    - STIR: Uses inversion recovery (short TI) to null fat signal based on T1 relaxation.
    - T2 Fat-Sat: Uses frequency-selective fat saturation pulses based on chemical shift difference between fat and water.
  - Field Inhomogeneity Sensitivity:
    - STIR: Insensitive to magnetic field inhomogeneity — performs reliably near metal, air-tissue interfaces, or implants.
    - T2 Fat-Sat: Susceptible to field inhomogeneity — fat suppression may fail near hardware or in areas with poor shimming (e.g., skull base, sinuses).
  - Signal-to-Noise Ratio:
    - STIR:
      - Lower SNR compared to spine echo
      - Contrast-to-noise for certain lesions may be higher
    - T2
      - Generally higher SNR
  - Speed
    - STIR takes longer, T2 is faster

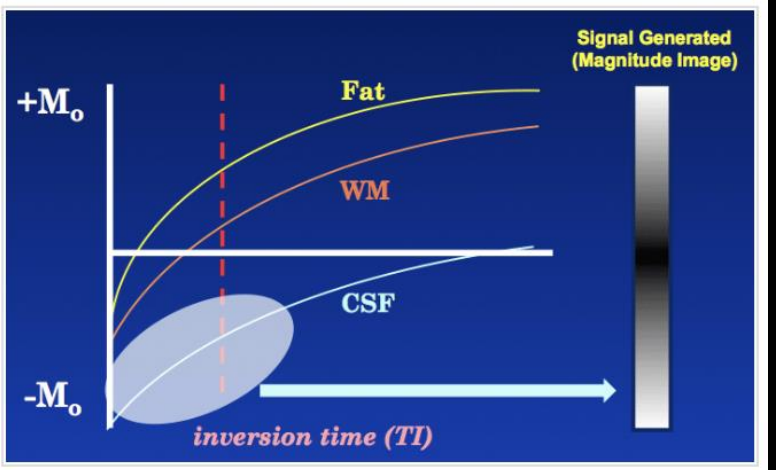

At short to medium TI's, long T1 substances (such as CSF) are bright on magnitude IR. This is opposite to SE where long T1 values cause reduced signal intensity.

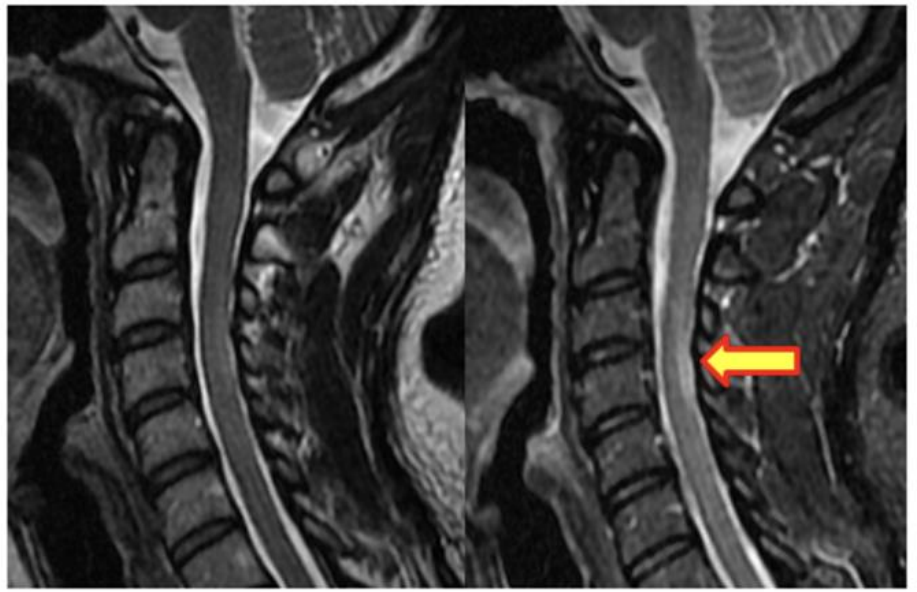

Additive T1 and T2 effects. MS plaque seen better on STIR image (right) than SE image (left)

On STIR, even if the overall image is grainier (lower SNR), the lesion is easier to detect because of the strong signal difference relative to background.

Back to techniques

SWAN

- Susceptibility-Weighted Angiography
  - 3D multi-echo GRE sequence with magnitude and filtered phase combination
  - SWI on Siemens
  - Highlights susceptibility effects from blood products (paramagnetic), iron and calcium (diamagnetic)
  - Used for microbleeds, hemorrhage, thrombosis, calcification, and venous structures

Table 1: Overview of Susceptibility-Sensitive Sequences for MRI Vendors

Handedness	Sequence Name	Paramagnetic: Probable Microbleed	Diamagnetic: Probable Microcalcification
Left-handed		Hyperintense on phase images	Hypointense on phase images
Siemens	SWI		
Canon	FSBB		
Philips	3D GRE raw data		
Right-handed		Hypointense on phase images	Hyperintense on phase images
United Neusoft	SWI		
GE Healthcare	SWAN		
Philips	3D SWIp		

Note.— FSBB = flow sensitive black blood, GRE = gradient echo, SWAN = susceptibility-weighted angiography, SWI = susceptibility-weighted imaging, SWIp = SWI with phase enhancement, 3D = three-dimensional.

Back to techniques

SWAN - Interpretation

- Step 1: Determine handedness of scanner
  - GE scanners are right-handed, so paramagnetic substances (blood) will appear hypointense on phase map, diamagnetic substances (calcium) will appear hyperintense
  - Use internal cerebral veins as an internal control to verify
- Step 2: If there is both hyperintense and hypointense signal present, use the dipole effect to troubleshoot
  - Dipole effect:
    - Predictable blooming artifact (magnetic field distortion pattern) that extends along the direction of B_0 (craniocaudal) caused by a localized susceptibility source
    - Diagram (right) is for right-handed scanners (GE), would be opposite for left-handed scanners (Siemens)

Calcification (diamagnetic)



Blood (paramagnetic)



Confirmed bleed (paramagnetic)

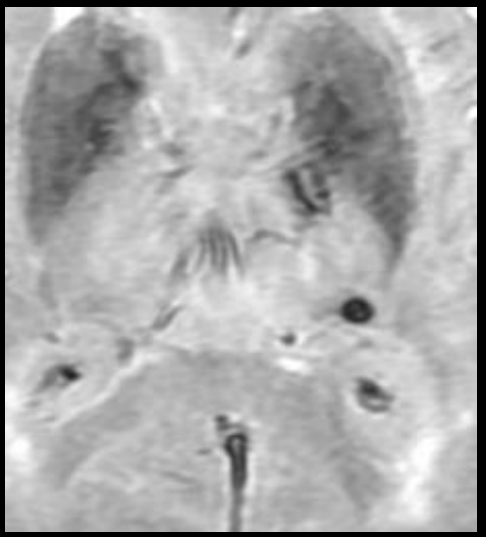

SWAN

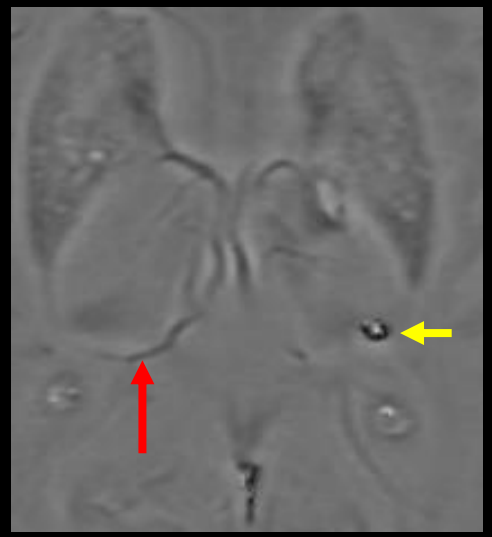

Phase

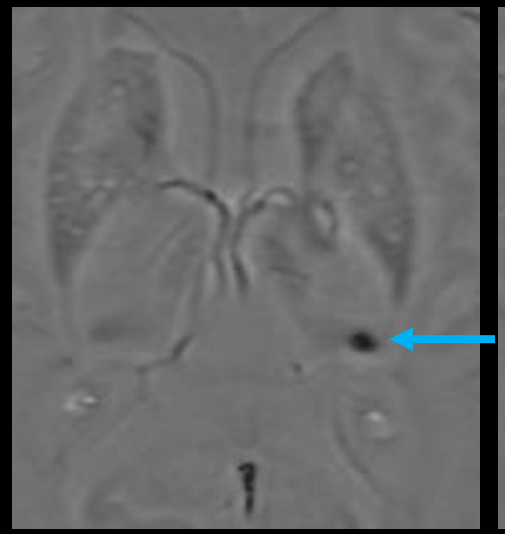

Slice above

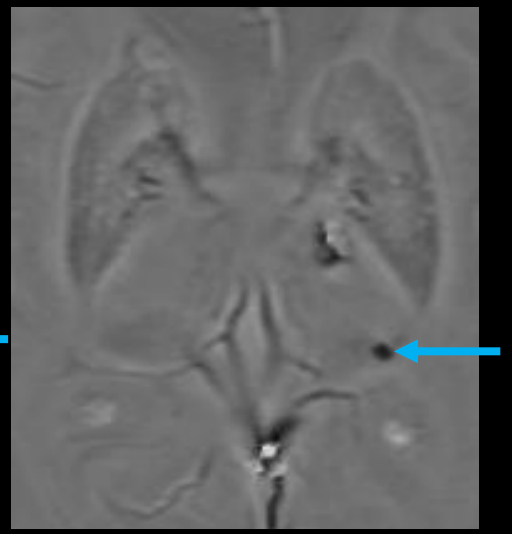

Slice below

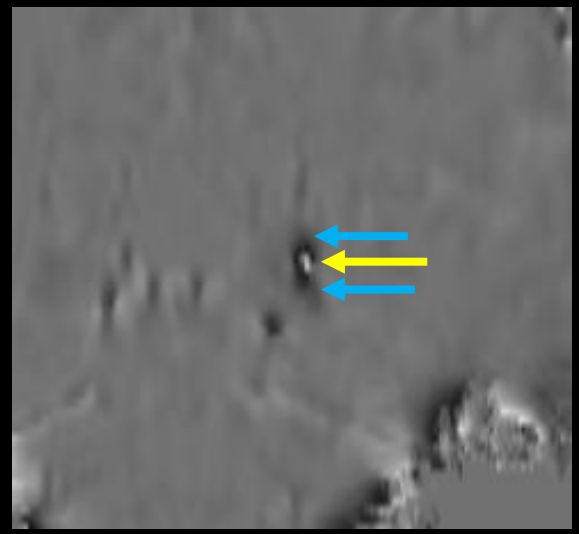

Coronal

TOF

- Time of Flight
  - A non-contrast technique that visualizes flow-related enhancement from inflowing unsaturated blood
  - T1 weighted 2D or 3D gradient echo with short TR/TE and high flip angle (such as FSPGR)
  - Suffers from saturation in slow flow or in-plane flow
  - 3D MOTSA (Multiple Overlapping Thin Slab Acquisition) often used for neck

2D TOF

- Fine slices are stacked alongside each other
- Sensitive to slow flows (which do not remain in the slice for long and will therefore not be saturated)
- Poor spatial resolution along the axis of the slice stack

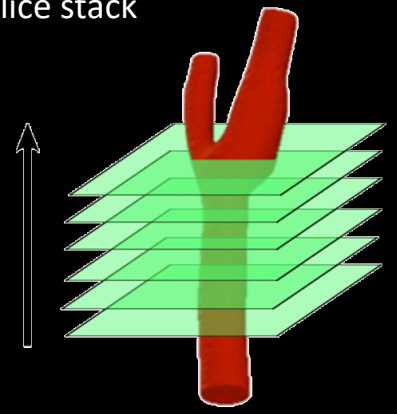

3D TOF

- Good spatial resolution in all 3 planes
- Better signal-to-noise ratio
- Longer acquisition

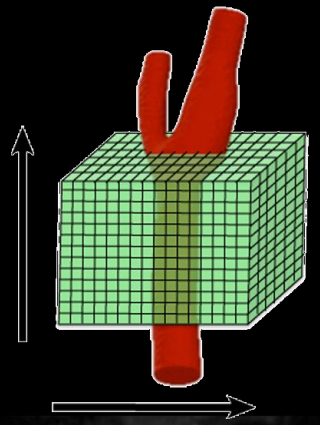

Back to techniques

TOF

- Stationary tissue becomes saturated by repeated RF pulses
- Blood flow perpendicular to imaging plane is not saturated and has high signal ("flow-related enhancement")

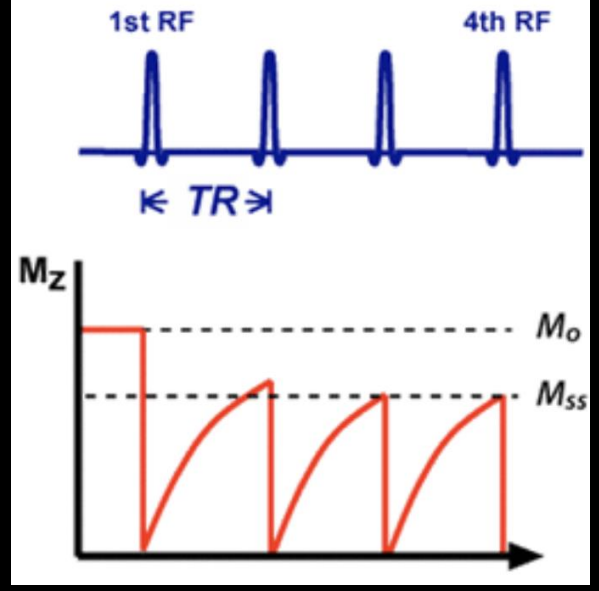

Adapted from https://doi.org/10.1148/rg.2021210141

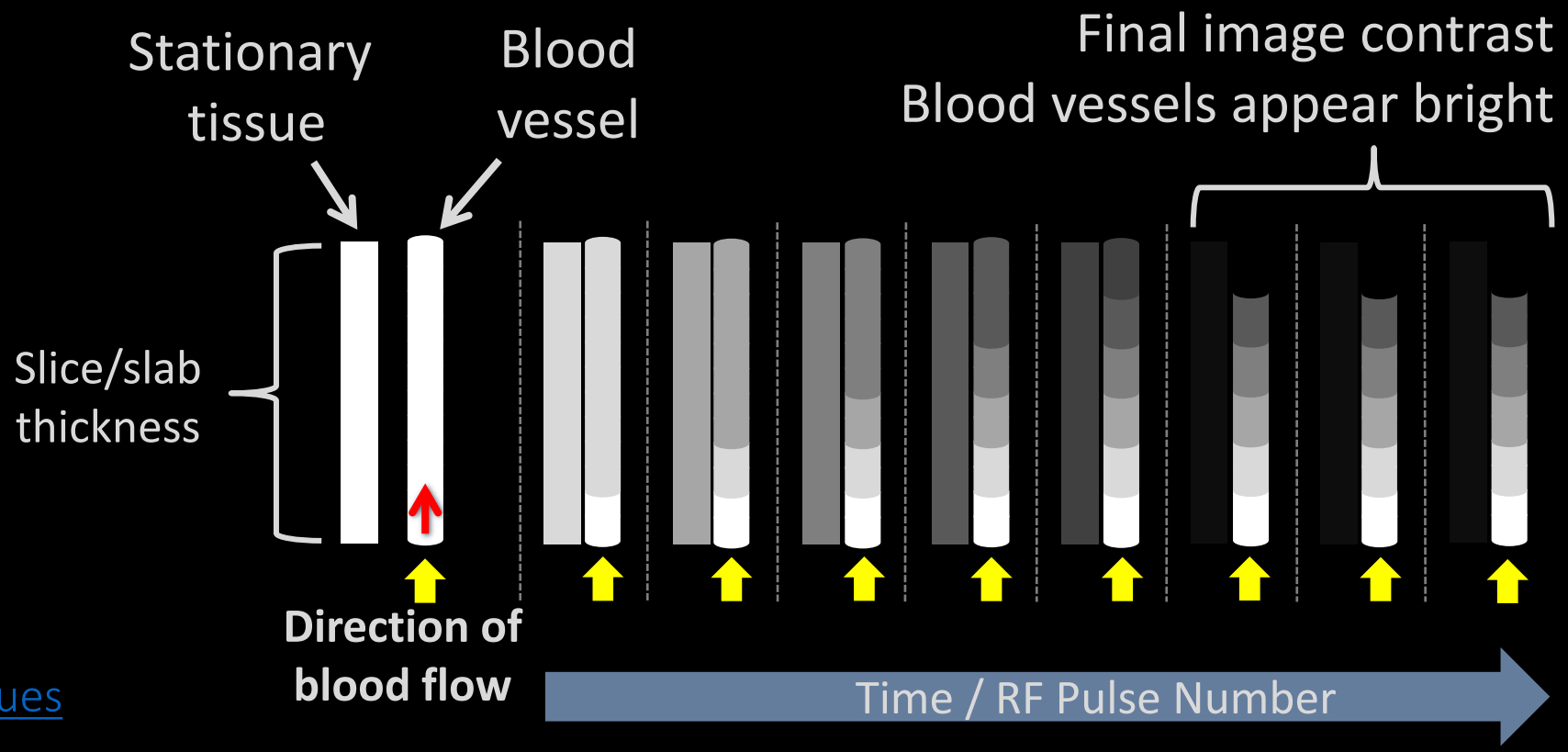

Back to techniques

TRICKS

- Time-Resolved Imaging of Contrast Kinetics
- 3D contrast-enhanced acquisition by sampling central k-space (AKA keyhole) more frequently than peripheral k-space
- Generates multiple time-resolved frames during contrast bolus passage Useful for evaluating vascular malformations, dAVFs, and high-flow lesions
- Can be applied to brain, spine, and peripheral vascular imaging
- Pros
  - Excellent temporal resolution
  - Allows visualization of arterial, capillary, and venous phases in a single acquisition
- Limitations
  - Lower spatial resolution than conventional single-phase CE-MRA
  - Requires gadolinium contrast

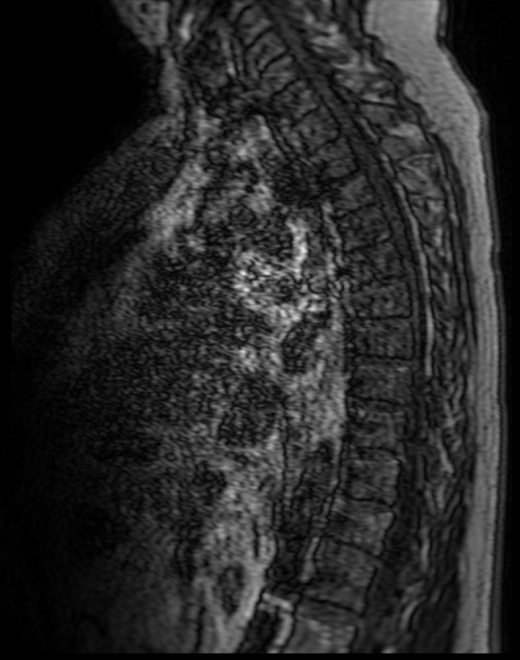

Sag TRICKS (mask)

SUB:Sag TRICKS (composite)

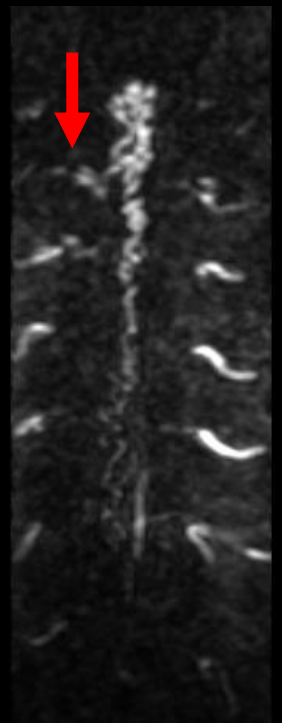

Subtraction coronal MPR

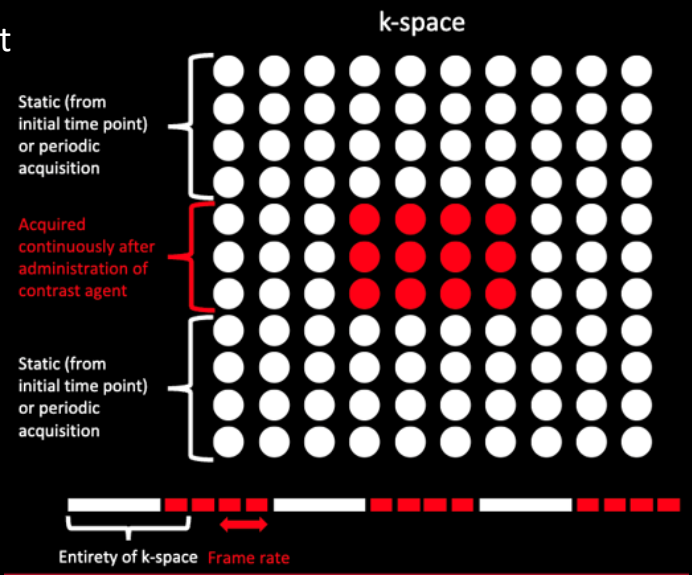

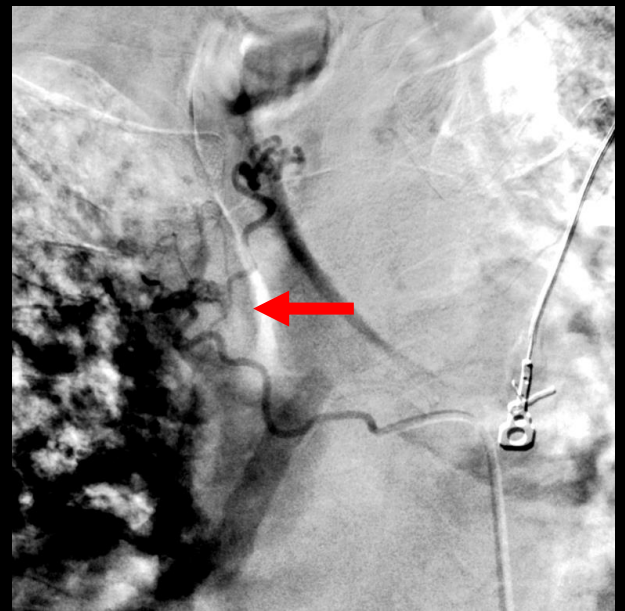

Early filling at T6 feeding cluster of vessels in the spinal canal, confirmed on DSA

Back to techniques

UCSD Neuroradiology MRI Protocols

Table of contents

MRI NEURO

Protocol	Brain · MR Angiogram · Head and Neck · Spine · Show All
Brain MRI	Brain W/O · Brain +C · Brain Mets · Brain Tumor · Brain VWI +C · Ant Skull Base + Sella · SRS/Brainlab · Pre-DBS · Spectroscopy
--	MS W/O · MS W/O LQ · MS +C · MS +C LQ
--	Epilepsy W/O · Epilepsy +C
--	Brain WO ARIA · Neuro Quant W/O · Neuro Quant +C
--	Neonate HIE +Spectroscopy · Neonate · Fetal
--	Neurocritical Care · Acute Stroke
--	CSF Flow - NPH · CSF Flow - Chiari · CSF Flow - Shunt · fMRI Guo/Hawley · Custom
MR Angiogram	Head MRA W/O · Head MRA +C · Custom MRA · VWI Head MRA W/O
--	Head MRV W/O · Head MRV +C
--	Neck MRA W/O · Neck MRA +C · Spine MRA
Head and Neck MRI	Face W/O · FACE + C + Brain Lab · Neck W/O · Neck + C · Sella W/O · Sella + C · Orbit W/O · Orbit + C · IAC W/O · IAC + C · Trigeminal W/O · Trigeminal + C · Glossopharyngeal+C · Custom
Spine MRI	C-Spine W/O · C-Spine + C · C-Spine Trauma · C-Spine CCJ · C-Spine MS W/O · C-Spine MS + C
--	T-Spine W/O · T-Spine +C · T-Spine Trauma · T-Spine MS W/O · T-Spine MS +C
--	L-Spine W/O · L-Spine +C · L-Spine Trauma · Spine Survey

Back to protocols

Brain

MRI NEURO

Protocol	Brain, MR Angiogram, Head and Neck, Spine, Show All
Brain MRI	Brain W/O, Brain +C, Brain Mets, Brain Tumor, Brain VWI +C, Ant Skull Base + Sella, SRS/Brainlab, Pre-DBS, Spectroscopy
--	MS W/O, MS W/O LQ, MS +C, MS +C LQ
--	Epilepsy W/O, Epilepsy +C
--	Brain WO ARIA, Neuro Quant W/O, Neuro Quant +C
--	Neonate HIE +Spectroscopy, Neonate, Fetal
--	Neurocritical Care, Acute Stroke
--	CSF Flow - NPH, CSF Flow - Chiari, CSF Flow - Shunt, fMRI Guo/Hawley, Custom

Back to protocols

Brain WO

- Indication:
  - New focal neurologic defect, fixed or worsening (suspected stroke)
  - Altered mental status
  - Dementia
  - Psychiatric disorder
  - Headaches
  - Symptomatic subacute or chronic head trauma
- Sequences:
  1. Sag T1 (FSE or FLAIR)
  2. Ax T1 (FSE or FLAIR)
  3. Ax T2 FSE
  4. Ax T2 FLAIR FS
  5. Cor T2 FSE
  6. Ax DWI / ADC / B0
  7. Ax 3D SWAN
  8. Ax 3D ASL

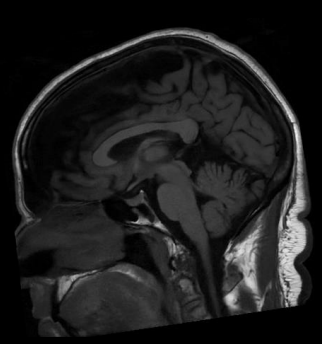

T1

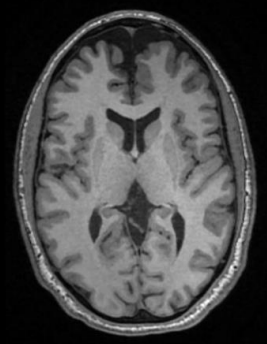

T1

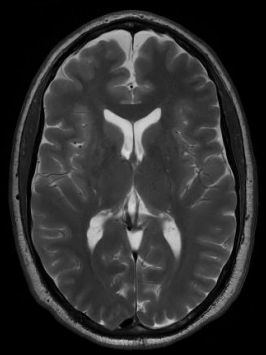

T2

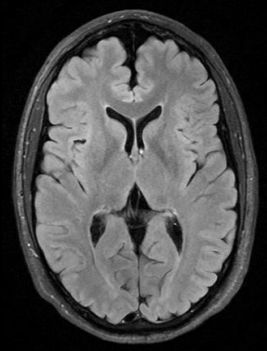

T2 FLAIR

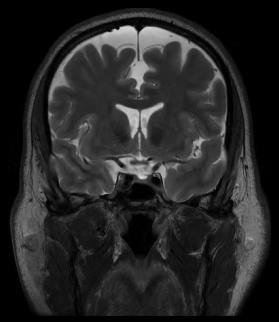

T2

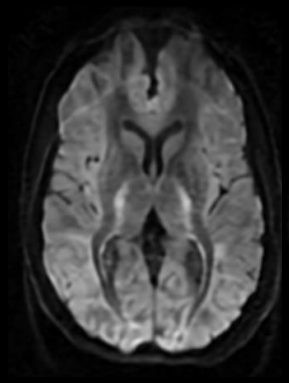

DWI

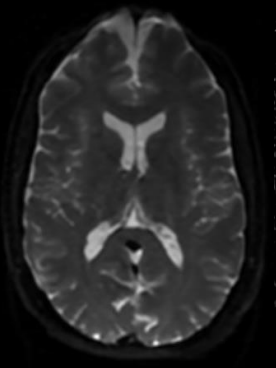

B0

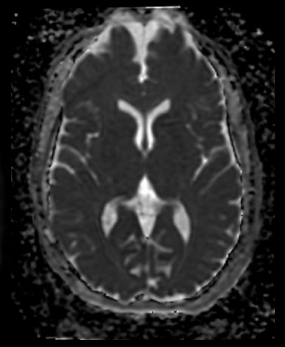

ADC

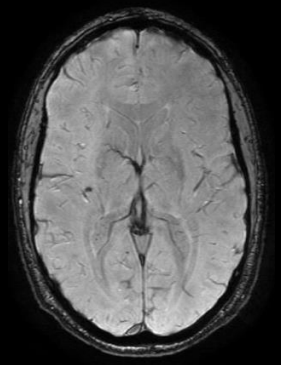

SWAN

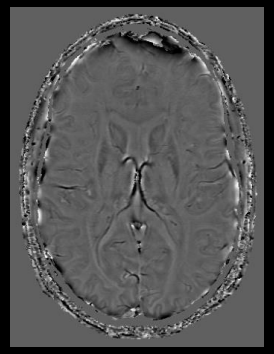

Phase map

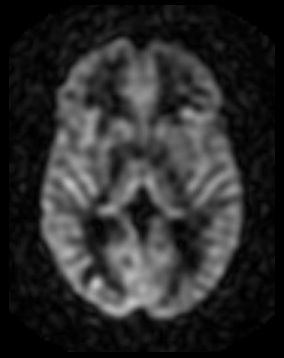

ASL

Back to protocols

Acute Stroke

Stroke MRI Protocol: DWI, T2*GRE/SWAN, FLAIR and ASL perfusion imaging. MRA head or MRA Neck only if patient did not have CTA and is stable to continue. No additional sequences will be added. If the patient is moving during the DWI, the exam will not continue. *We do not do contrast MR perfusion for stroke codes.*

- Indication:
  - Abbreviated MRI appropriate for patients in the 6-24 hour or wake-up stroke window. The following steps must be taken:
    - Stroke team must put in “Acute Stroke Brain MRI” and MRA orders (if vessel imaging not performed by CTA)
    - Head CT and CXR screen for metal
    - Stroke Leader Calls MRI to discuss ETA and logistics
    - Radiologist calls MRI to give them a heads up and that metal was screened for
    - No discussion between stroke team and radiology is required
    - If the patient is moving during the DWI, the exam will not continue
- Sequences:
  - Standard
    - Ax DWI / ADC / B0
    - Ax FLAIR FSE
    - Ax SWAN
    - Ax ASL
  - If no CTA vessel imaging obtained
    - MRA is obtained

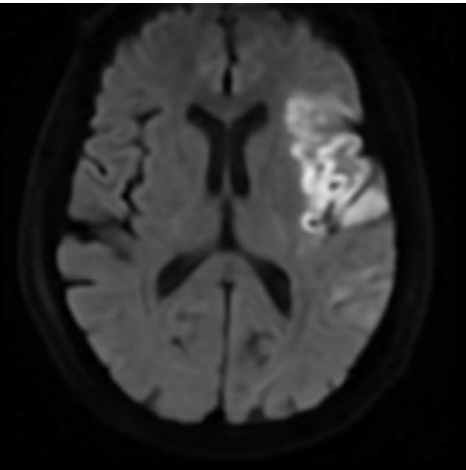

DWI

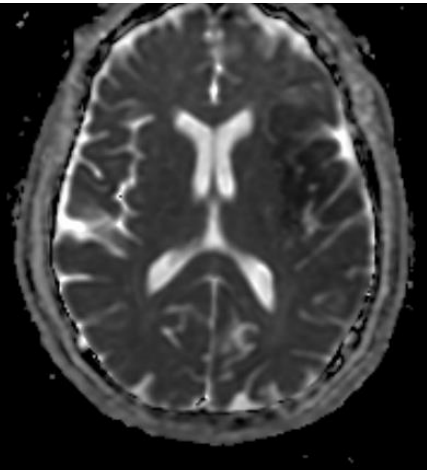

ADC

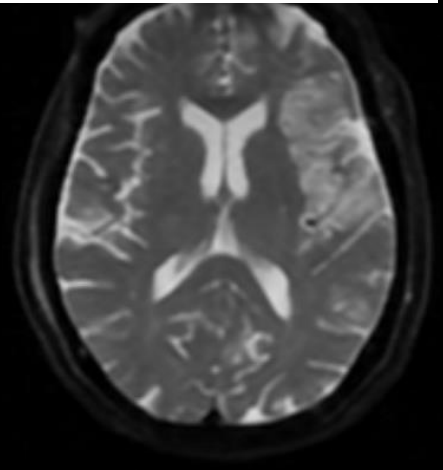

B0

T2 FLAIR

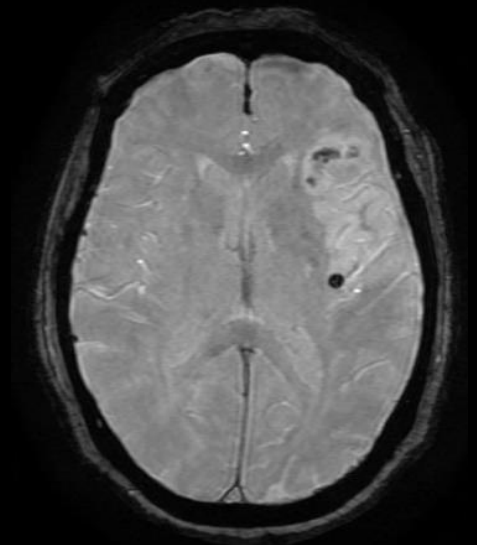

SWAN

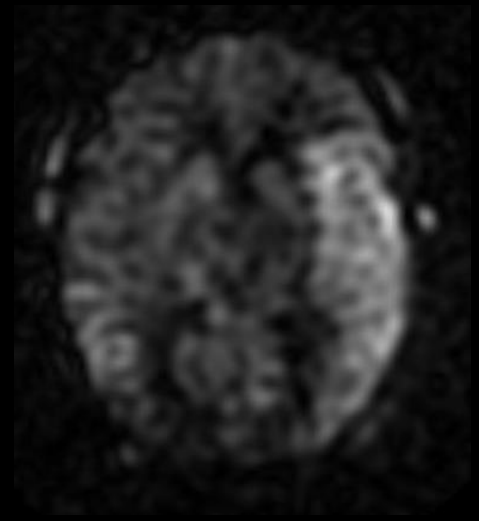

ASL

Back to protocols

Brain C+

- Indication
  - Infection
  - TIA
  - Parenchymal hemorrhage of uncertain etiology
  - Ataxia
  - Headache
  - Worsening mental status despite clinical management of the suspected underlying cause (intoxication, medication-related, hypoglycemia, sepsis)
- Sequences:
  - Brain WO protocol PLUS
    - SAG T2 FLAIR CUBE
    - Axial T1 +C (FSE or FLAIR)
    - Coronal T1 +C (FSE or FLAIR)
    - Axial T1 MPRAGE +C

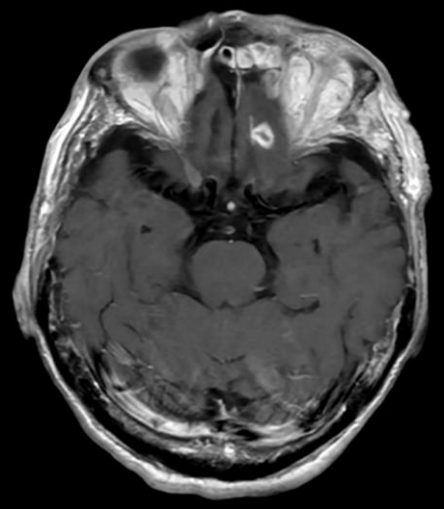

Ax T1 +C

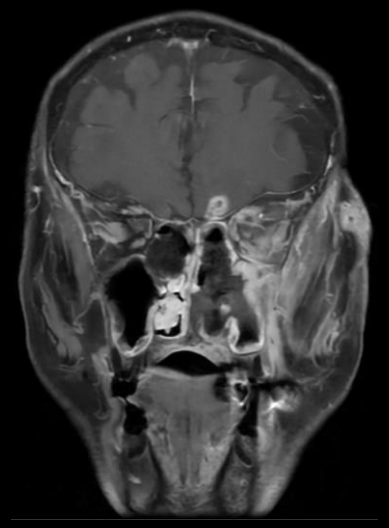

Cor T1 +C

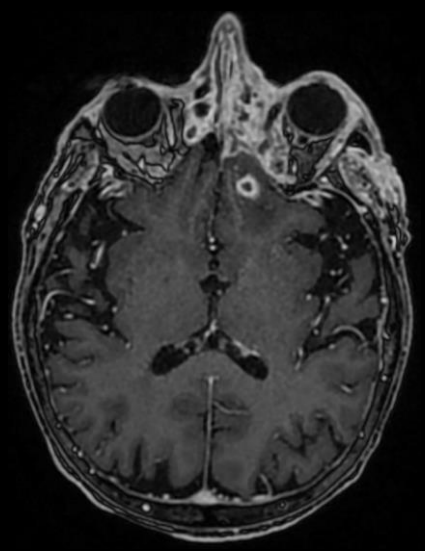

T1 MP-RAGE +C

Back to protocols

Brain Mets

- Indication
  - Metastatic brain lesions and meningiomas
  - Do not use for primary brain tumors (use brain tumor protocol)
    - If primary brain tumor and assessing leptomeningeal involvement, brain mets can be appropriate
- Sequences:
  - Brain WO protocol PLUS
    - Axial T1 +C (FSE or FLAIR)
    - Coronal T1 +C (FSE or FLAIR)
    - 3D Sag T1 MPRAGE +C
    - 3D Sag T2 FLAIR CUBE +C

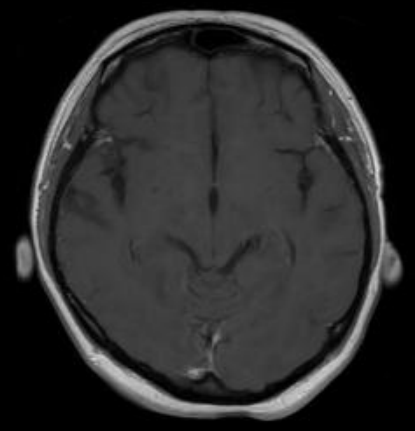

Ax T1 +C

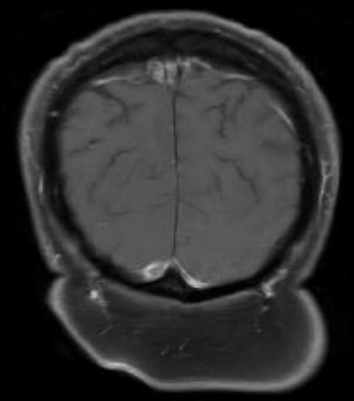

Cor T1 +C

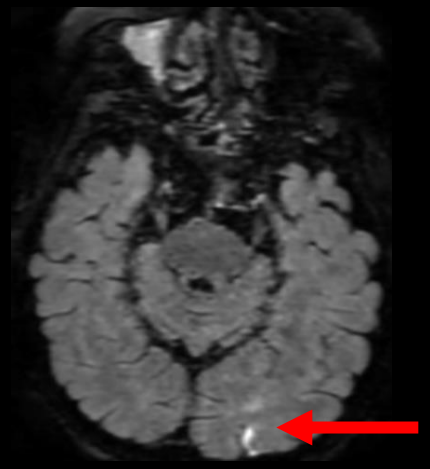

T2 FLAIR CUBE +C

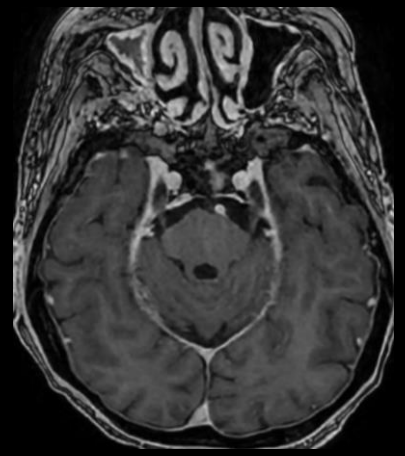

T1 MP-RAGE +C

Leptomeningeal metastases occult on other sequences

Back to protocols

Brain Tumor

- Description:
  - Used for primary brain tumors, eg GBM, meningioma, medulloblastoma, etc
  - Do not use for metastatic brain disease
- Sequences:
  - Brain +C protocol
    - MINUS
      - Cor T1 FS C+
    - PLUS
      - Sag T1 MP-RAGE (plus reformats)
      - Sag T2 FLAIR FS CUBE (noncontrast)
      - Perfusion C+
      - Perfusion Field Map C+
      - Diffusion tensor imaging

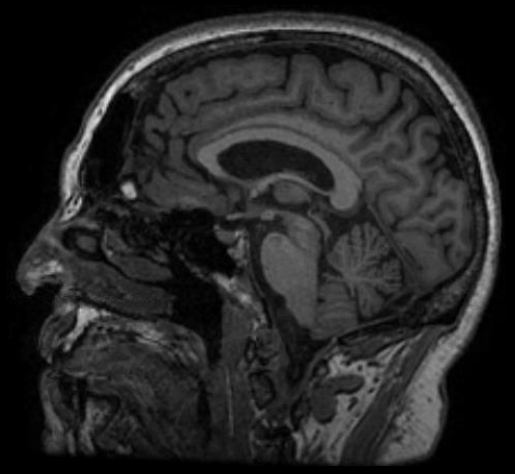

Sag T1 +MP-RAGE

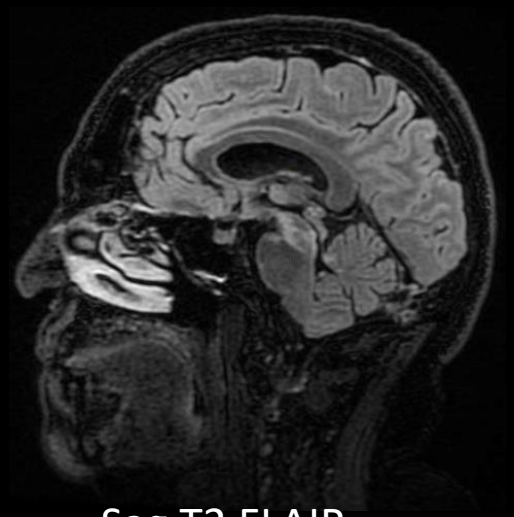

Sag T2 FLAIR

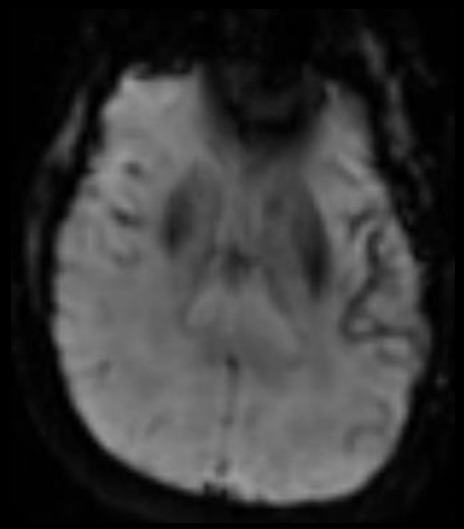

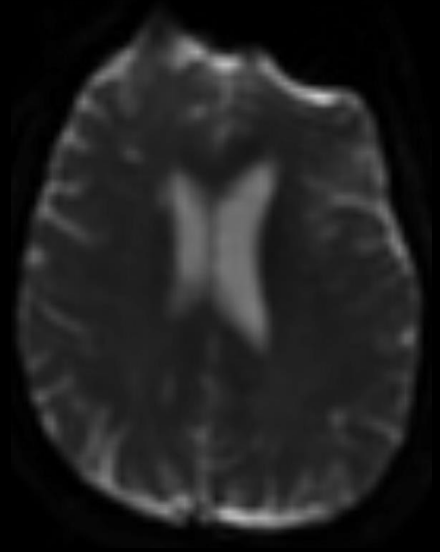

DSC Perfusion C+

Back to protocols

Brain Operative Planning (epic button pending)

- For brain masses in the immediate post-operative period (24-72 hours), a full “Brain Tumor” protocol is not necessary. There is no prebuilt “epic” protocol button for this, but you can choose “Brain Mets” sequence and add any additional sequences requested by ordering (eg, T2 CUBE)
- Example:
  - “Reason for exam: Brain mass, include pre-post-contrast T1 FSPGR, T2 CUBE sagittally acquired with axial and coronal recons, sagittal FLAIR, Brainlab and DTI.”
- Sequences:
  - Can use “Brain mets” and add other requested sequences (eg, T2 CUBE)

Back to protocols

Epilepsy (WO or W/WO)

- Indication:
  - Epilepsy
  - New seizure
- Sequences:
  - Brain WO protocol PLUS
    - Sagittal T1 MP-RAGE
    - Coronal oblique T2 FSE
    - Coronal oblique T2 FLAIR
  - Optional
    - Axial and coronal T1 +C
    - Sagittal T1 MP-RAGE +C

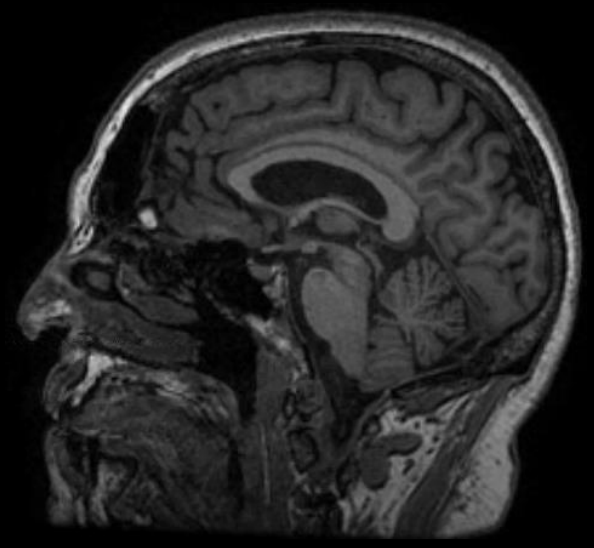

MP-RAGE

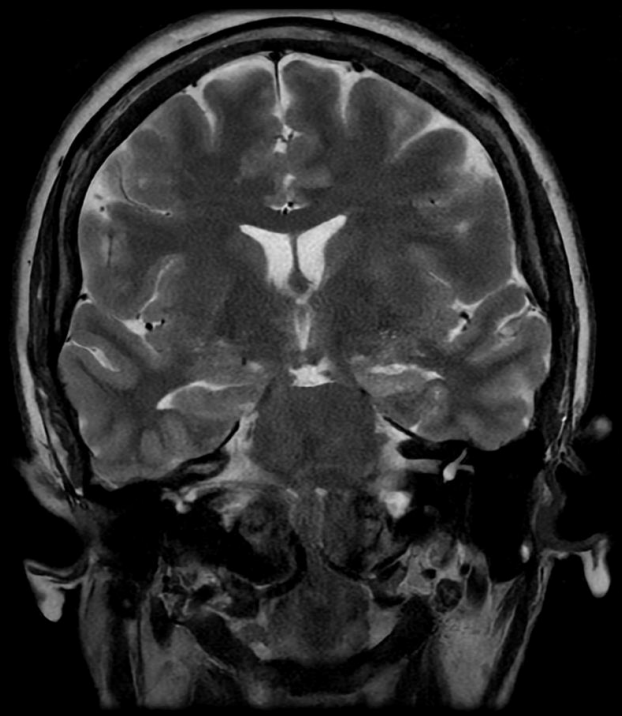

Cor oblq T2 FSE

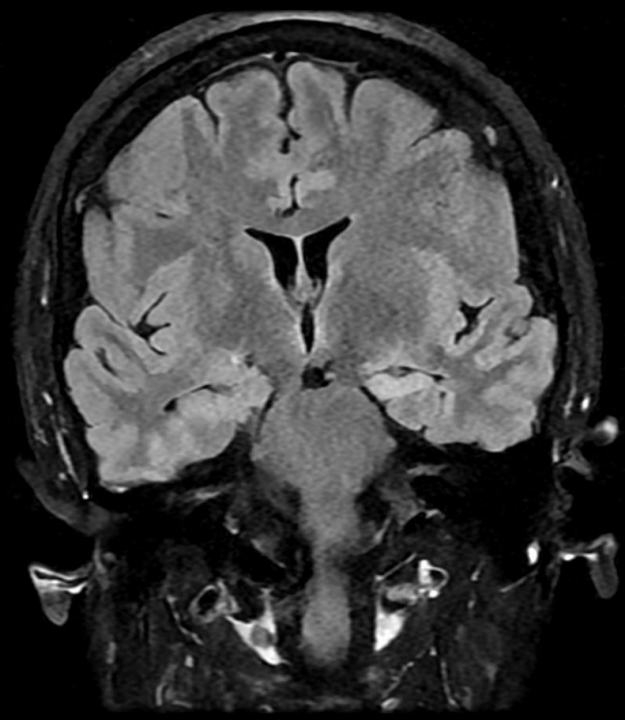

Cor oblq T2 FLAIR

Coronal oblique sequences should be thin section and perpendicular to the long axis of the hippocampus.

Back to protocols

MS (WO or W/WO, +/- lesionquant)

- Indication:
  - Multiple sclerosis or other demyelinating disease
  - Whether contrast is needed is variable, usually only if provider orders it, most often during initial work up and/or clinical progression/exacerbation
  - Follow up exams are most often WO contrast
- Sequences:
  - Brain WO protocol PLUS
    - Sag T1 FSPGR
    - Sag T2 FLAIR CUBE
    - Axial T1 +C (FSE or FLAIR)
    - Cor T1 FS +C FSE
- Notes
  - Does not include 3D post-contrast MP-RAGE

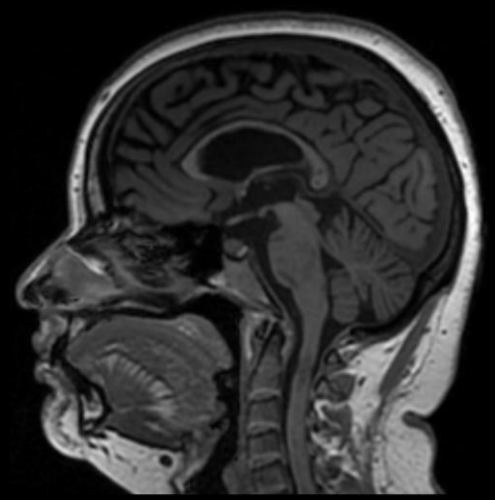

MP-RAGE

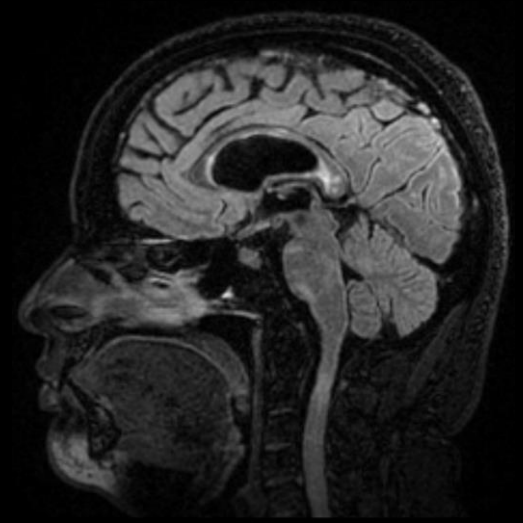

Sag T2 FLAIR CUBE

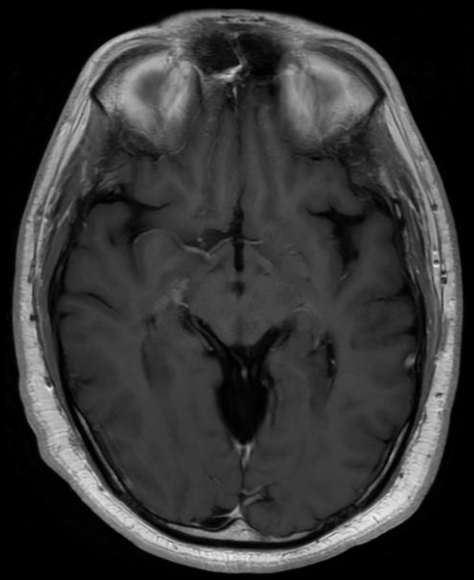

Ax T1 FSE C+

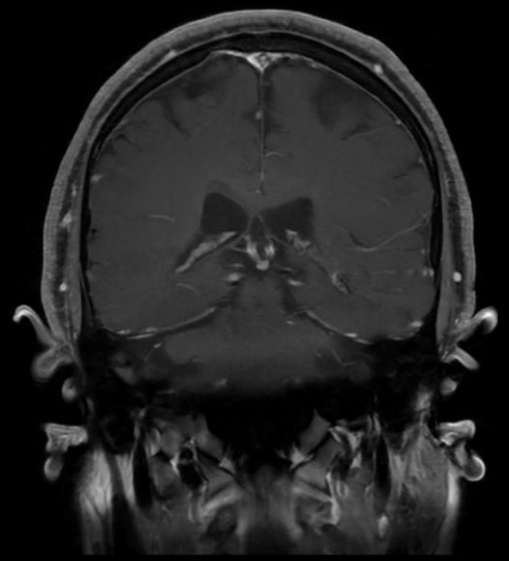

Cor T1 C+ FSE

Back to protocols

Ant Skull Base Brain + Sella

- Indication
  - Use for all “MRI Brain + Sella” orders, all pre-op or immediate post-op studies for sella or anterior skull base masses
  - Operative planning and neuronavigation MRI for complex sella and third ventricle lesions
  - Includes large field for endonasal approach planning and volumetric for neuronavigation
  - Sella/Pituitary protocol (head and neck section below) is superior for initial diagnosis of sella/pituitary abnormalities, which takes less time to perform and has option of adding dynamic post-contrast
- Sequences:
  - Whole brain FOV
    - Brain +C protocol PLUS
    - Sag T1 MP-RAGE (instead of FSE)
    - Sag T2 CUBE (no Cor T2 FSE)
  - Small FOV (including sella and sphenoid sinus)
    - Axial T1 FSE
    - Coronal T2 sella to include sphenoid sinuses
    - Sag T1 FS + C sella to include sphenoid sinuses
    - Cor T1FS + C sella to include sphenoid sinuses

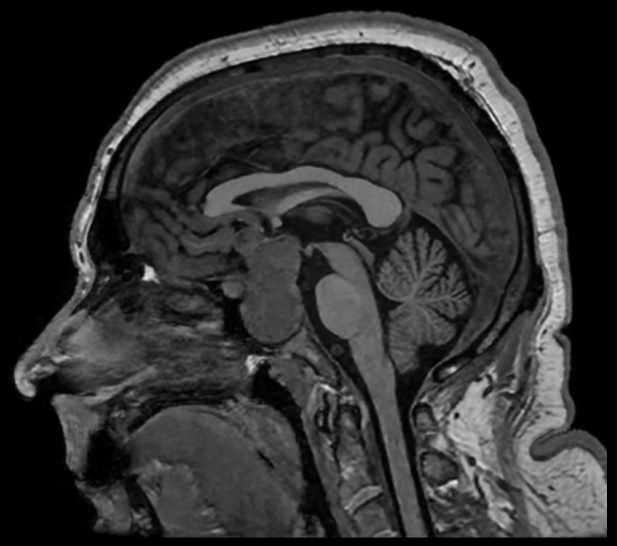

Sag T1 MP-RAGE
(replaces Sag T1 FSE)

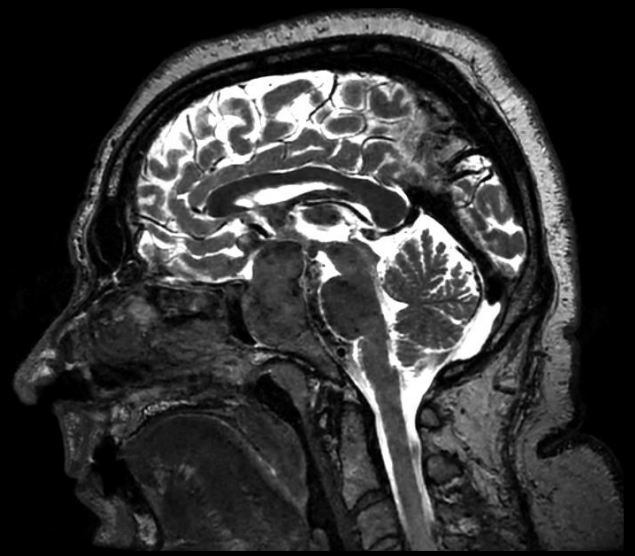

Sag T2 CUBE
(replaces Cor T2 FSE)

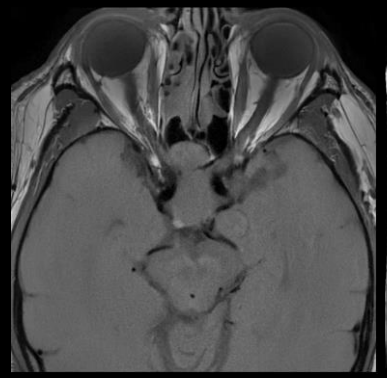

Ax T1 FSE

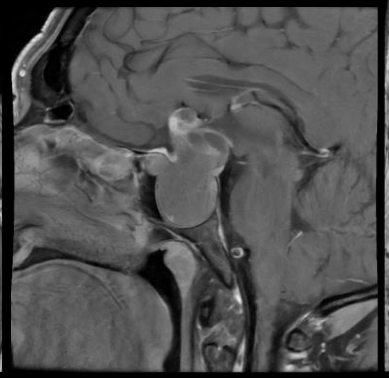

Sag T1 FS C+

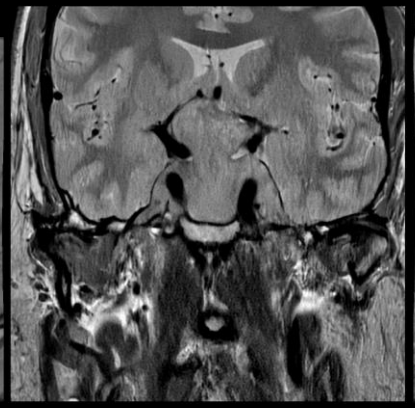

Cor T2 FSE

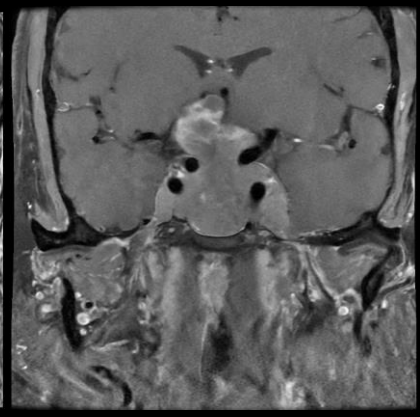

Cor T1 FS C+

Back to protocols

Brain Vessel Wall Imaging

- Indication:
  - Vasculitis
- Sequences: MRI + MRA of the head
  - Brain WO protocol
  - MINUS
    - Ax T1
    - Cor T2
  - PLUS
    - 3D T2 CUBE
    - 3D MDSE Pre (3.0T) or 3D T1 Cube FS POST (1.5T)
    - 3D MDSE C+ (3.0T) or 3D T1 Cube FS POST (1.5T)
  - MRA
    - Ax 3D TOF

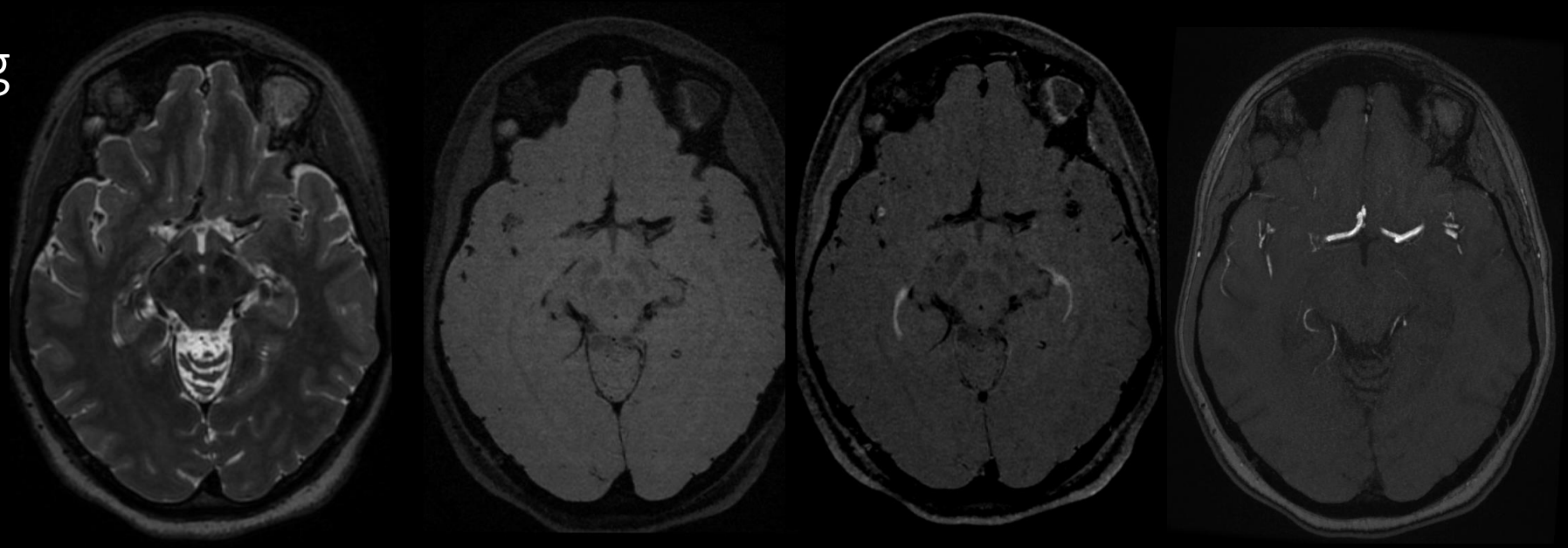

3D MDSE | 3D MDSE C+ | MRA TOF

3D MDSE | 3D MDSE C+ | MRA TOF

Circumferential vessel wall enhancement

Back to protocols

Head and Neck

MRI NEURO

Protocol	Brain, MR Angiogram, Head and Neck, Spine, Show All
Head and Neck MRI	Face W/O, FACE + C + Brain Lab, Neck W/O, Neck + C, Sella W/O, Sella + C, Orbit W/O, Orbit + C, IAC W/O, IAC + C, Trigeminal W/O, Trigeminal + C, Glossopharyngeal+C, Custom

Back to protocols

Face +/- BrainLab

- Indication
  - Bell's Palsy
- Coverage
  - AP: Nose through brainstem
  - CC: frontal sinuses through entire chin.
  - Use 20 cm FOV for face unless very large patient. Do not include entire neck.
  - Brain lab to cover parotid, face, and skull base
- Sequences:
  - Ax T1 PROP
  - Cor T1 PROP
  - SAG T1 PROP
  - Ax STIR PROP
  - Cor STIR PROP
  - Ax MUSE DWI
  - +C Ax T1 FS FLEX (Water)
  - +C Cor T1 FLEX (Water)
  - Ax +C 3D T1 FS ISO (Brain Lab with same coverage of the face and skull base)

Ax T1 prop

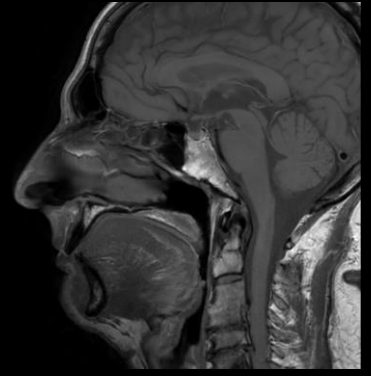

Sag T1

Cor T1 prop

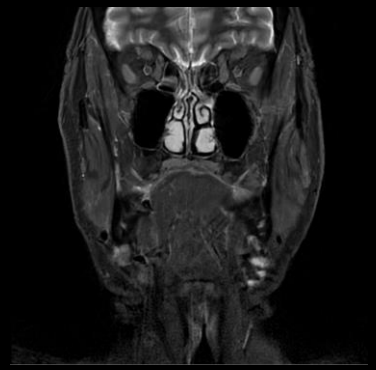

Cor STIR prop

Ax STIR PROP

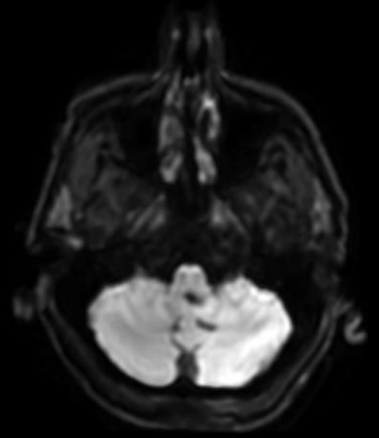

Ax MUSE DWI

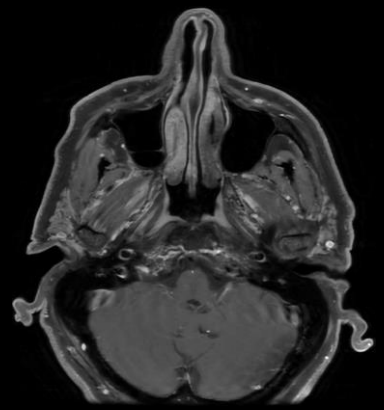

Water: +C Ax T1 FS FLEX

Ax +C 3D T1 FS ISO

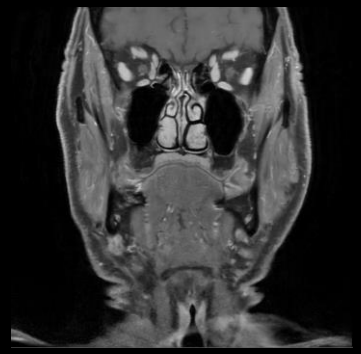

Water: +c Cor T1 FLEX

Back to protocols

Neck

- Indication
  - Tumor, infection
- Sequences:
  - Cor T1 PROP
  - Sag T1 PROP
  - Ax DWI MUSE
  - Ax T1 PROP
  - Cor STIR PROP
  - Cor T1 +C
  - Ax T1 +C
  - Dixon method:
    - Ax T2 (Water + In-Phase)
    - Ax T1 (Water + In-Phase)
    - Cor T1 (Water)
    - Sag T1 +C (Water)
    - Ax T1 +C (Water + In-Phase)
    - Cor T1 +C (Water)

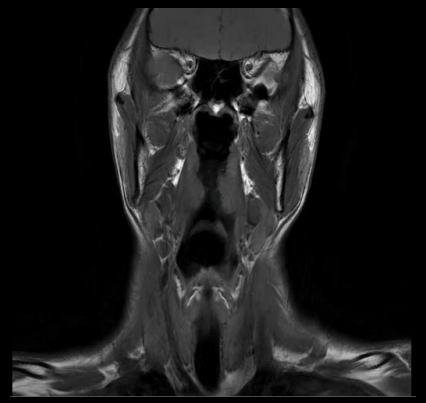

Cor T1 PROP

Sag T1 PROP

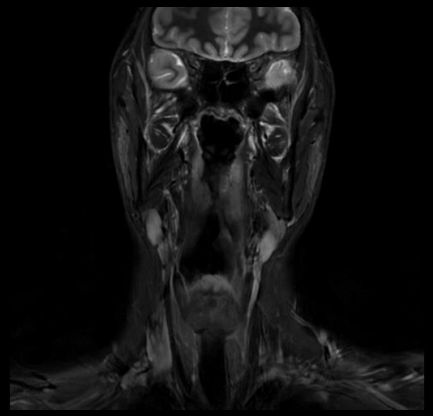

Cor STIR PROP

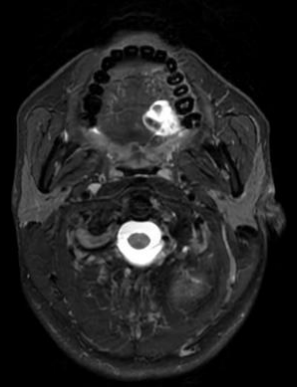

Water: Ax T2 FSE Flex

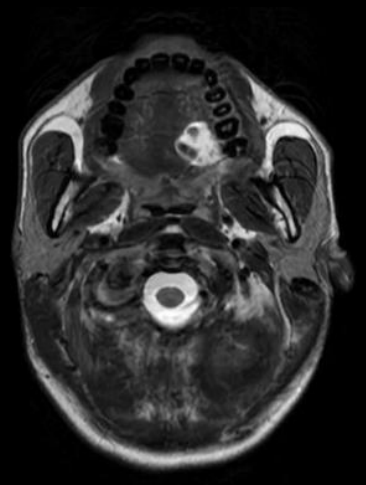

InPhase: Ax T2 FSE Flex

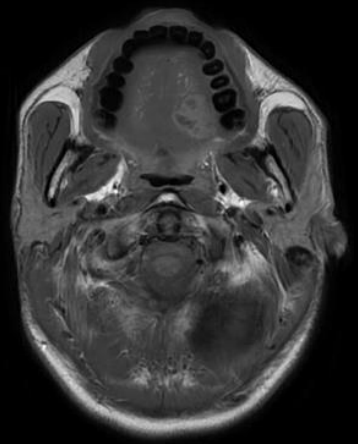

Ax T1 PROP

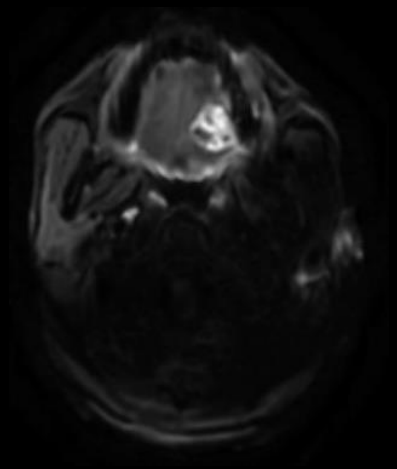

Ax MUSE DWI

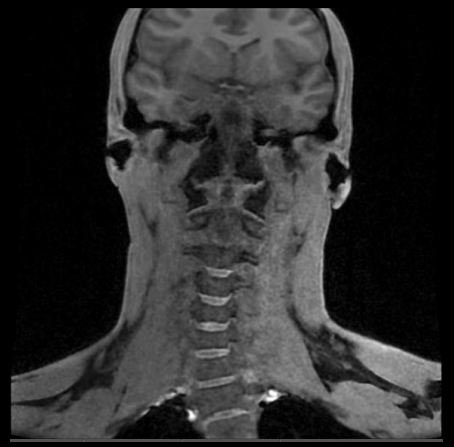

Water: Cor LAVA T1

Back to protocols

Neck (continued)

- Indication
  - Tumor, infection
- Sequences:
    - Cor T1 PROP
    - Sag T1 PROP
    - Ax DWI MUSE
    - Ax T1 PROP
    - Cor STIR PROP
    - Cor T1 +C
    - Ax T1 +C
  - Dixon method:
    - Ax T2 (Water + In-Phase)
    - Ax T1 (Water + In-Phase)
    - Cor T1 (Water)
    - Sag T1 +C (Water)
    - Ax T1 +C (Water + In-Phase)
    - Cor T1 +C (Water)

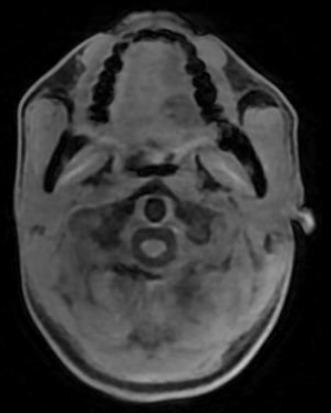

Water: Ax LAVA T1 FS

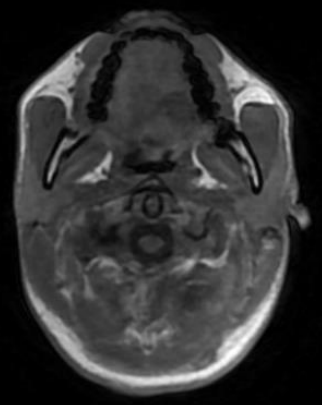

InPhase: Ax LAVA T1 FS

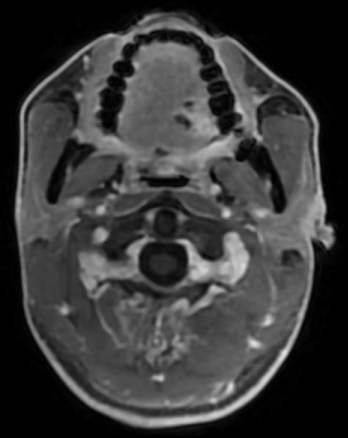

Water: Ax LAVA T1 FS C+

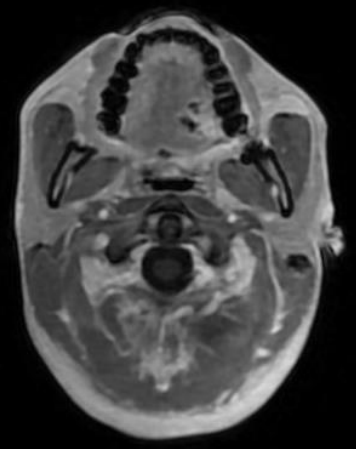

InPhase: Ax LAVA T1 FS C+

Water: Sag LAVA T1 FS C+

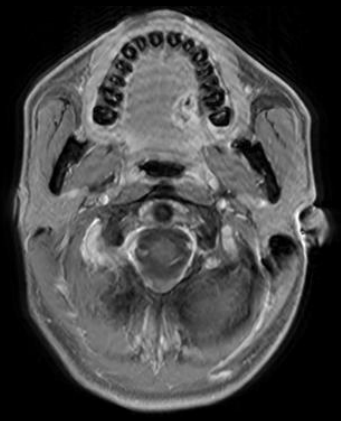

Ax T1 FS C+

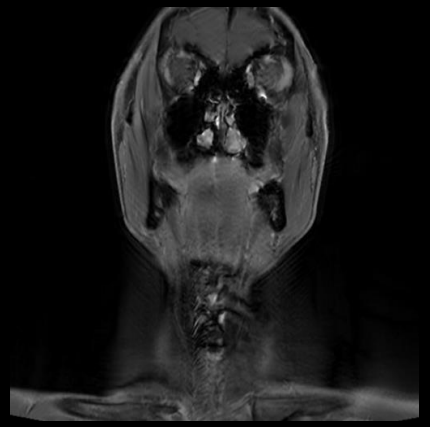

Cor T1 FS C+

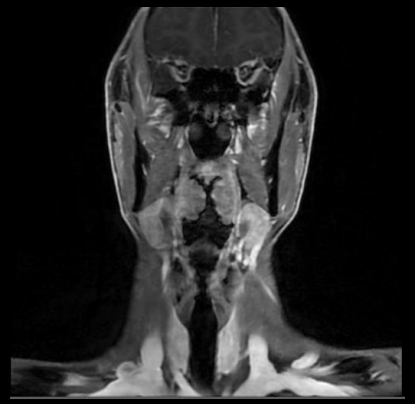

Water: Cor LAVA T1 FS c+

Back to protocols

Sella/Pituitary

- Indication
  - Pituitary dysfunction, Sellar or suprasellar mass
- Sequences
  - Whole Brain FOV
    - Ax DWI
    - AX T2 FSE
    - AX T1 SE +C
  - Small FOV
    - Sag T1
    - Cor T1 SE
    - Cor T2 FSE
    - Cor T1 +C
    - Sag T1 +C
  - Comments
    - If post-operative, small FOV contrast sequences need to be done with fat saturation

Ax T2 FSE

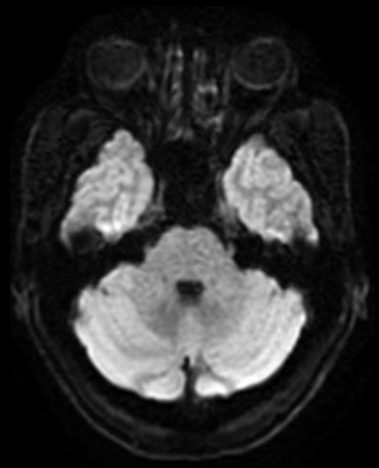

Ax T2 FSE

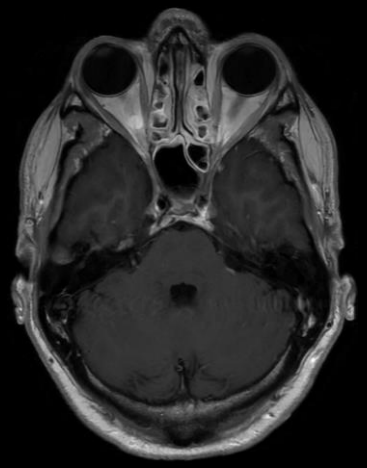

Ax T1 FLAIR C+

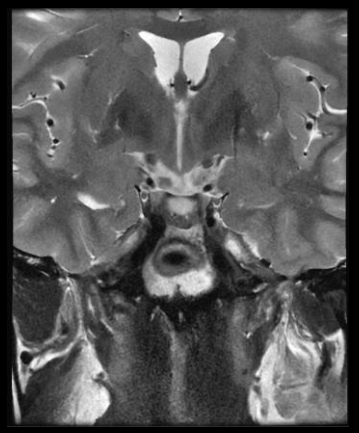

Cor T2 FSE

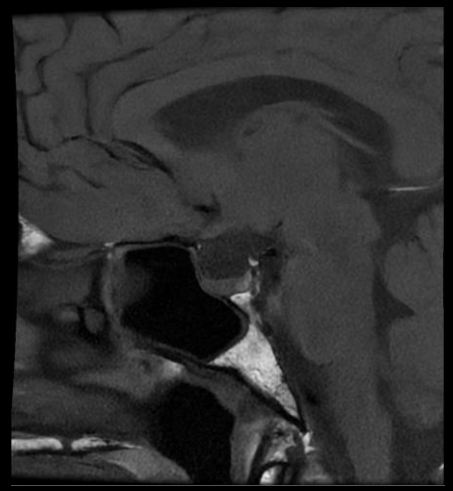

Sag T1 FSE

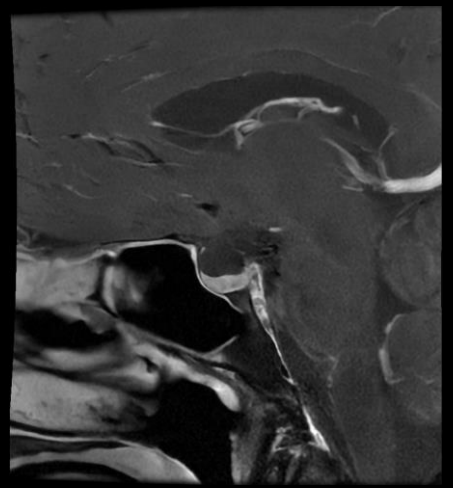

Sag T1 F SE FS C+

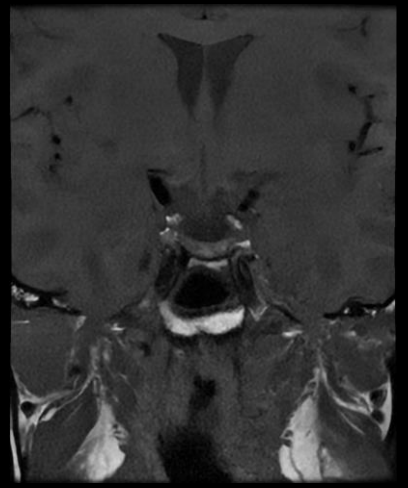

Cor T1 FSE

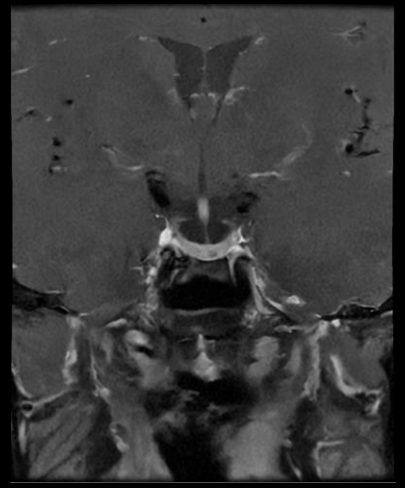

Cor T1 FSE FS C+

Back to protocols

Orbits – update*

- Indication
  - Orbit pathology, visual deficit
- Sequence
  - Sag T1
  - Ax T1 PROP
  - Cor T1 PROP
  - Ax DWI (whole brain)
  - Ax DWI MUSE
  - Cor STIR
  - T2 CUBE
  - Water: Cor T1 +C (FS)
  - Water: Ax T1 FLEX +C (FS)
- Optional:
  - Post Contrast Sag T1 Fat Sat along optic nerve (each side separate)
  - Add T2 FSE/ T2 FLAIR whole brain if visual field deficit/cranial nerve deficits
- FOV
  - FOV through orbits to include brainstem
  - Coronal perpendicular to optic nerves
  - Axial parallel to optic nerves

Sag T1 FSE

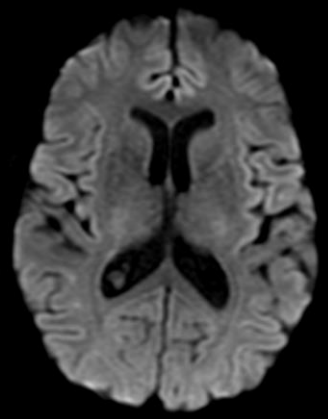

DWI

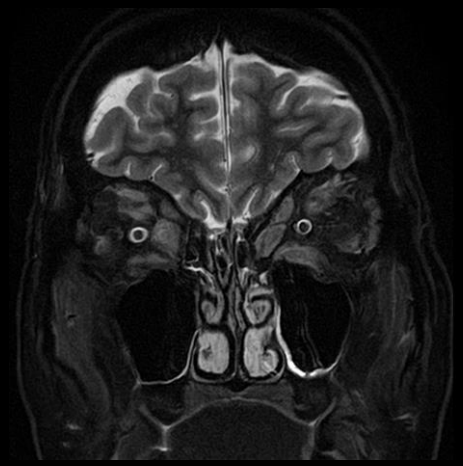

Cor T2 STIR

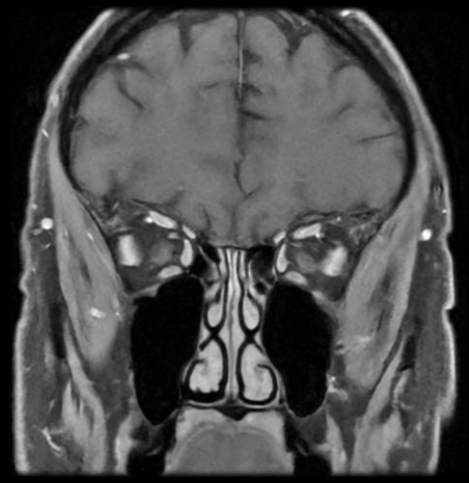

Water: Cor T1 +C (FS)

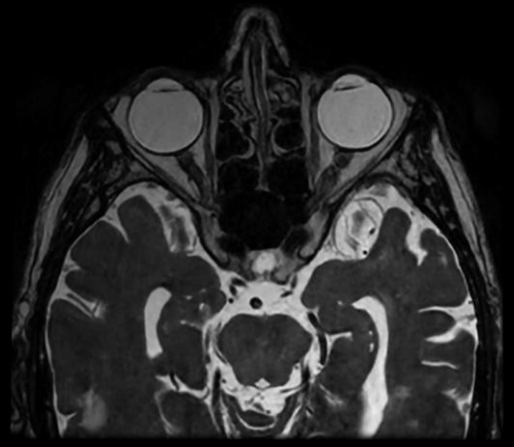

T2 CUBE

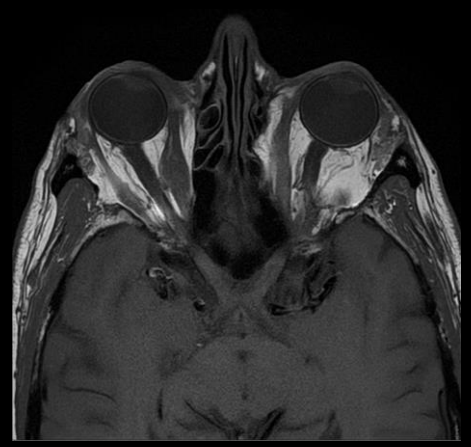

Ax T1 FS FSE

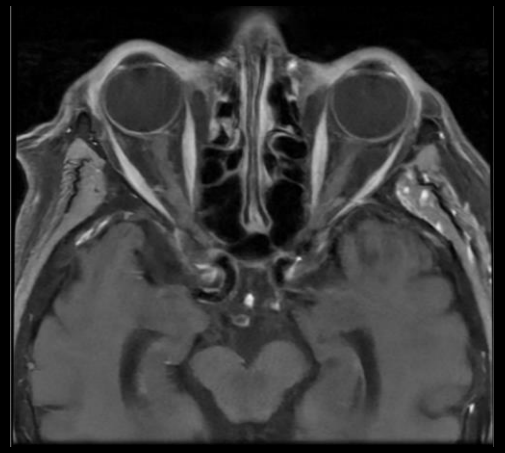

Water: Ax T1 FLEX +C

Back to protocols

IAC

- Indication:
  - Tinnitus, vertigo, hearing loss, CN6 or 7 palsy, 7th nerve palsy
  - Do NOT use for known schwannoma, sudden onset hearing loss, or presurgical evaluation (cochlear implant)
- Sequences
  - Whole Brain:
    - Ax DWI
    - Ax T1 FLAIR +C whole brain (no Fat Sat)
  - IAC
    - Sag T1
    - Ax DWI FSE PROP (non-echo planar DWI)
    - Cor T2
    - Ax T1
    - 3D T2 Cube or FIESTA
    - Ax T1 FS PROP +C
    - Cor T1 FS PROP +C
- Comments:
  - For cranial nerves extend slices anteriorly to posterior orbit & superiorly to 3rd ventricle

Sag T1 FSE

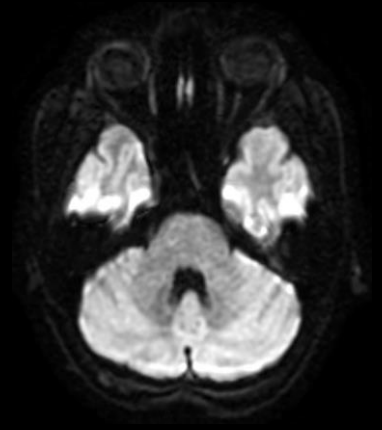

DWI

DWI PROP

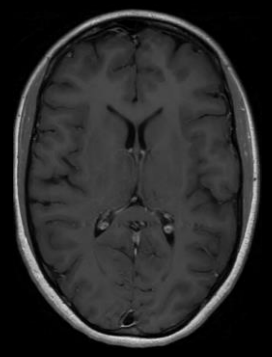

Ax T1 FSE C+

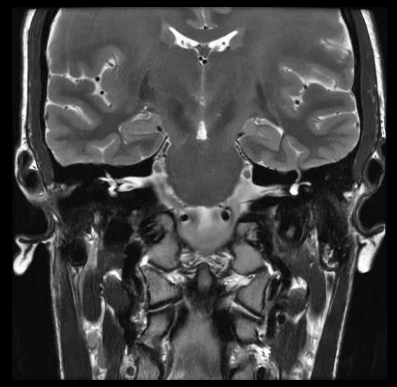

Cor T2 FSE

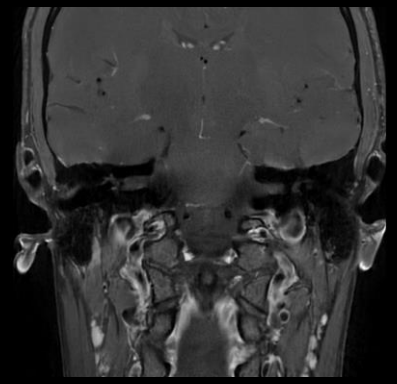

Cor T1 FS FSE C+

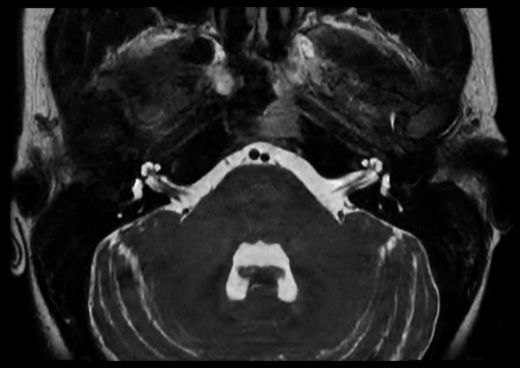

Ax FIESTA

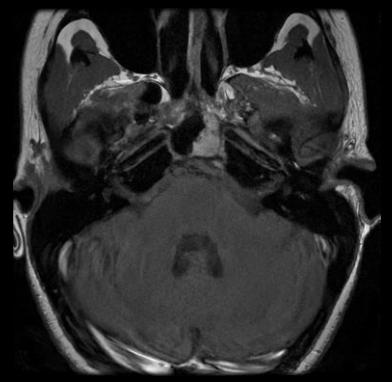

Ax T1 FSE

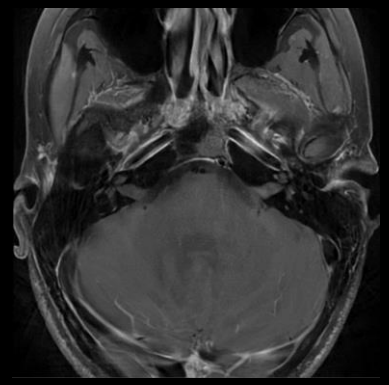

Ax T1 FS FSE C+

Back to protocols

Trigeminal

- Indication:
  - Trigeminal neuralgia
- Sequences
  - Ax 3D TOF MRA
  - Ax 3D T2 Cube or FIESTA
  - Ax 3D MP-RAGE +C

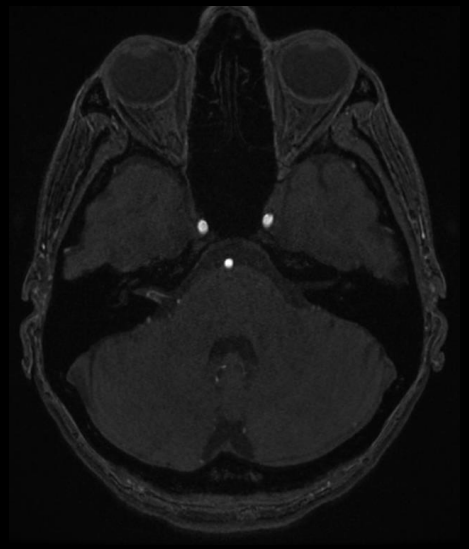

Ax 3D SPGR

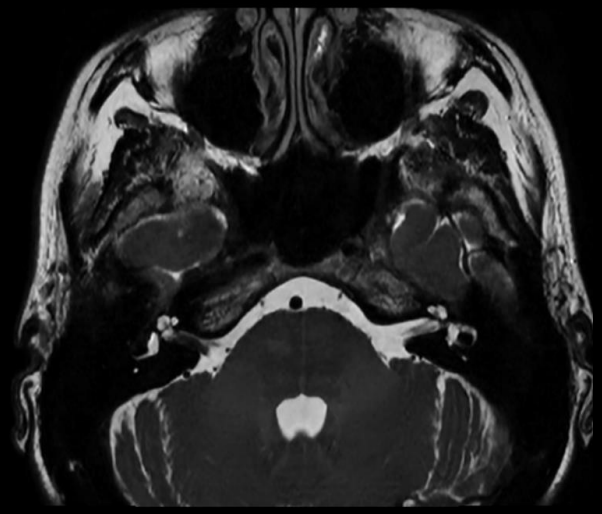

Ax 3D T2 Cube

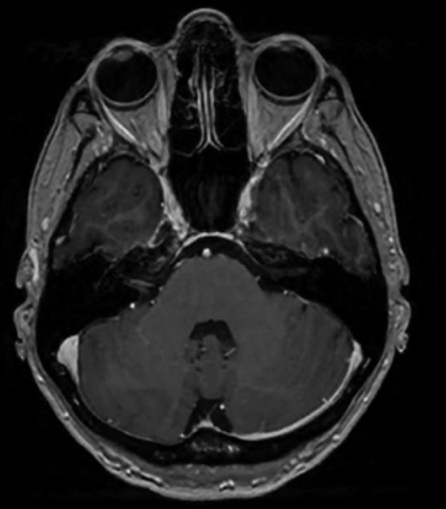

Ax 3D SPGR C+

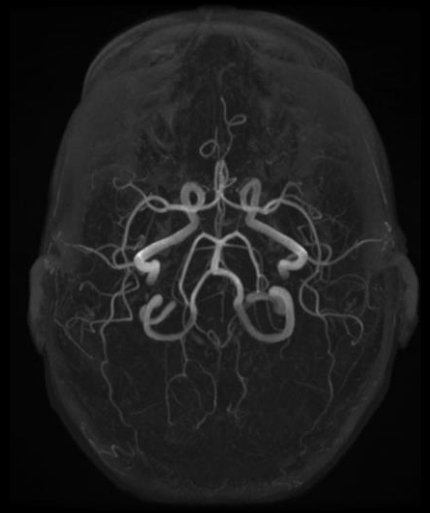

3D reconstructions

Back to protocols

Glossopharyngeal

- Indication:
  - Glossopharyngeal Neuralgia
- Coverage
  - Smaller FOV: coverage top of pons through C3, brain stem through all of face/mouth
- Sequences
  - Whole brain
    - Ax DWI
    - Ax T2 FLAIR
    - Ax T1 FS +C
  - Small FOV
    - Sag T1
    - Time of flight MRA (does not include full circle of Willis)
    - 3D T2 Cube or FIESTA Cor post contrast fat saturated
    - Cor T1 FS +
    - T1 MP-RAGE C+

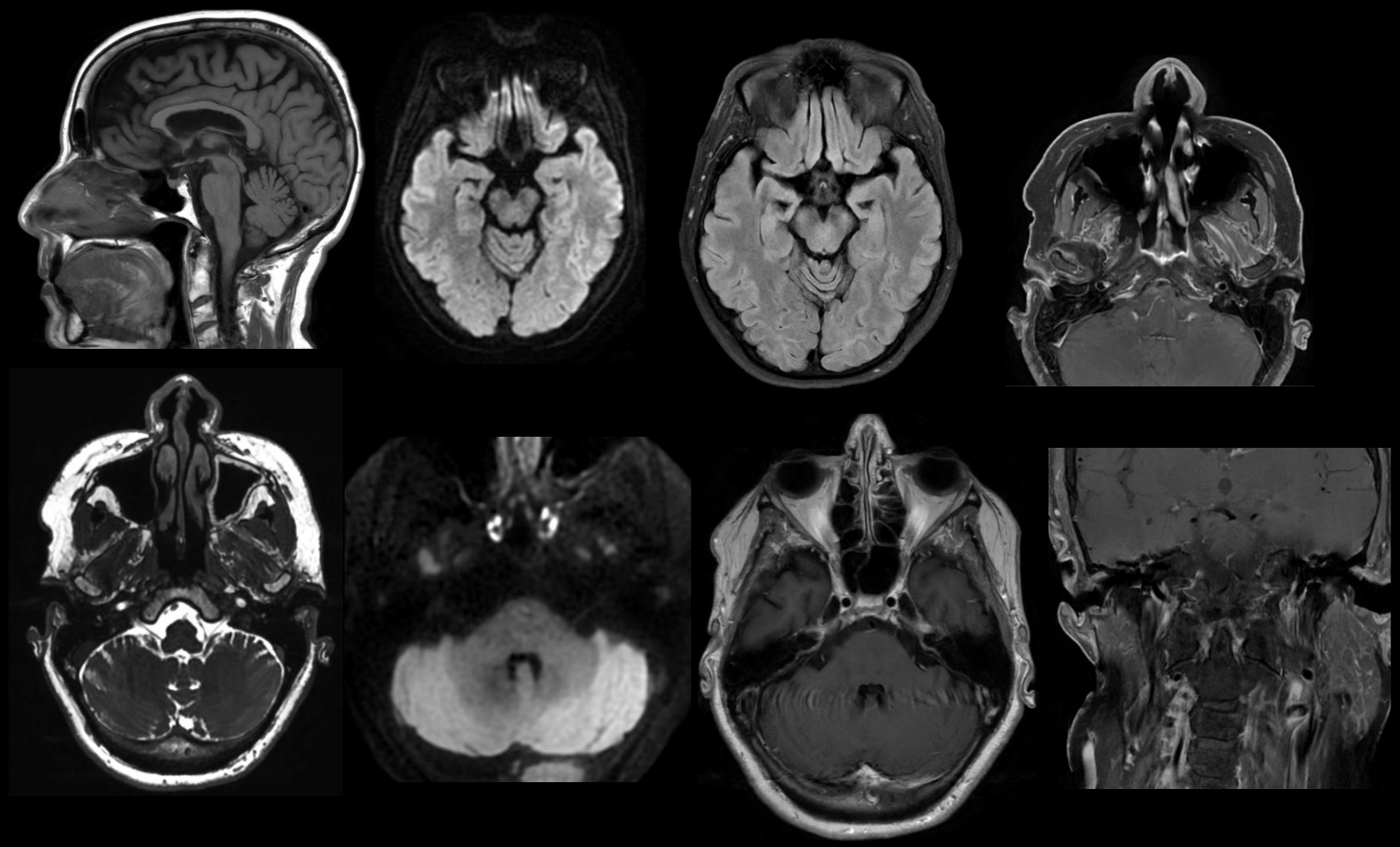

Back to protocols

Vascular

MRI NEURO

Protocol	Brain	MR Angiogram	Head and Neck	Spine	Show All
MR Angiogram	Head MRA W/O	Head MRA +C	Custom MRA	VWI Head MRA W/O	
--	Head MRV W/O	Head MRV +C			
--	Neck MRA W/O	Neck MRA +C	Spine MRA		

Back to protocols

Head MRA

- Non-contrast is sufficient for intracranial aneurysm screening and LVO detection (eg, time of flight and phase-contrast techniques)
- Contrast useful for more accurate vessel lumen assessment (especially in the neck) for high-grade carotid stenosis, dissections, and aortic arch pathology, and can also be useful to characterize treated/coiled aneurysms to looks for residual filling
- Sequences:
  - Ax 3D TOF FSPGR
  - SAG 3D Inhance Pre
  - +/- Ax 3D TOF C+ FSPGR

Ax 3D TOF

Ax 3D TOF C+

Back to protocols

Head MRV

- For venous sinus thrombosis, contrast-enhanced is **strongly** preferred (push for this).
- Pregnant patients cannot receive contrast
- Sequences:
  - SAG 3D Inhance Pre
  - Cor 2DTOF SPGR
  - Sag 2DTOF SPGR (slight oblique angle)
  - Cor 3DTOF FSPGR +C

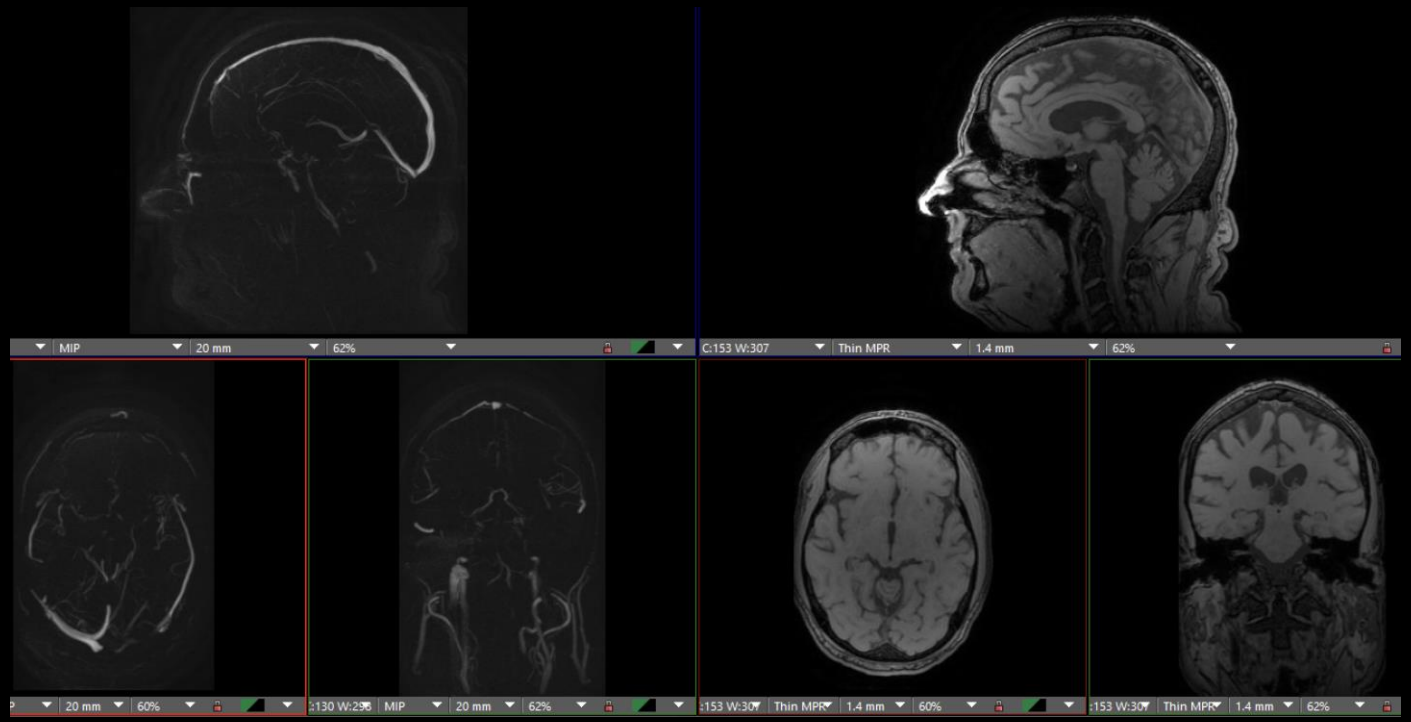

3D Sag Inhance Pre

3D Baseline

Cor 2D TOF

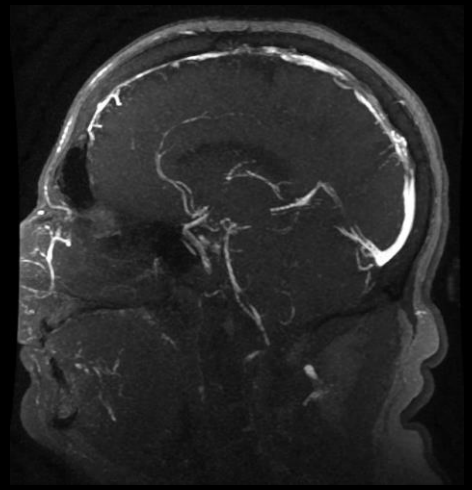

Sag 2D TOF

3D C+

Back to protocols

Neck MRA

- Non-contrast is sufficient for intracranial aneurysm screening and vessel occlusion (eg, time of flight and phase-contrast techniques)
- Contrast useful for more accurate vessel lumen assessment (especially in the neck) for high-grade carotid stenosis, dissections, and aortic arch pathology, and can also be useful to characterize treated/coiled aneurysms to looks for residual filling
- FOV:
  - Aortic arch to circle of Willis
- Sequences:
  - Standard
    - InHance
    - Ax 3D TOF SPGR
    - Cor 3D TOF FSPGR+C
  - For Dissection/Trauma:
    - AX T1 FS GATED BLACK BLOOD through skull base

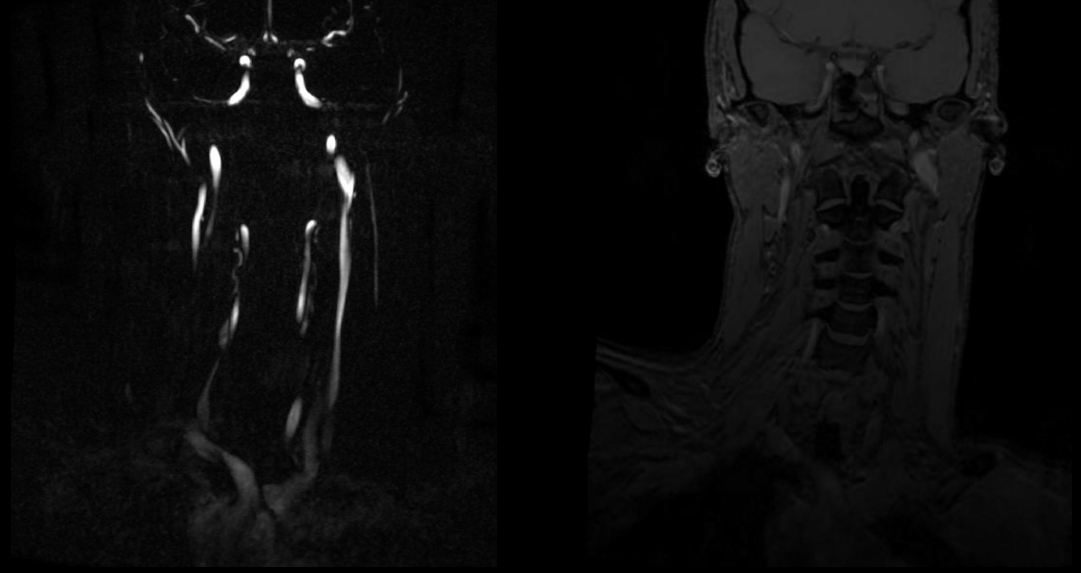

Cor 3D Inhance (subtracted vs background)

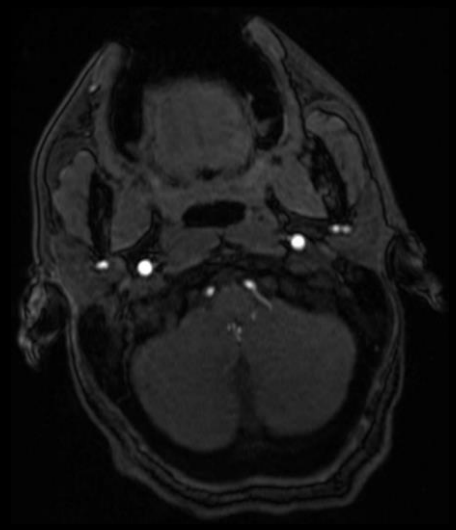

Ax 3D TOF

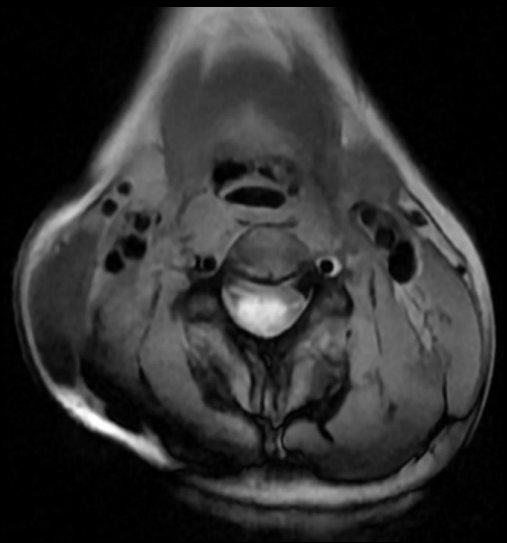

Black Blood T1 FS or MDSE

Back to protocols

Spine MRA

- Indication:
  - Spinal arteriovenous shunt lesions
- Sequences:
  - Sag TRICKS +C (mask)
  - Subtraction images/phases

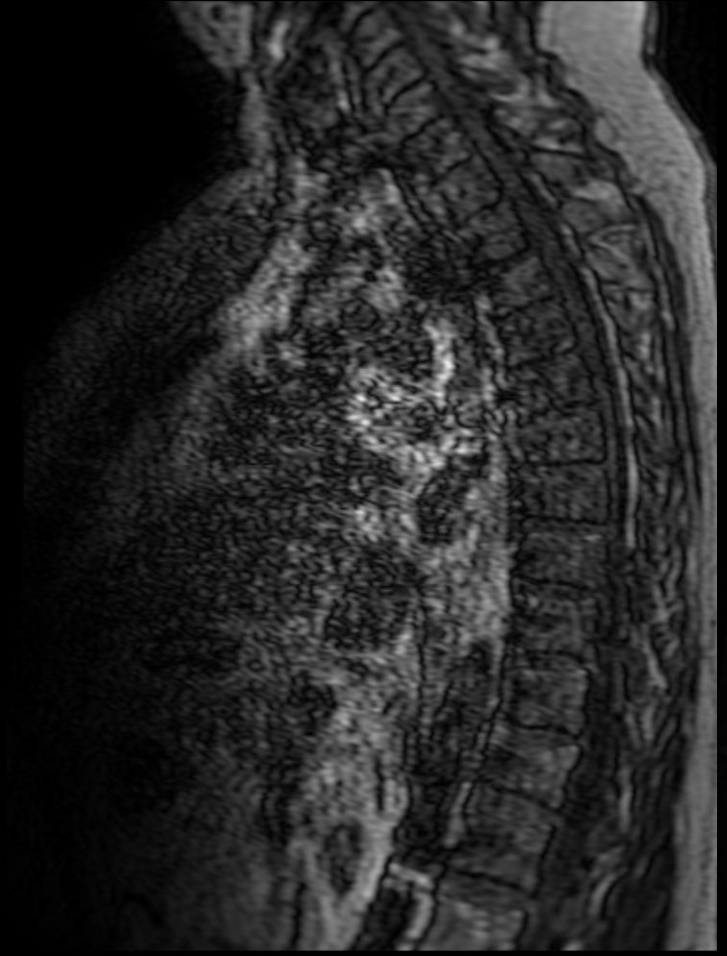

Sag TRICKS (mask)

SUB:Sag TRICKS (composite)

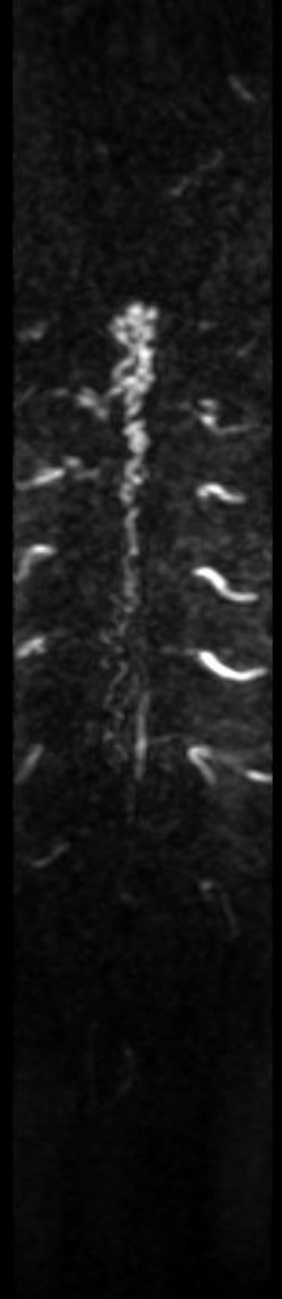

Subtraction coronal MPR

Back to protocols

Back to home

Spine

MRI NEURO

Protocol	Brain, MR Angiogram, Head and Neck, Spine, Show All
Spine MRI	C-Spine W/O, C-Spine + C, C-Spine Trauma, C-Spine CCJ, C-Spine MS W/O, C-Spine MS + C
--	T-Spine W/O, T-Spine +C, T-Spine Trauma, T-Spine MS W/O, T-Spine MS +C
--	L-Spine W/O, L-Spine +C, L-Spine Trauma, Spine Survey

Back to protocols

C-Spine WO

- Indication:
  - Disc disease, degenerative, pain, radiculopathy, including post-op
- Sequences:
  - Standard
    - Sag T2 FSE
    - Sag T1 FSE
    - Sag STIR
    - Ax T2 FSE
    - Ax MERGE
  - Optional
    - Cor T1 FSE
    - Cor T2 FSE
- Comments
  - Axial imaging from C2 to top of T1
  - For scoliosis and tethered cord add coronal

Sag T1 TSE

Sag T2 FSE

Sag T2 STIR

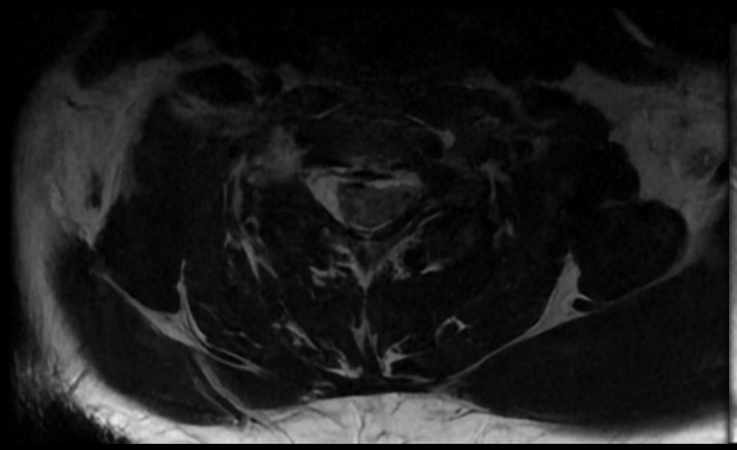

Ax T2 FSE

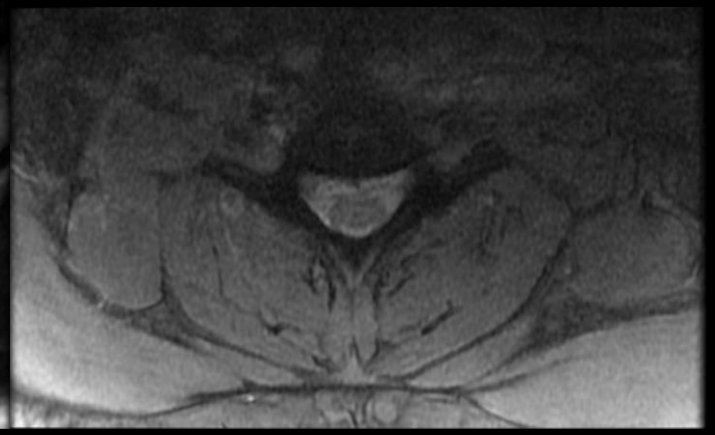

3D Ax <MERGE

Back to protocols

C-Spine CCJ
(craniocervical junction)

- Indication:
  - Trauma, craniocervical ligament evaluation
- Coverage:
  - Axials go to sphenoid sinus to T1-T2 (higher than standard C-spine WO)
- Sequences:
  - C-Spine Trauma WO PLUS
    - Sag 3D T2 Cube
    - Cor STIR
    - Cor PD
  - Small FOV centered at C1-2
    - 3D PD Cube
    - Cor STIR

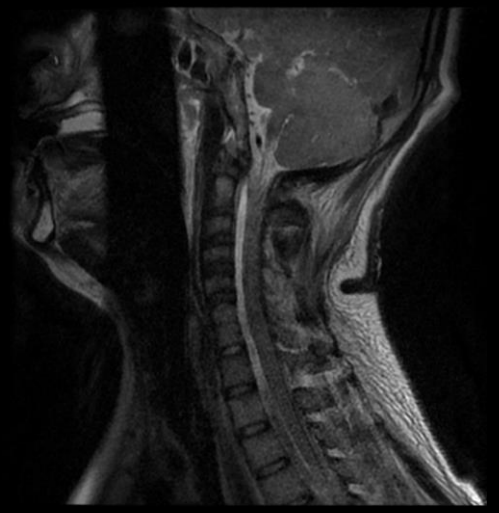

Sag T2 CUBE

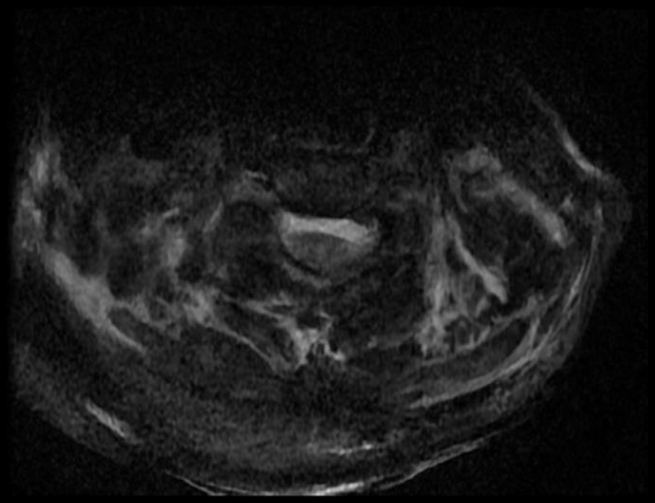

Ax T2 FSE FS

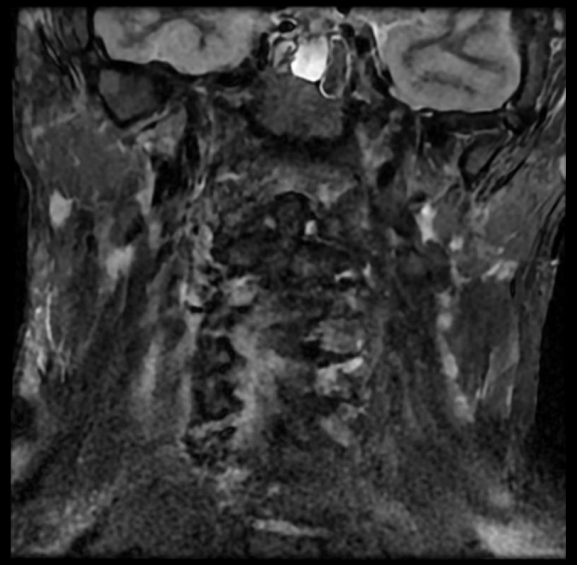

Cor T2 STIR

3D PD cube

Back to protocols

C-Spine CCJ
(craniocervical junction)

Partial tear of the left alar ligament
and apical ligament

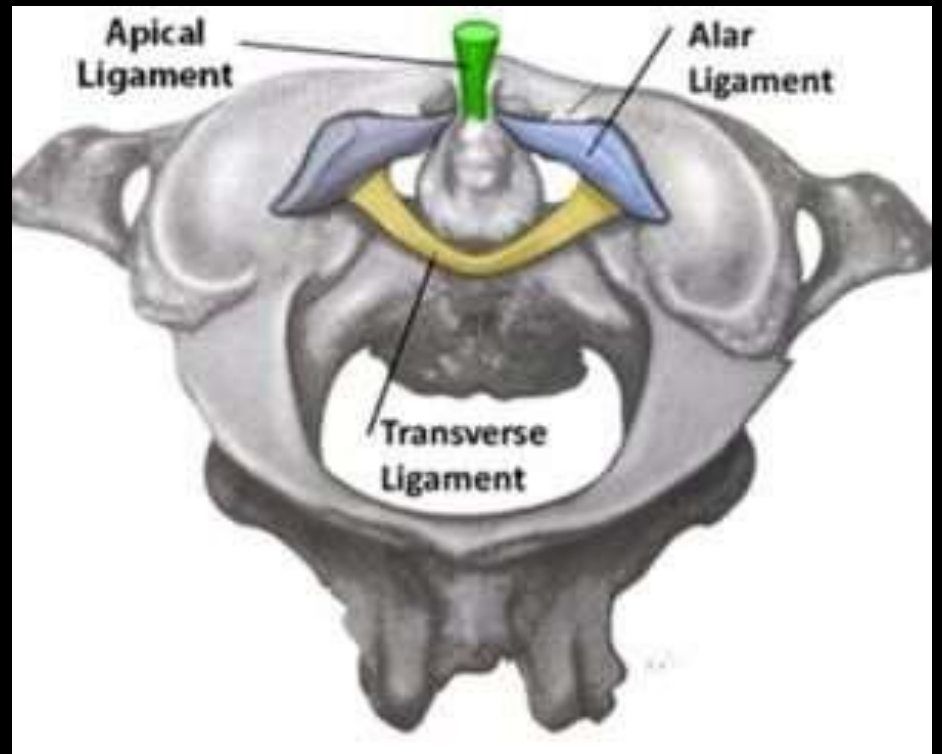

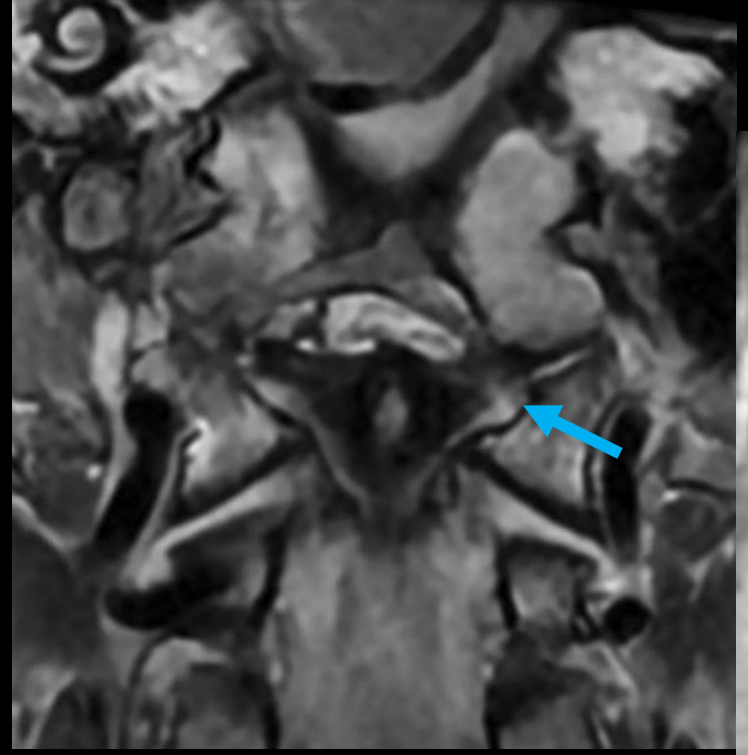

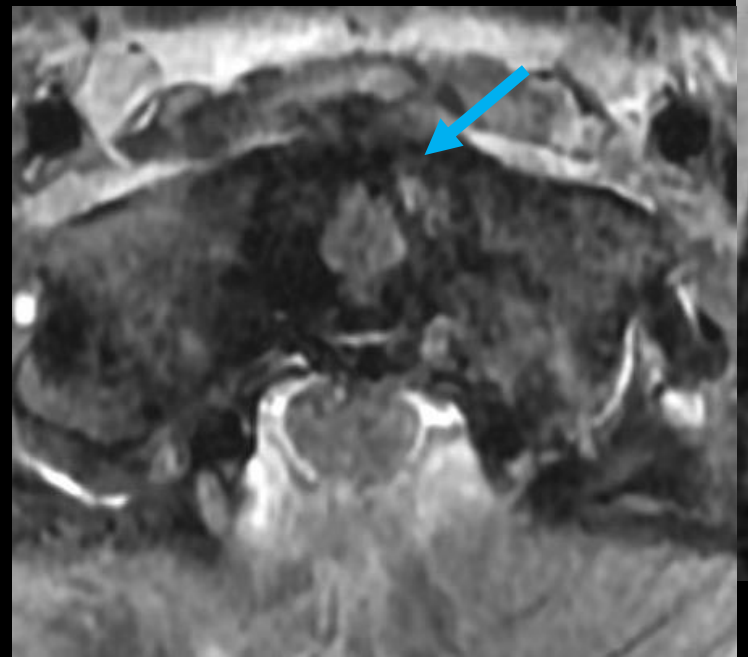

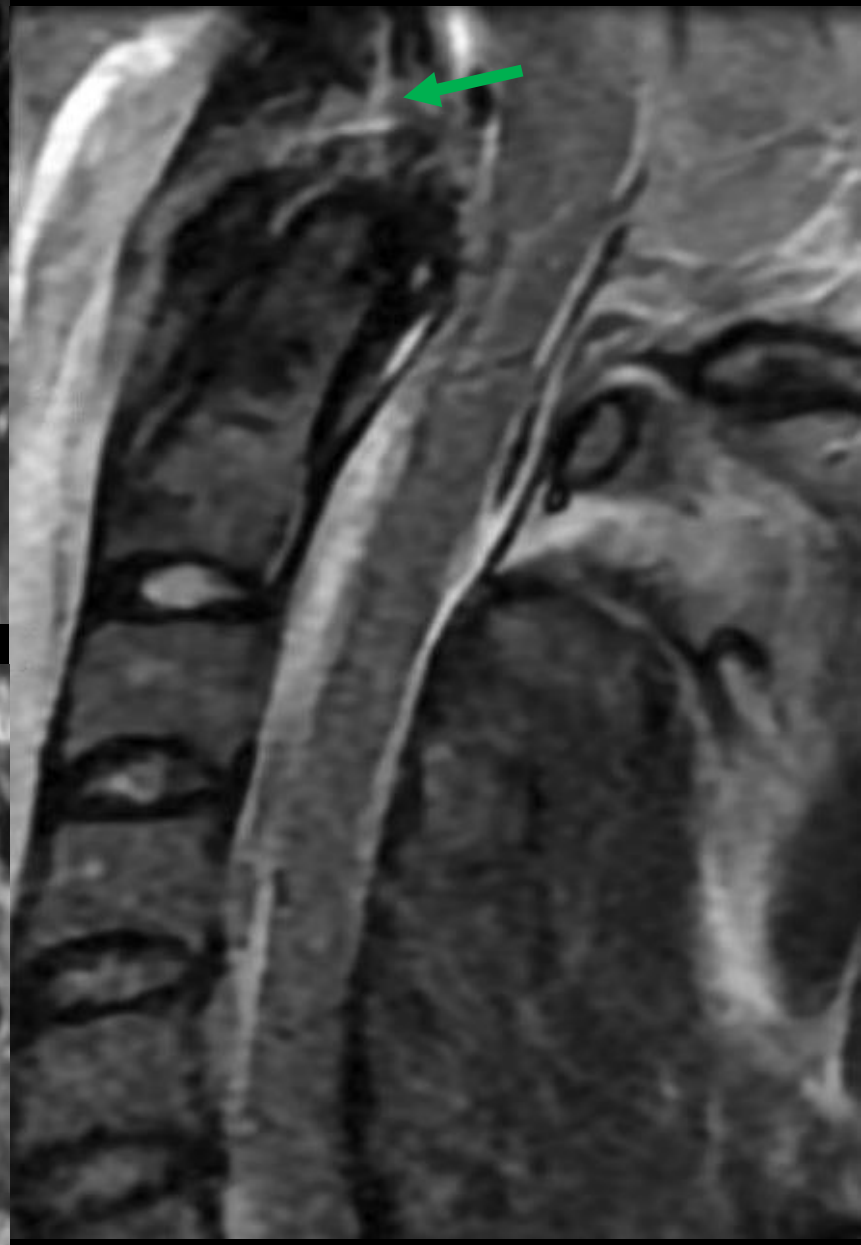

C-Spine W

- Notes:
  - Indications: Tumor, Infection, Syrinx
- Sequences:
  - For post-contrast, some scanners utilize FLEX (Dixon), others FSE
  - C-Spine WO PLUS
    - Sag T1 FS + C
    - Axial T1 FS +C
    - If post fat saturation is suboptimal, repeat sequences non fs.
- Optional
  - For scoliosis, tethered cord and Neurofibromatosis, add coronal
  - If there is concern for syrinx, add 1-mm 3D sagittal FIESTA through the spinal cord.

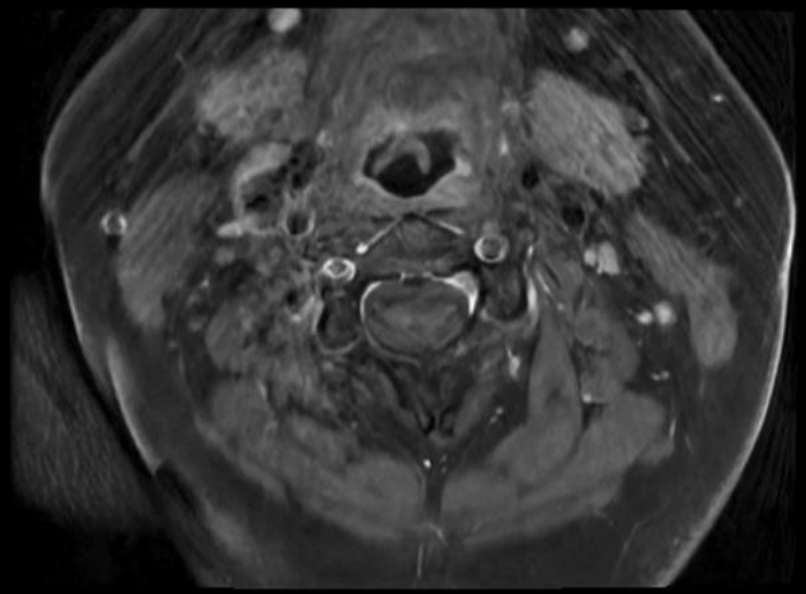

Water: Ax T1 FS FLEX +C

Water: Sag T1 FS FLEX +C

Back to protocols

C-Spine MS (WO or WO/W)

- All scanners utilize FSE (not FLEX)
  - T1 and T2 FSE sequences maintain more consistent T1 and T2 contrast ensuring optimal cord-to-lesion contrast, and because they are not influenced by FLEX artifacts (Dixon fat-water separation processing), which could mimic or obscure MS plaques.
  - Maintains consistency with prior studies, which is important for accurately assessing new vs. chronic lesions.

- Sequences:
  - C-Spine WO PLUS
    - Sag PD
    - Sag T1 +C (no Fat Sat)
    - Axial T1 +C (no Fat Sat)

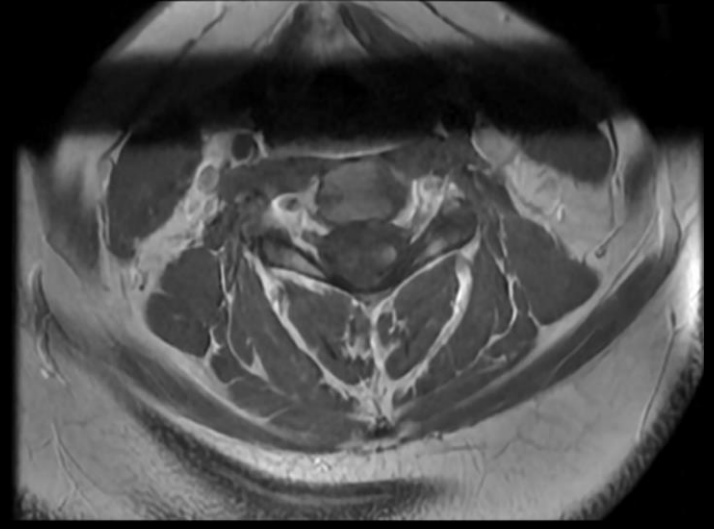

Sag T1 PD

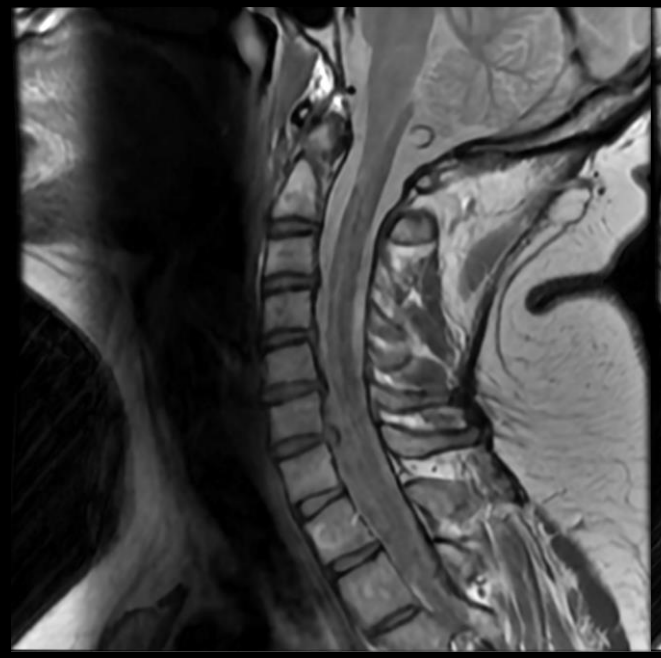

Ax NOFS T1 C+

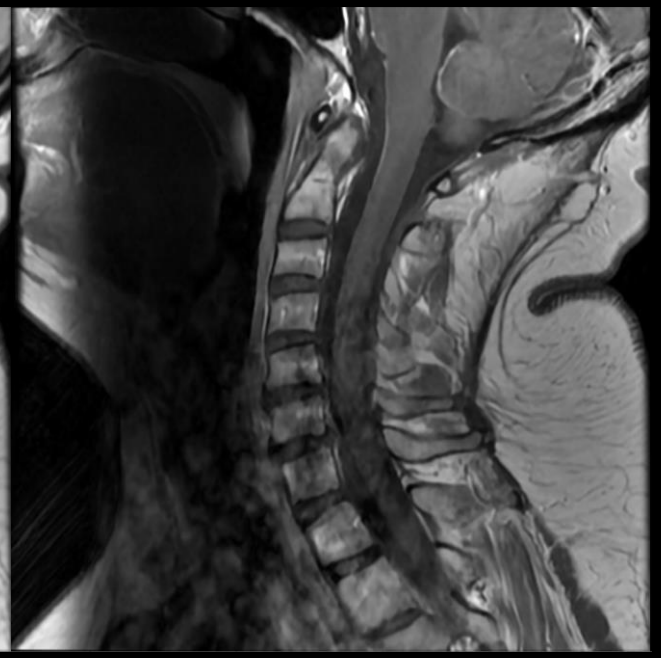

Sag NOFS T1 C+

Back to protocols

T-Spine WO

- Indication:
  - Disc disease, pain, radiculopathy
- FOV
  - Axial coverage through ROI
  - Angle sagittals to spine, if scoliosis, do upper and lower angels.
- Sequences:
  - Standard
    - Sag T1 FSE counter
    - Sag T1 FSE or FLAIR
    - Sag T2 FSE
    - Sag STIR
    - Ax MERGE
    - Ax T2 FSE
  - Optional
    - Cor T1 FSE
    - Cor T2 FSE
    - For scoliosis and tethered cord, add coronal

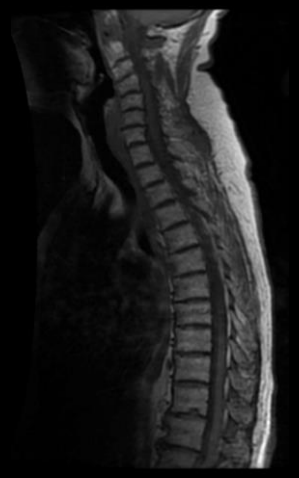

Sag T1 counter

Sag T1 FLAIR

Sag T2

Sag STIR

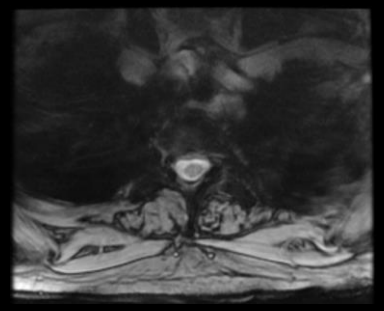

Ax 2D MERGE upper

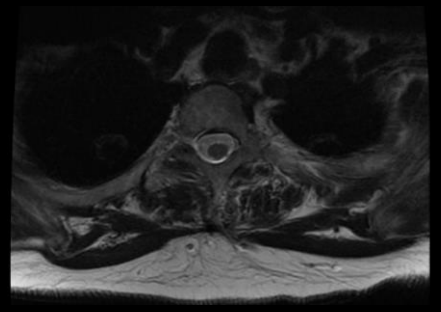

Ax T2 FSE upper

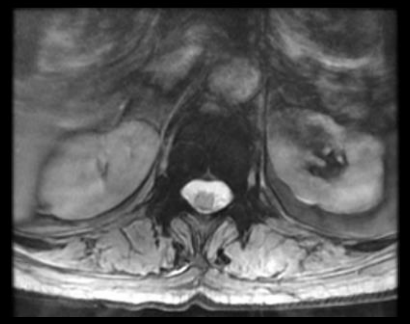

Ax 2D MERGE lower

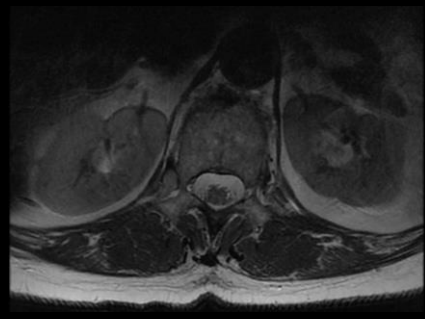

Ax T2 FSE lower

Back to protocols

T-Spine Trauma

- Indication:
  - Trauma
  - Acute thoracic or lumbar spine injury detected on radiographs or noncontrast CT. Neurologic abnormalities.
- Sequences:
  - T-Spine WO
    - Sag T1 FSE
    - Sag T2 FSE
    - Sag STIR
    - Sag GRE
    - Sag T2 CUBE
    - Ax T2 FSE FS, upper and lower
  - Optional
    - Ax GRE
    - Cor T1 FSE
  - Axial coverage through ROI
  - For scoliosis and tethered cord add coronal
  - Angle sagittals to spine, if scoliosis, do upper and lower angels.

Sag counter

Sag T2 FSE

Sag T1 FSE

Sag STIR

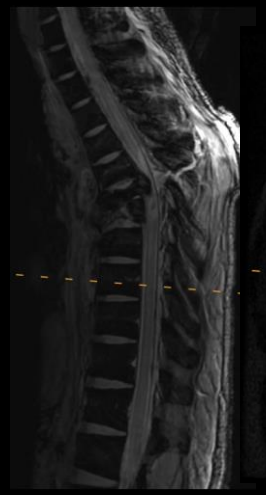

Sag GRE

Sag T2 CUBE

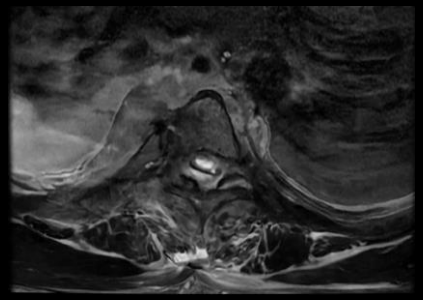

Ax T2 FSE FS upper

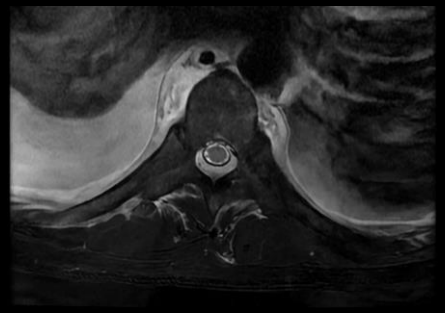

Ax T2 FSE FS lower

Back to protocols

T-Spine WO/W

- Indication:
  - Tumor, Infection, Syrinx
- Sequences:
  - T-Spine WO PLUS
    - Sag T1 +C FSE FS
    - Ax T1 +C FSE FS
    - If Fat Sat fails, do non Fat Sat post contrast
- Optional
  - Cor T1 FSE
  - Cor T2 FSE
  - For neurofibromatosis, add coronal T2

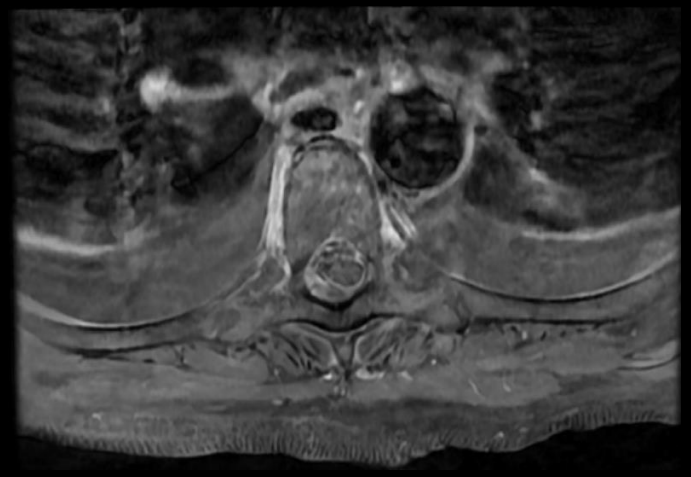

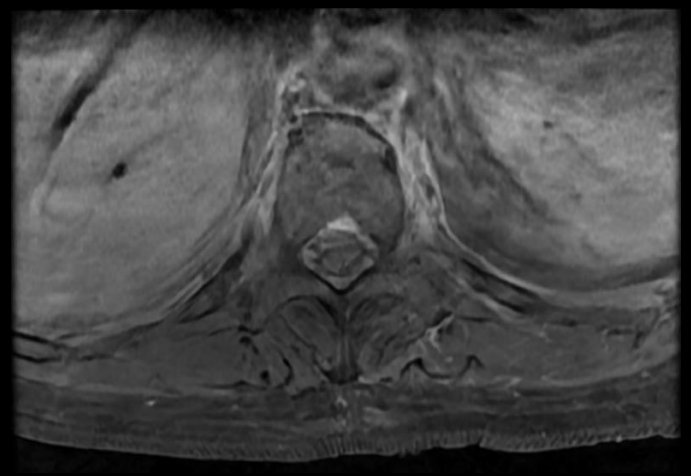

Back to protocols

T-Spine MS

- Indication:
  - MS
- Sequences:
  - Sag STIR
  - Sag PD
  - Sag T2 FSE
  - Sag T1 FS
  - Ax MERGE
  - Ax T2 FSE
  - Sag T1 +C (no Fat Sat)
  - Axial T1 +C (no Fat Sat)
- Angle sagittals to spine, if scoliosis, do upper and lower angels.

Sag T2 count | Sag T2 | Sag T1 | Sag PD | Sag STIR | Sag T1 No FS C+

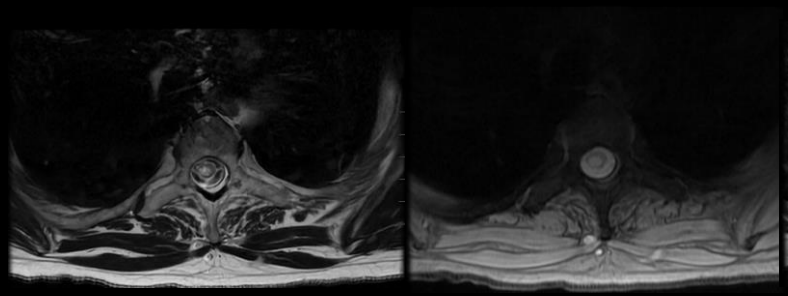

Ax T2 FSE upper | Ax MERGE upper

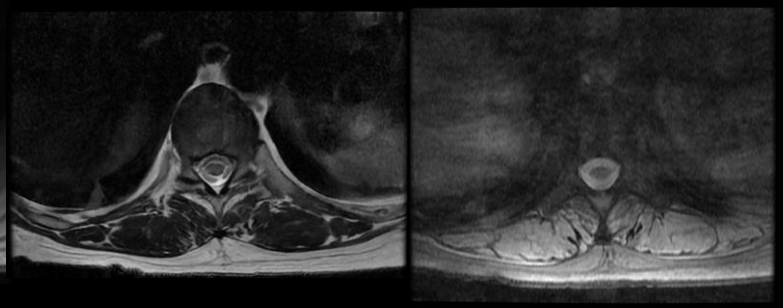

Ax T2 FSE lower | Ax MERGE lower

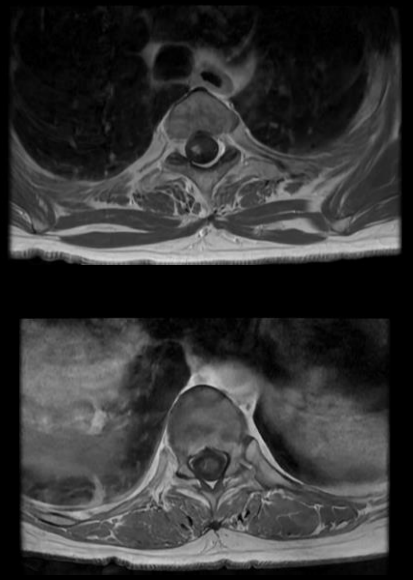

Ax T1 upper and lower

Back to protocols

L-Spine WO

- Indication:
  - Disc disease, pain, radiculopathy
- Sequences:
  - Standard
    - Sag T1 FSE
    - Sag T2 FSE
    - Sag STIR
    - Ax T2 FSE
    - Ax T1 FSE
  - Optional (eg, scoliosis, tethered cord)
    - Cor T1 FSE
    - Cor T2 FSE

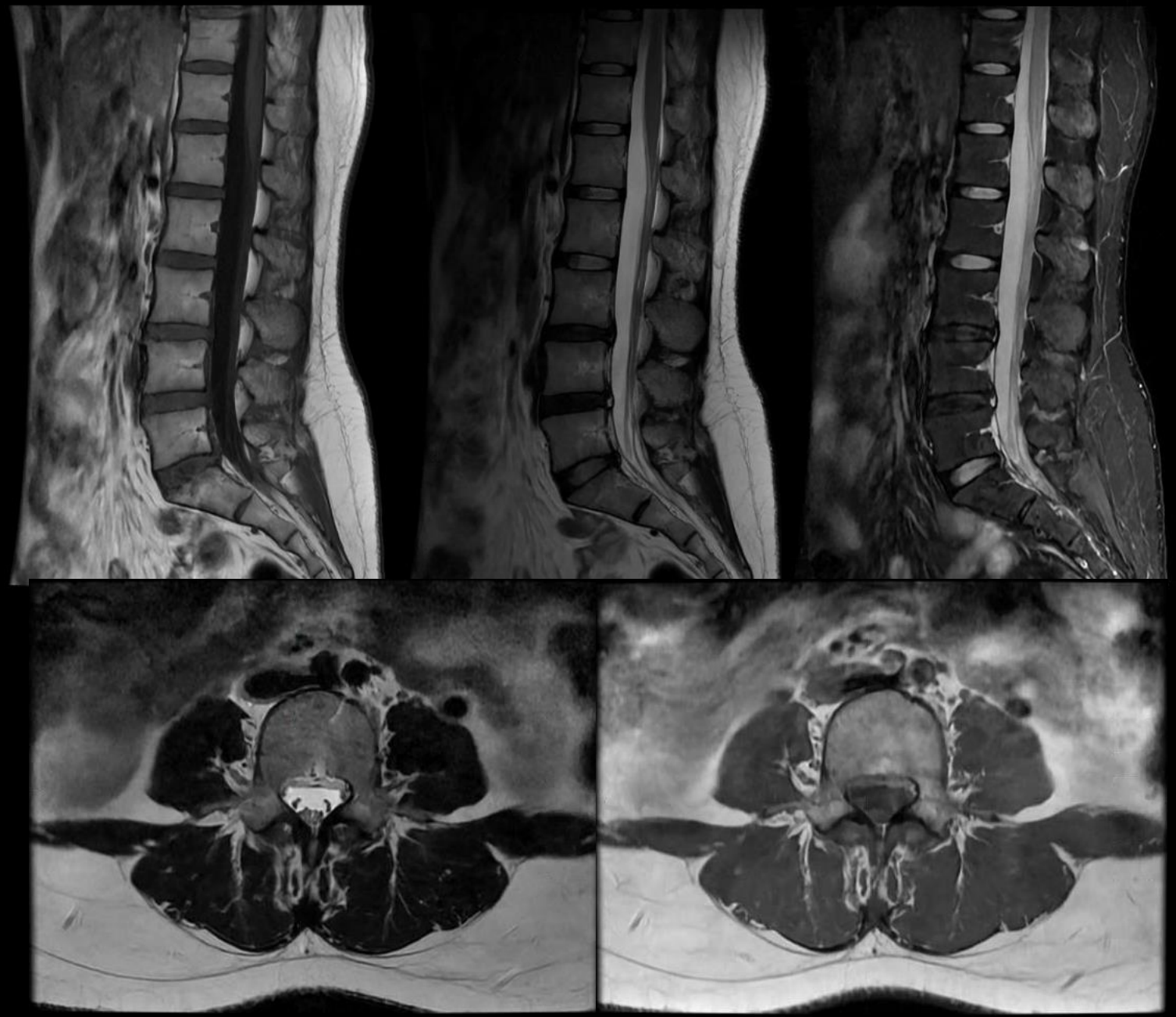

Back to protocols

L-Spine Trauma

- Indication:
  - Trauma
  - Acute thoracic or lumbar spine injury detected on radiographs or noncontrast CT. Neurologic abnormalities.
- Sequences:
  - Lumbar Spine WO PLUS
    - Sag GRE
    - Ax T2 FSE FS (in place of non-FS)
  - Optional
    - Cor T1 FSE
    - Cor T2 FSE

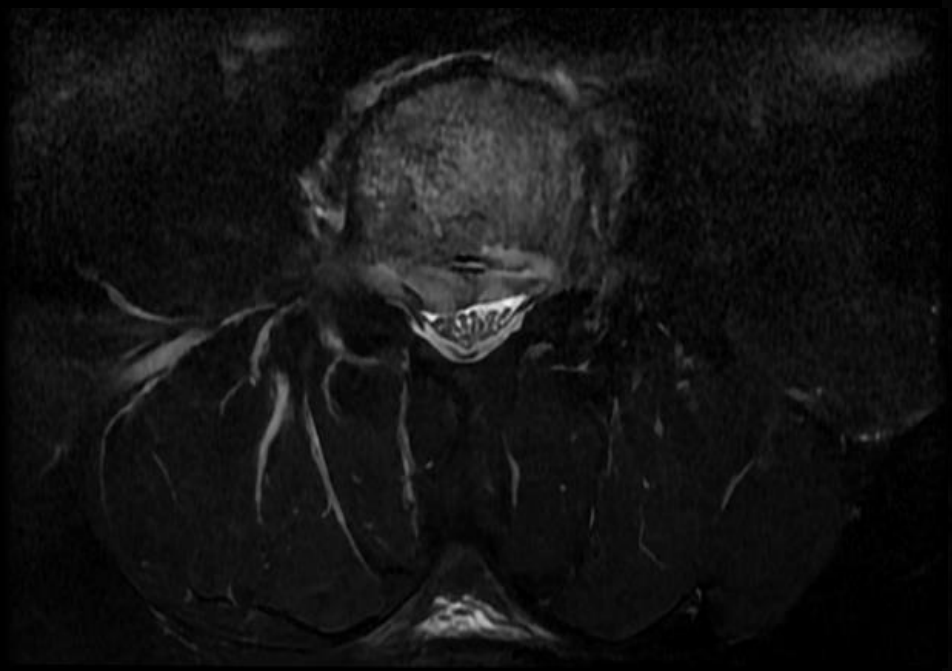

Back to protocols

L-Spine C+

- Indication:
  - Tumor, post-operative, infection
- Sequences:
  - L-Spine WO PLUS:
    - Sag T1 +C FSE FS
    - Axial T1 FS +C
  - Optional
    - Cor T1 FSE
    - Cor T2 FSE
  - If metal hardware in spine, obtain the post contrast without fat sat
  - For neurofibromatosis add coronal T2

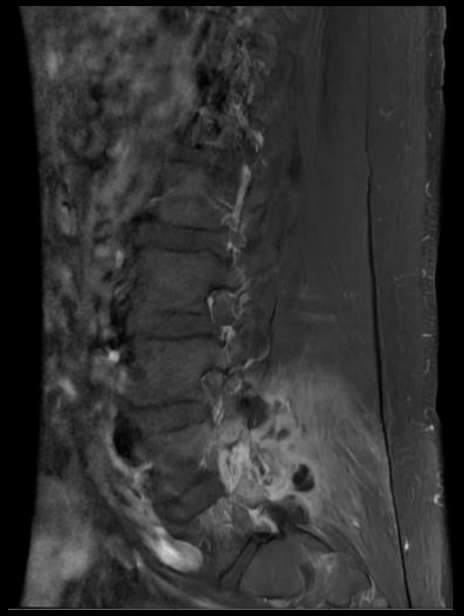

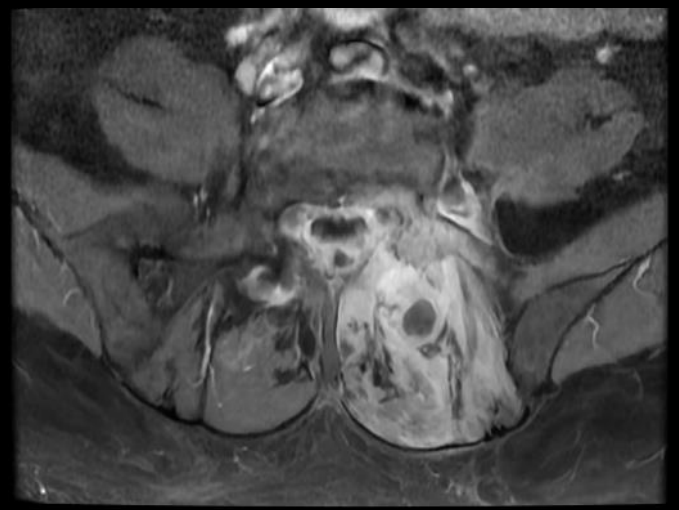

Back to protocols

Spine Survey

- Indication:
  - DO NOT USE FOR MS OR TRANSVERSE MYELITIS
  - Metastases
  - Non-localized infection
  - Acute myelopathy / cord compression
  - See next slide for additional details
- FOV
  - 2 sets of sagittal images, upper (cervicothoracic) and lower (thoracolumbar)
- Sequences:
  - Water: Sag T2 FLEX
  - InPhase: Sag T2 FLEX
  - Sag T1 PROP
  - Water: +C Sag T1 FLEX
  - InPhase: +C Sag T1 FLEX
  - C+ Ax 3D LAVA (upper, thoracolumbar, lower)
- Comments
  - For scoliosis, tethered cord or neurofibromatosis, add coronal
  - Post-contrast images in patient with spinal hardware need to be done non-fat suppressed, and have axial T1 pre-contrast for comparison

Water: Sag T2 FLEX

InPhase: Sag T2 FLEX

Sag T1 PROP

Water: +C Sag T1 FLEX

InPhase: +C Sag T1 FLEX

Water: Sag T2 FLEX

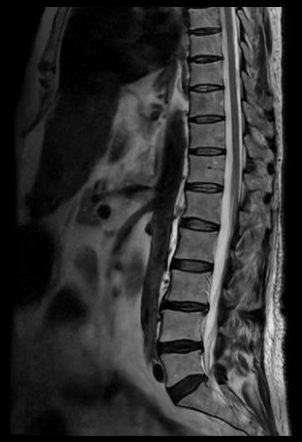
InPhase: Sag T2 FLEX

Sag T1 PROP

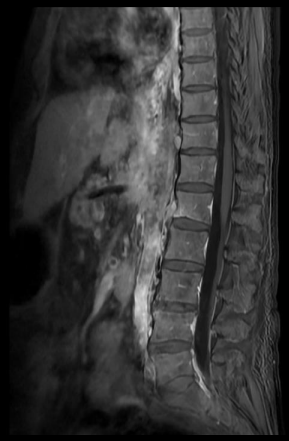
Water: +C Sag T1 FLEX

InPhase: +C Sag T1 FLEX

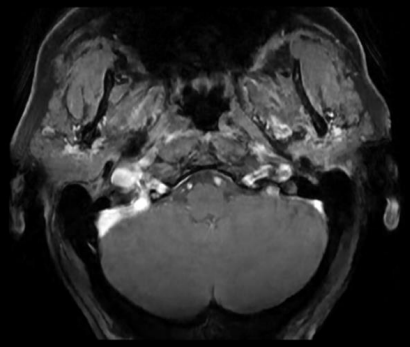
C+ Ax 3D LAVA Upper

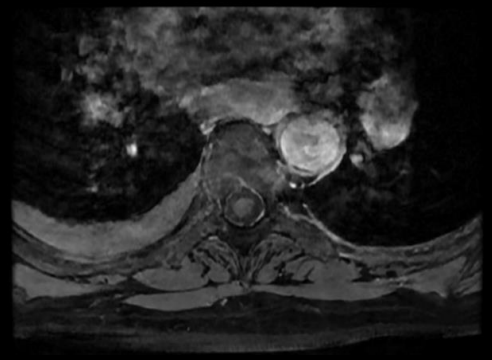
C+ Ax 3D LAVA Thoracolumbar

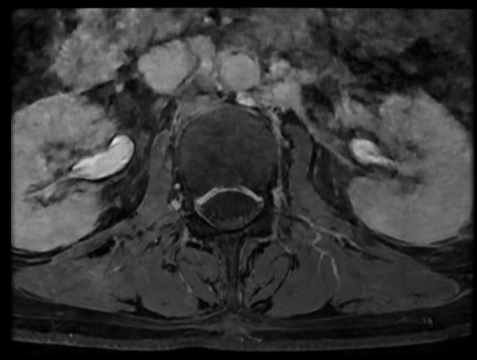
C+ Ax 3D LAVA Lower

Back to protocols

Spine Survey

- Advantages:
  - Faster
  - Patients tolerate the exam
  - Not tailored for the evaluation of degenerative changes

- Disadvantages:
  - Larger FOV decreases lesions conspicuity
  - Lack of axial T2 – limited evaluation of nerve roots
  - Not tailored for the evaluation of degenerative changes
  - Surgical or radiation planning may require dedicated exam of spine segment

Water: +C Sag T1 FLEX

C+ Ax 3D LAVA

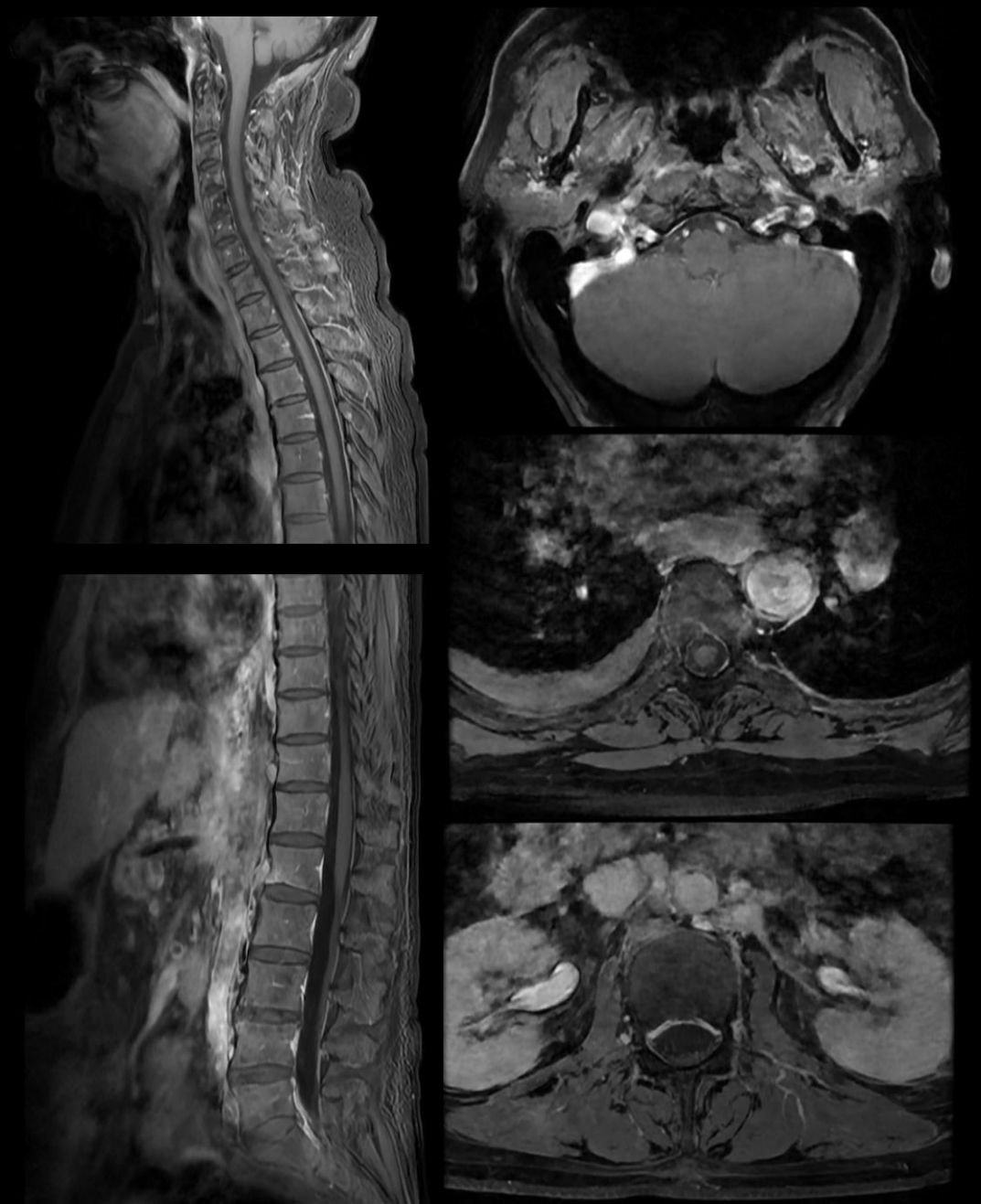

Back to protocols

Cases

Table of contents

Case 1

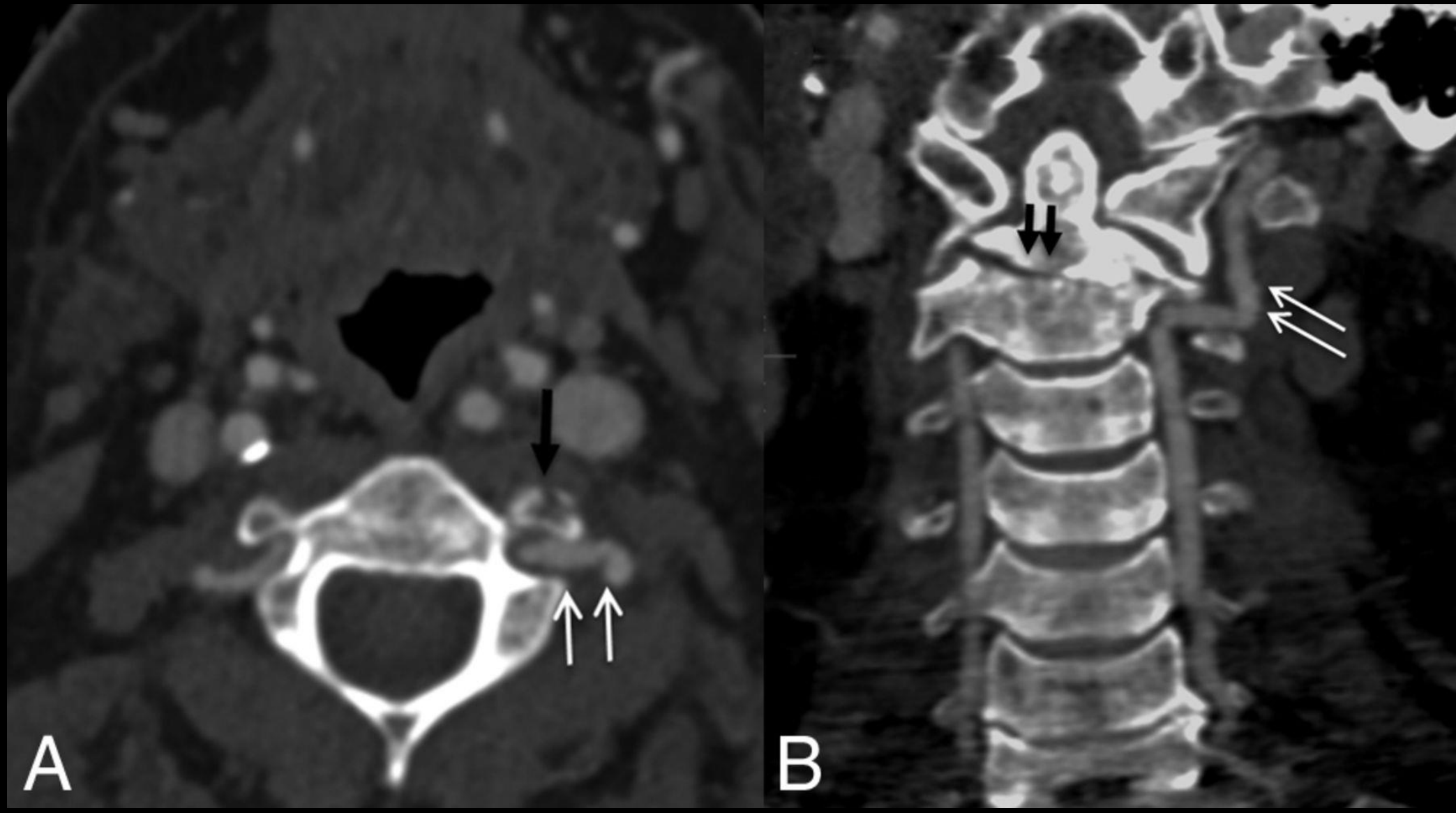

Table of contents

Order: Neck MRA
Reason for exam: Dissection

What sequence should we add?

A. Time of Flight
B. Black blood fat-saturated
C. T1 non-fat saturated MRA
D. Phase contrast

Table of contents

Order: Neck MRA
Reason for exam: Dissection

What sequence should we add?

A. Time of Flight
B. Black blood fat-saturated
C. T1 non-fat saturated MRA
D. Phase contrast

B. Black blood fat-saturated

Table of contents

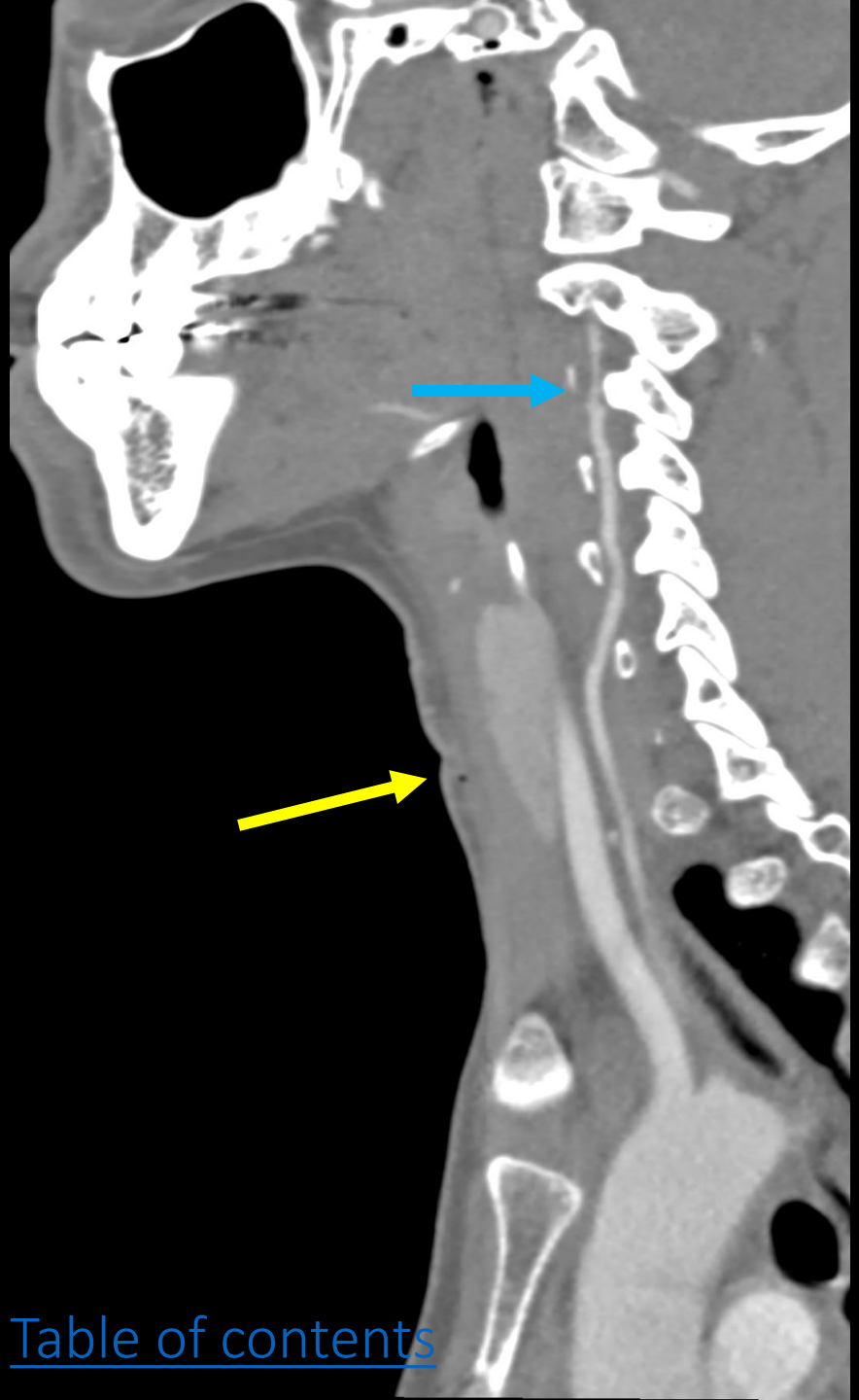

Black blood: T1 Fat-saturated

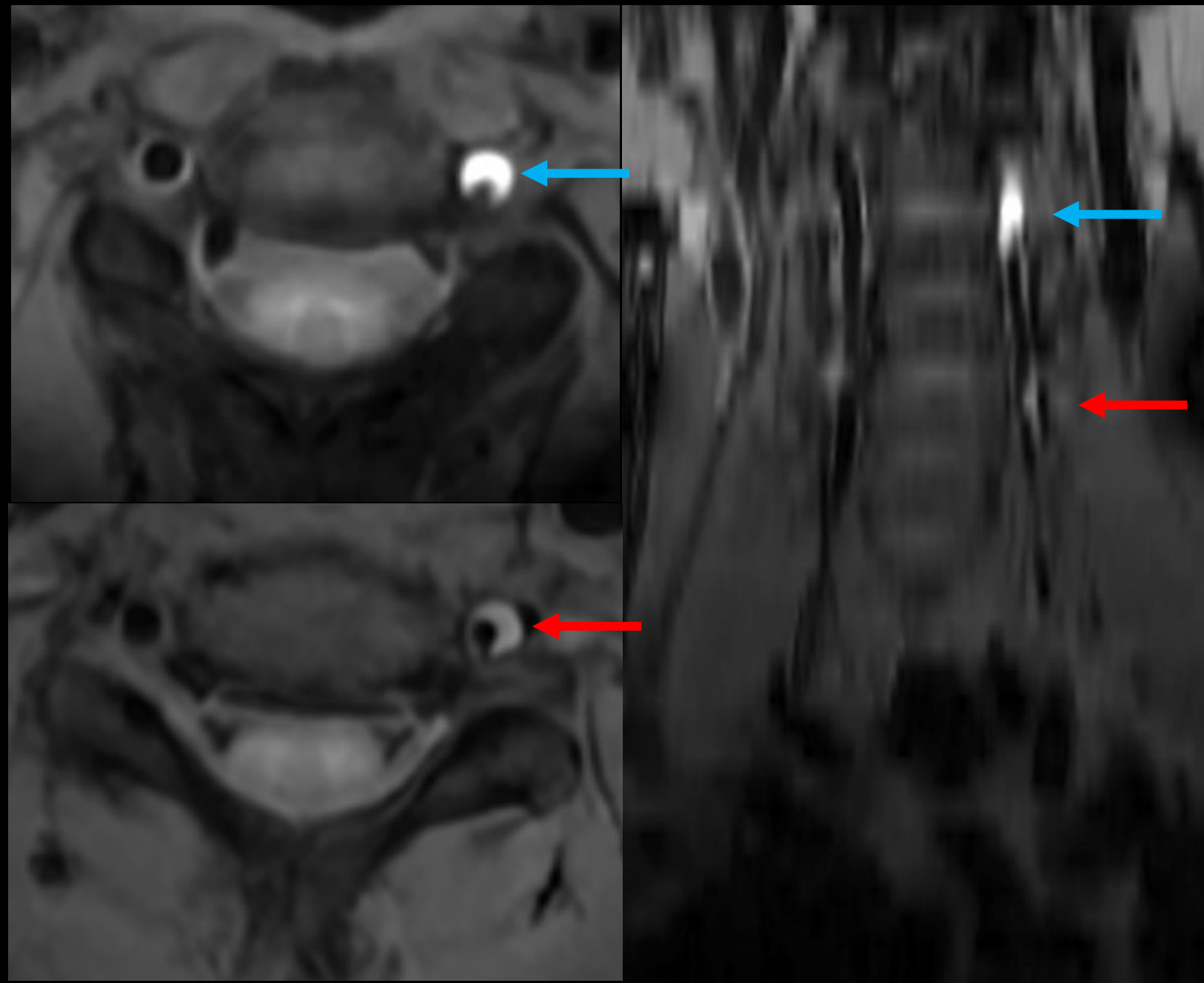

Table of contents

Reason for exam: Aneurysm

A. Brain C+
B. MRA Head WO
C. MRA Head C+
D. Change to CTA

Table of contents

Reason for exam: Aneurysm

A. Brain C+
B. MRA Head WO
C. MRA Head C+
D. Change to CTA

B. MRA Head WO

Table of contents

Reason for exam: Aneurysm s/p coiling

A. MRA
B. CTA

Table of contents

Reason for exam: Aneurysm s/p coiling

A. MRA
B. CTA

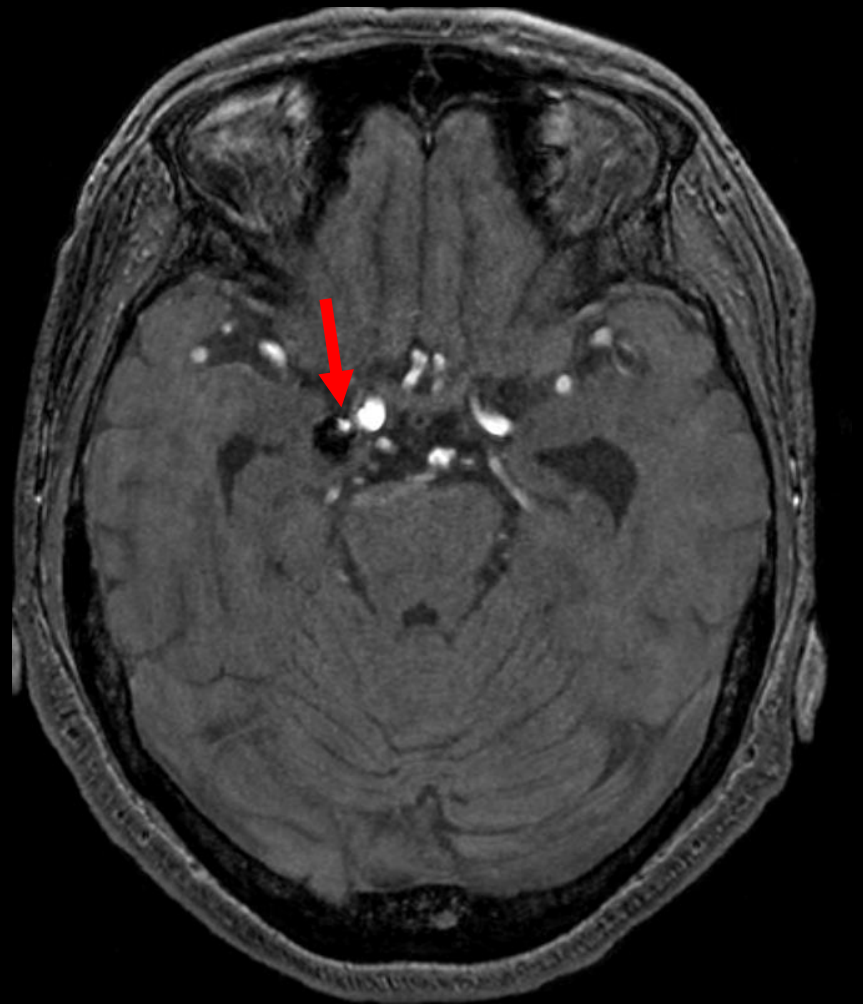

A. MRA

Table of contents

Reason for exam: Aneurysm s/p clipping

A. MRA Head C+
B. CTA
C. MRA Head WO

Table of contents

Reason for exam: Aneurysm s/p clipping

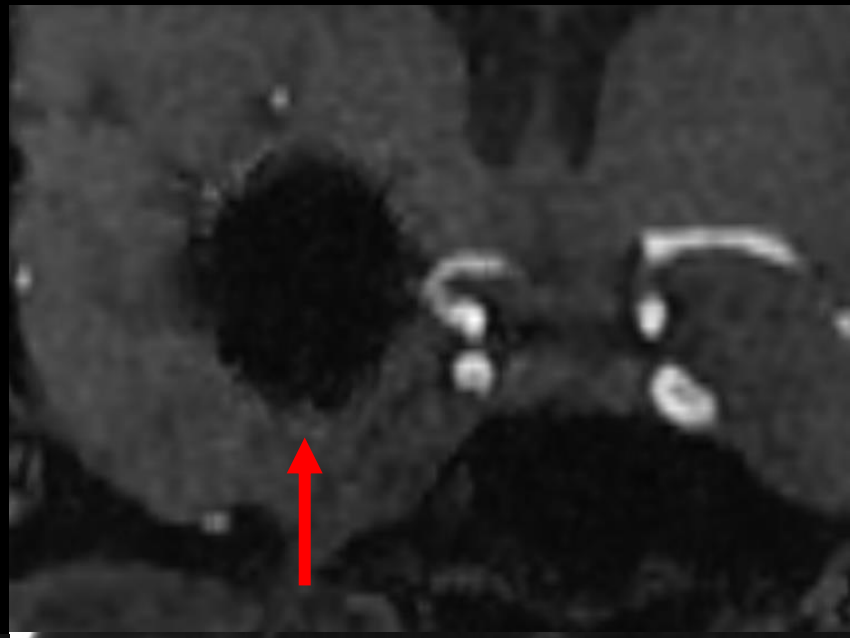

A. MRA Head C+
B. CTA
C. MRA Head WO

C. CTA

Table of contents

Aneurysm coiling

- MRA is superior to CTA
- Significant beam-hardening and streak artifact on CTA
- Contrast can increase visualization of residual aneurysm
- Exception: Flow-diverter stent, CTA is more useful for evaluation in-stent lumen/stenosis

Aneurysm clipping

- CTA is superior to MRA
- Clips cause marked metallic susceptibility artifact at MRI
- CTA is first-line imaging modality

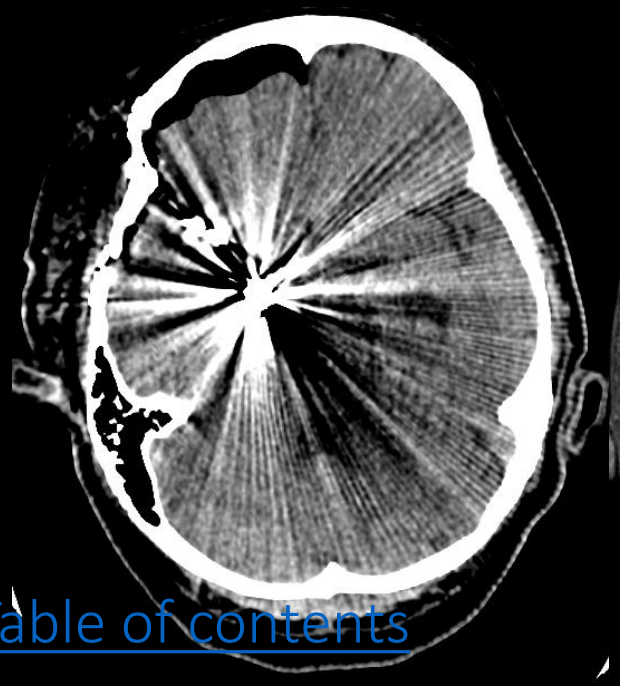

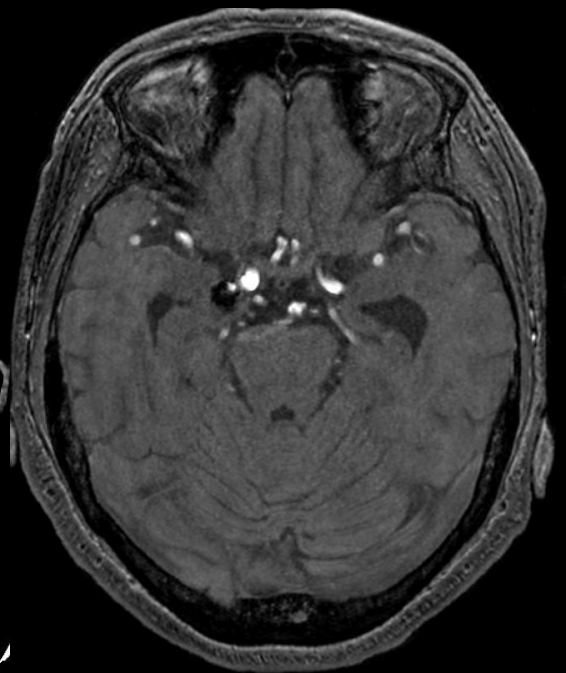

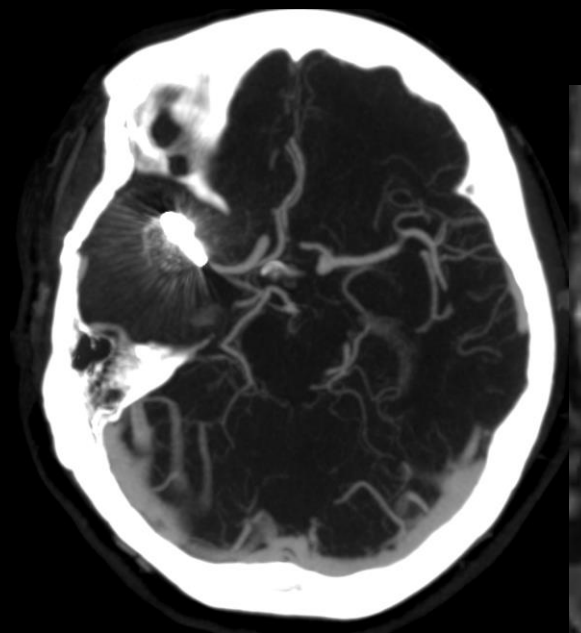

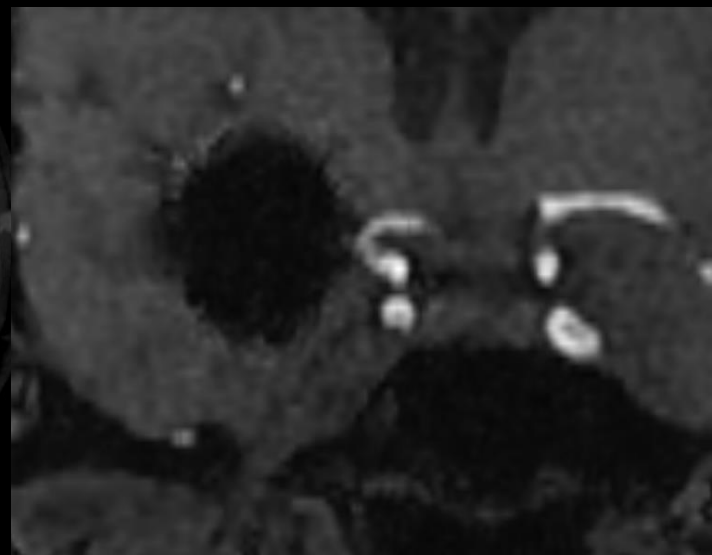

Table of contents

MR Angiography

- Most techniques use T1-weighted echo gradient sequences
- Most suppress background signal of stationary tissue (except black blood)
- All techniques can be adapted to 3D

Table of contents

Time of Flight (non-contrast)

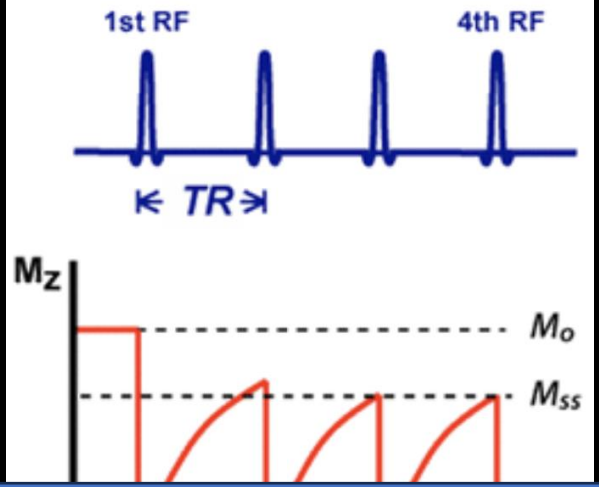

Adapted from https://doi.org/10.1148/rg.2021210141

Saturation-band for incoming venous signal

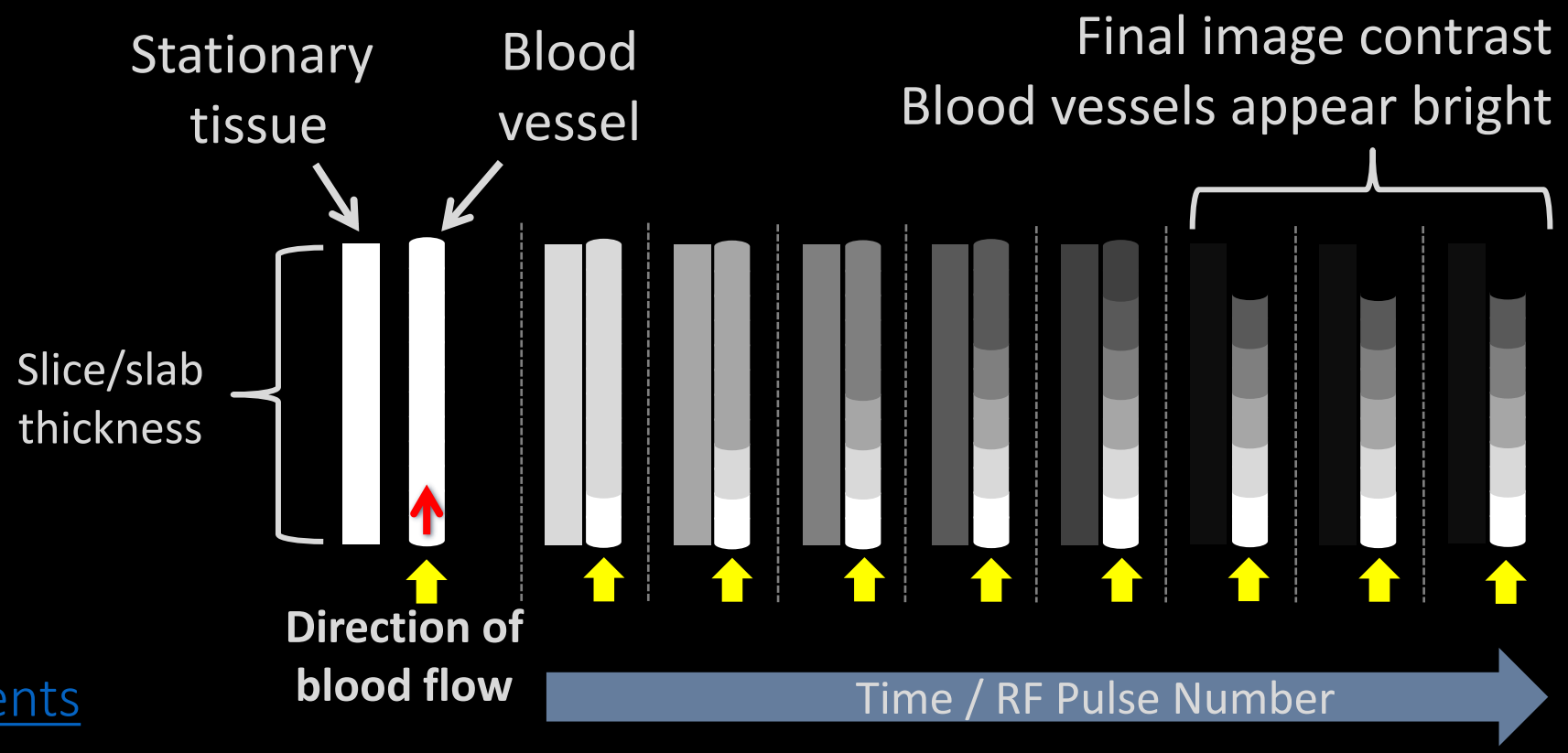

Table of contents

2D TOF

- Fine slices are stacked alongside each other
- Sensitive to slow flows (which do not remain in the slice for long and will therefore not be saturated)
- Poor spatial resolution along the axis of the slice stack

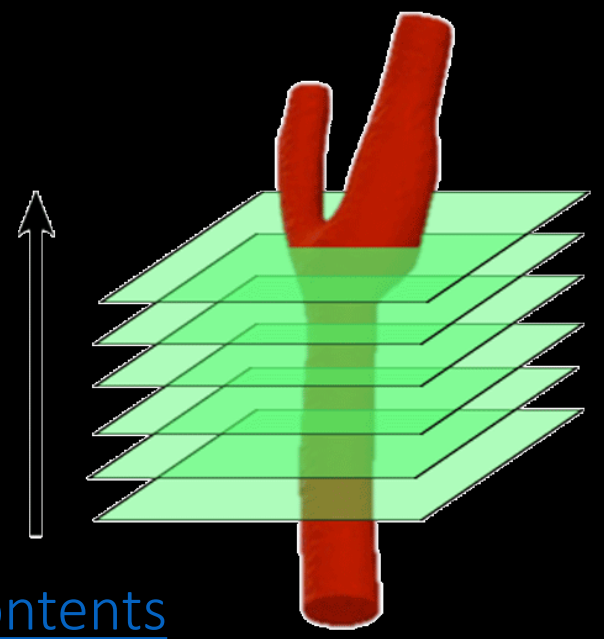

3d TOF

- Good spatial resolution in all 3 planes
- Better signal-to-noise ratio
- Longer acquisition

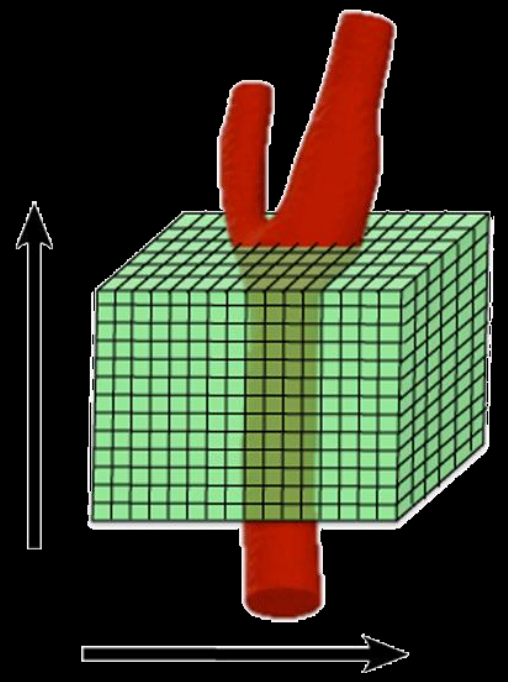

Table of contents

2D TOF

3D TOF

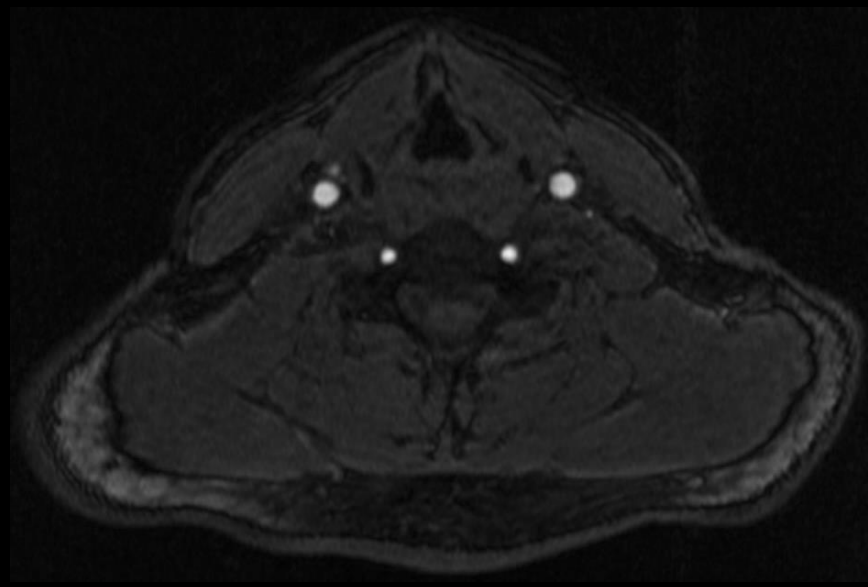

Table of contents

Phase-Contrast MRA

Signal in arteries + veins

Axial

Table of contents

Phase-Contrast (no gadolinium)

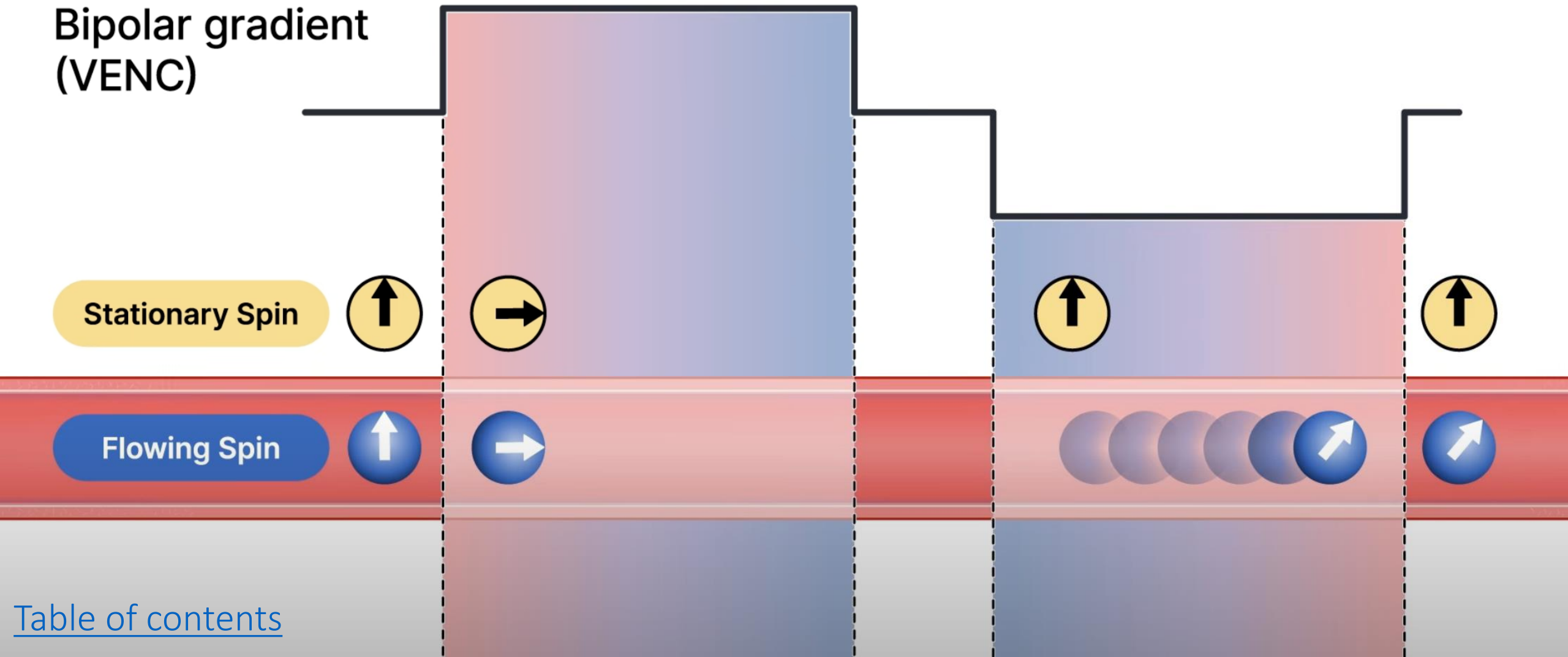

Table of contents

Challenge case

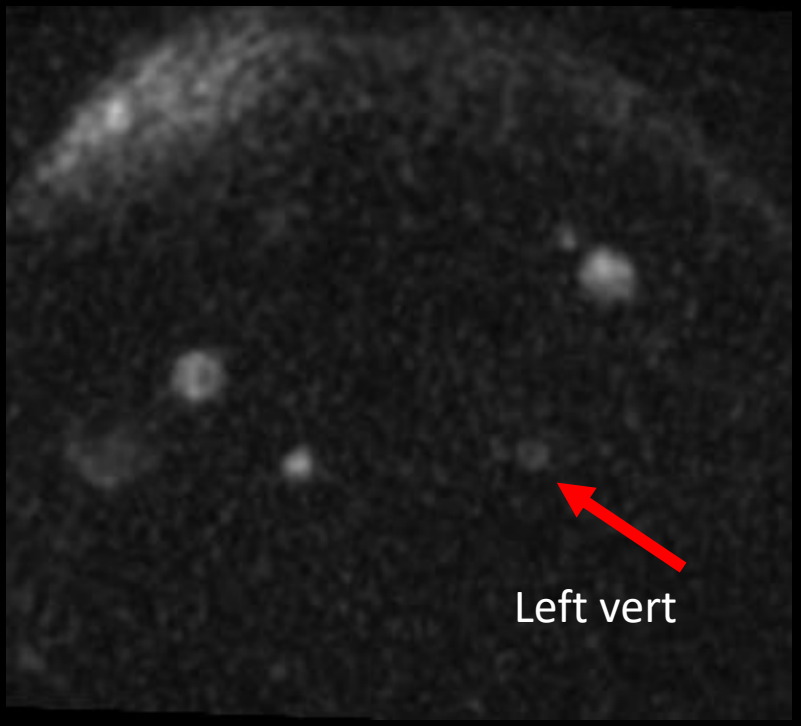

3D InHance
(phase contrast)

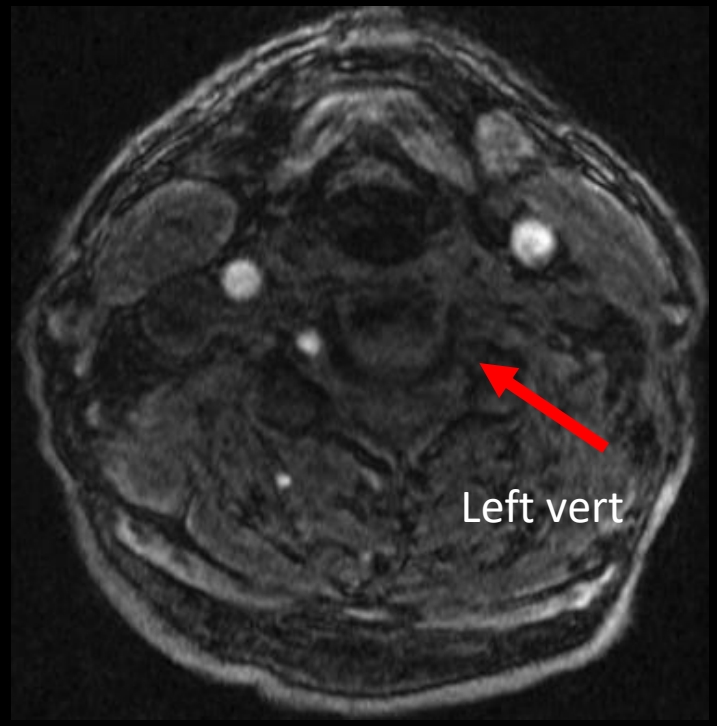

3D TOF

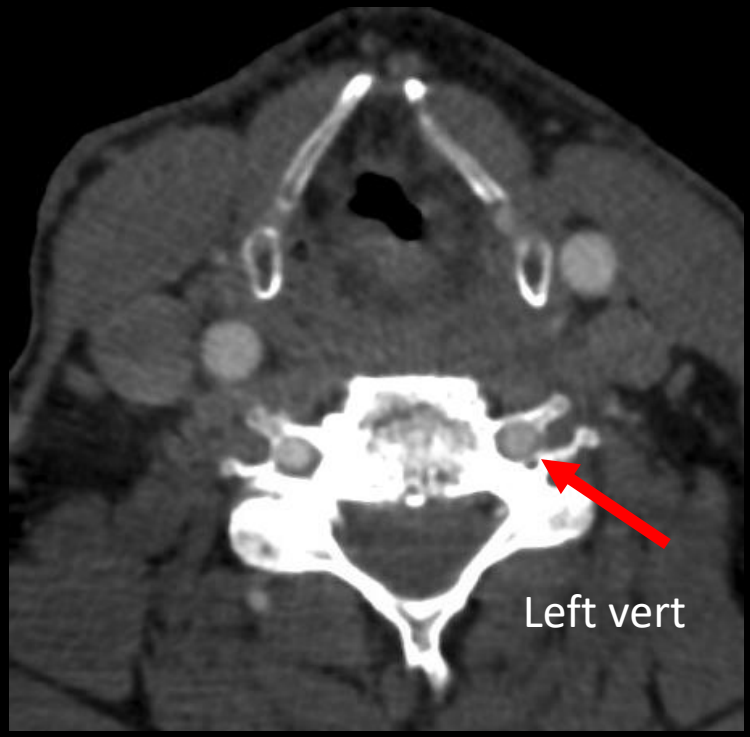

CTA

Table of contents

Subclavian Steal

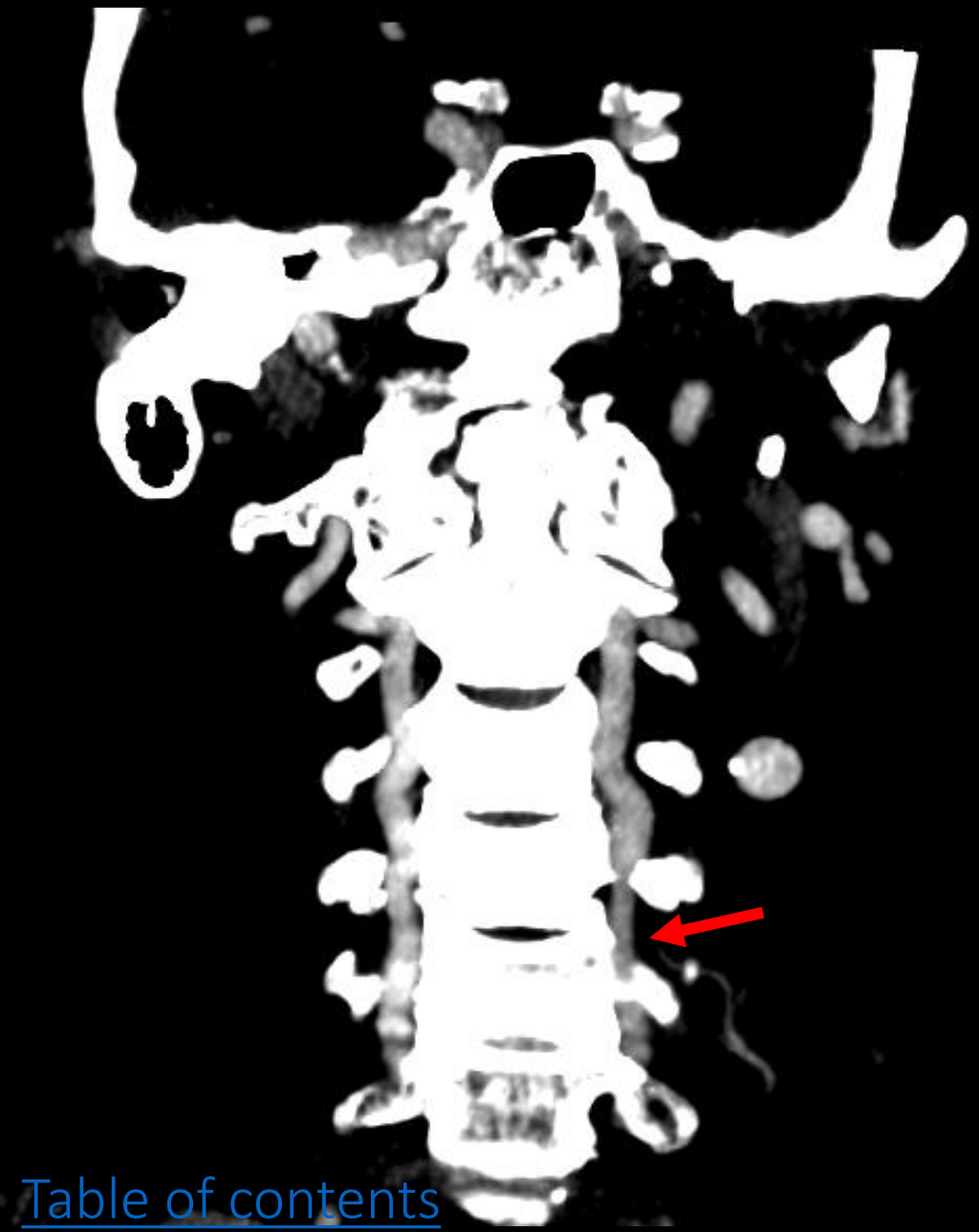

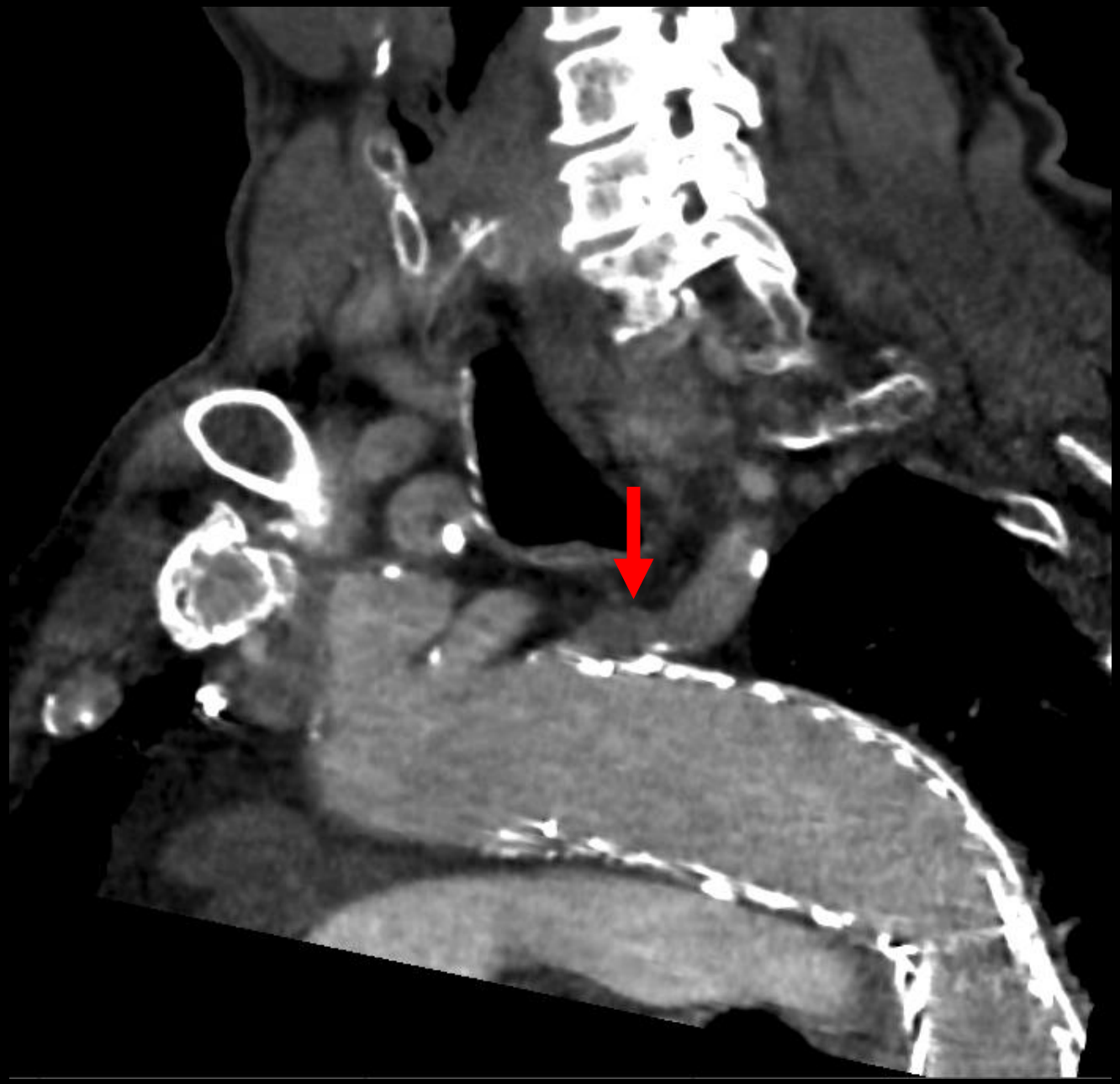

Table of contents

Challenge case

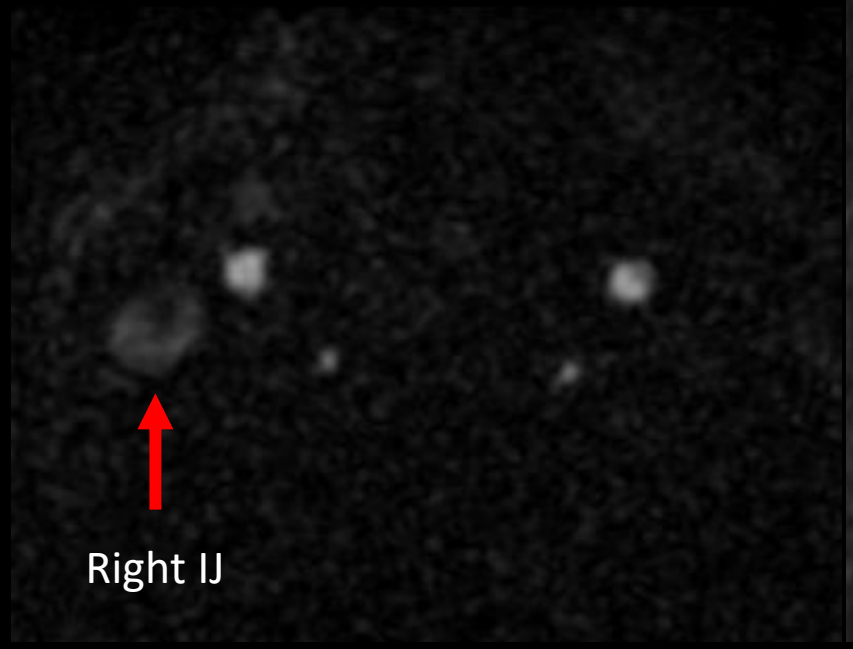

3D InHance
(phase contrast)

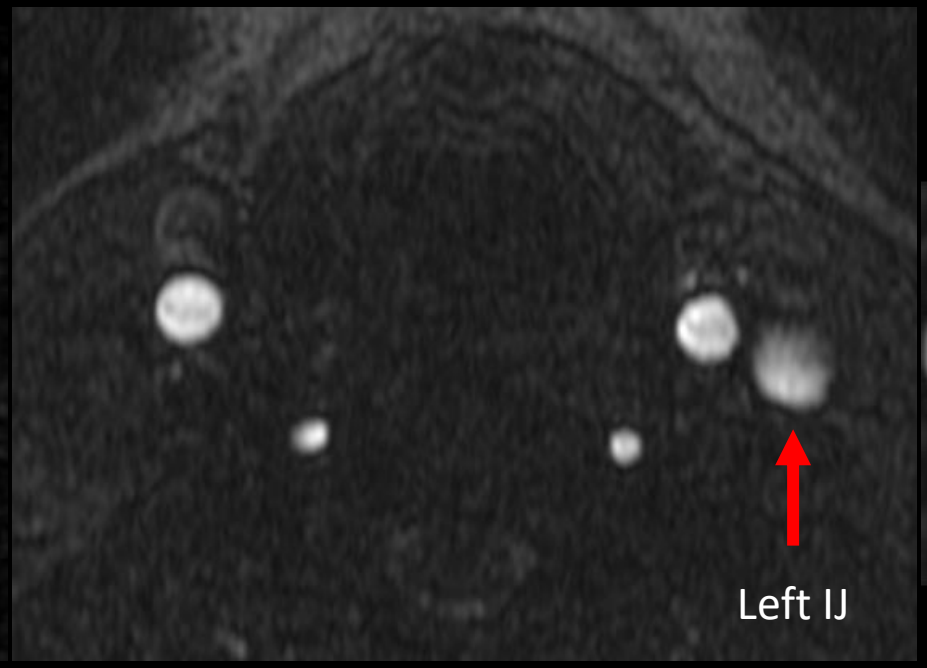

2D TOF

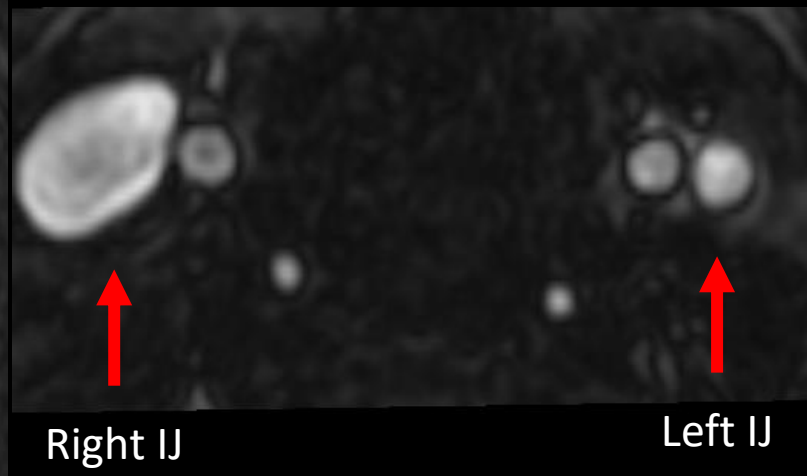

MRA C+

Table of contents

Jugular venous reflux

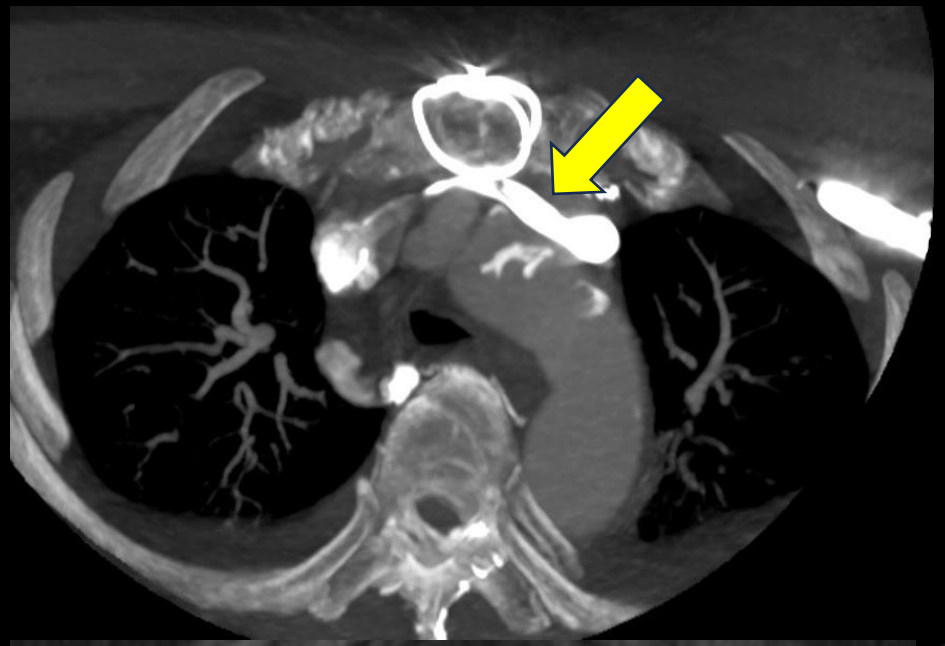

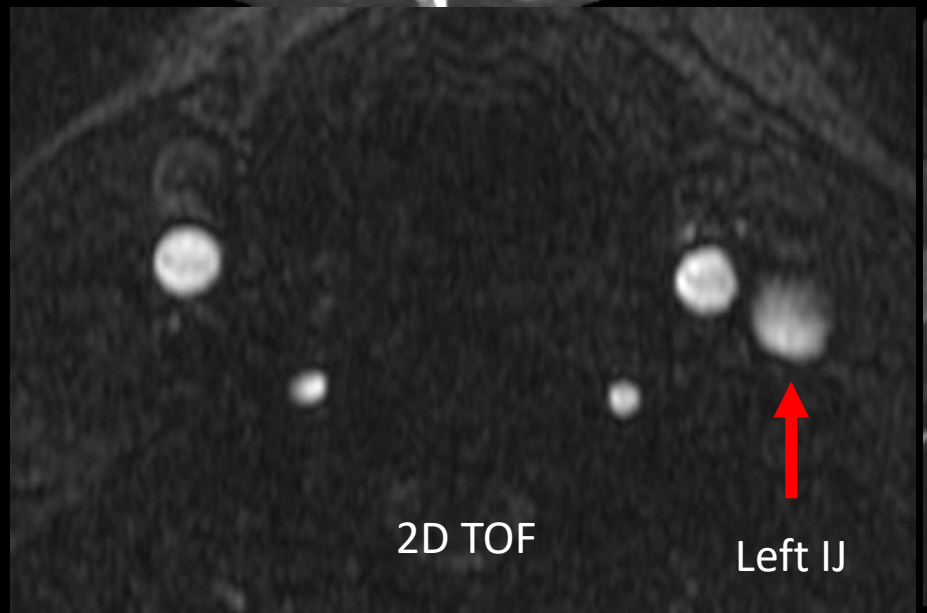

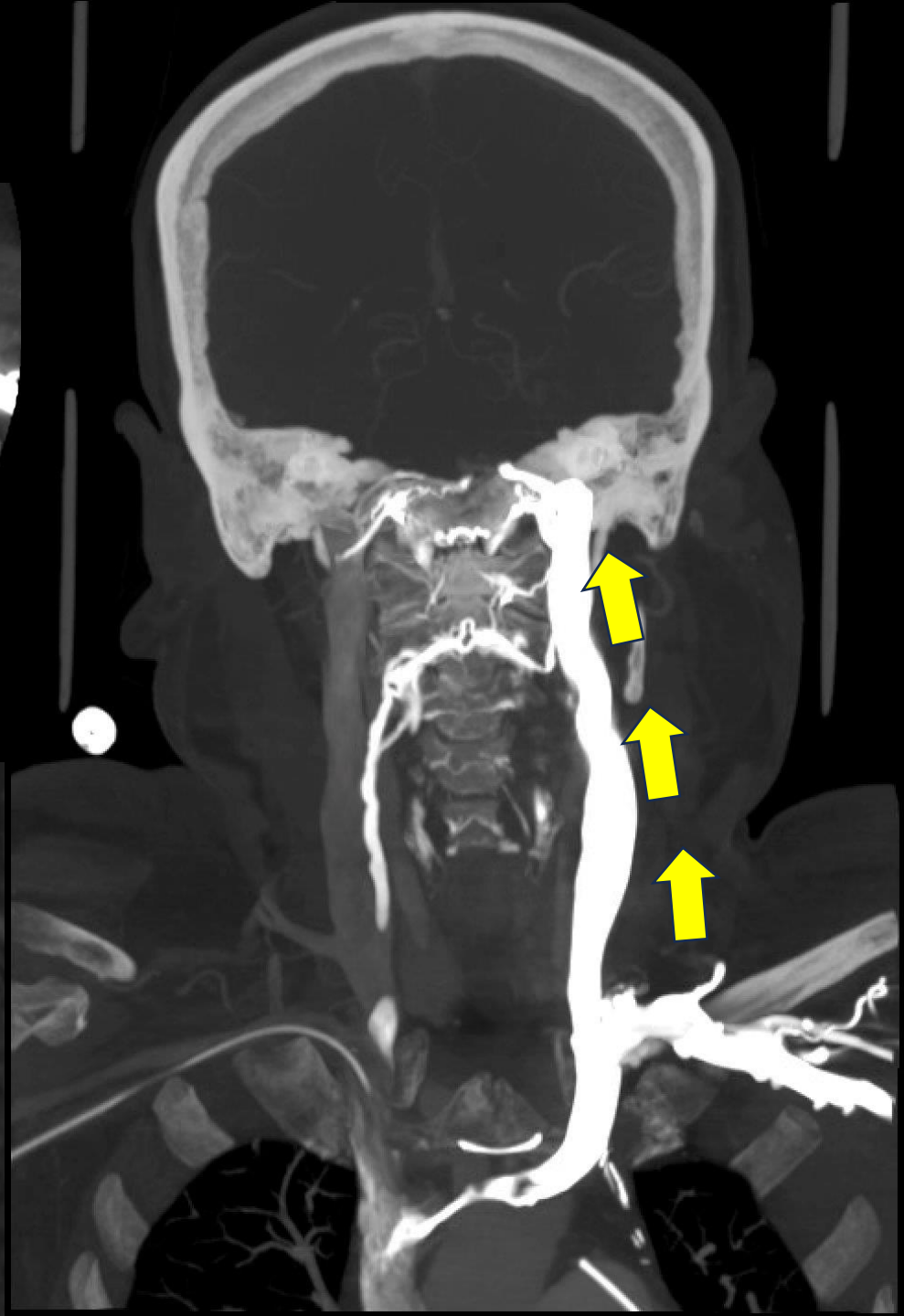

Table of contents

Reason for exam: Cerebral venous thrombosis

A. MRA C+
B. MRV WO
C. MRV C+
D. MRI Brain WO/W

Table of contents

Reason for exam: Cerebral venous thrombosis

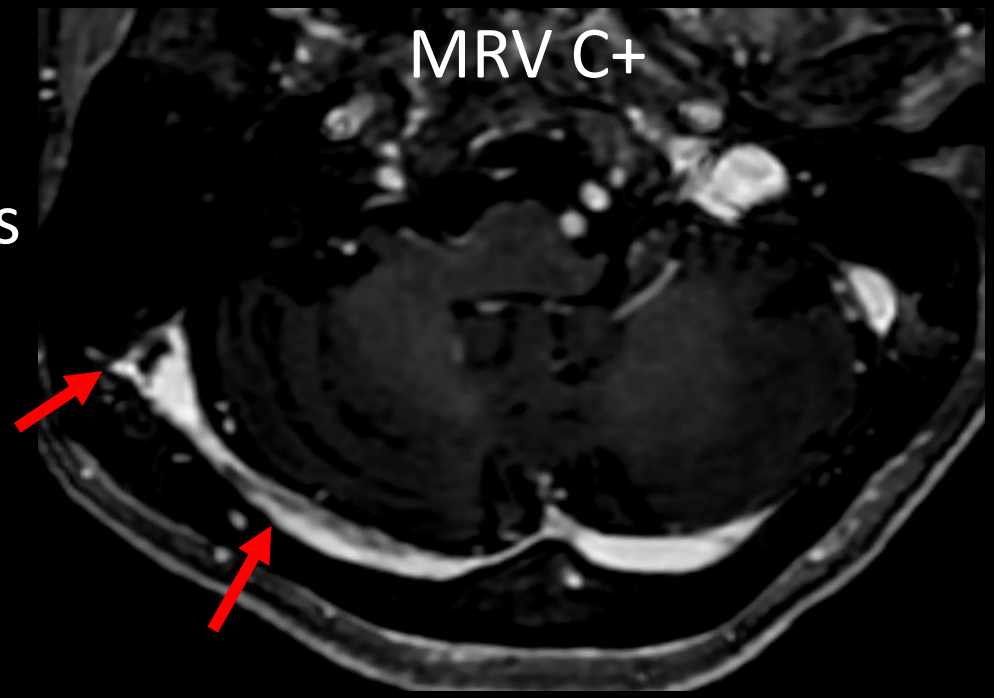

A. MRA C+
B. MRV WO
C. MRV C+
D. MRI Brain WO/W

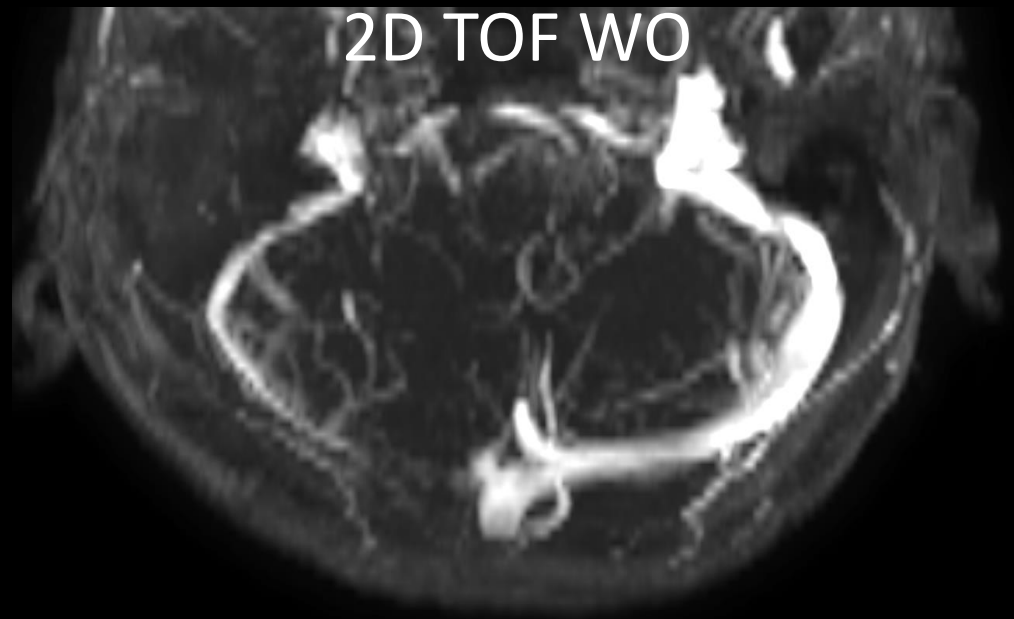

C. MRV C+

Table of contents

Reason for exam: Acute focal neurological deficit, stroke

A. Acute stroke
B. Brain WO
C. Brain C+
D. MRA Head

Table of contents

Reason for exam: Acute focal neurological deficit, stroke

A. Acute stroke
B. Brain WO
C. Brain C+
D. MRA Head

B. Brain WO

Table of contents

Brain WO

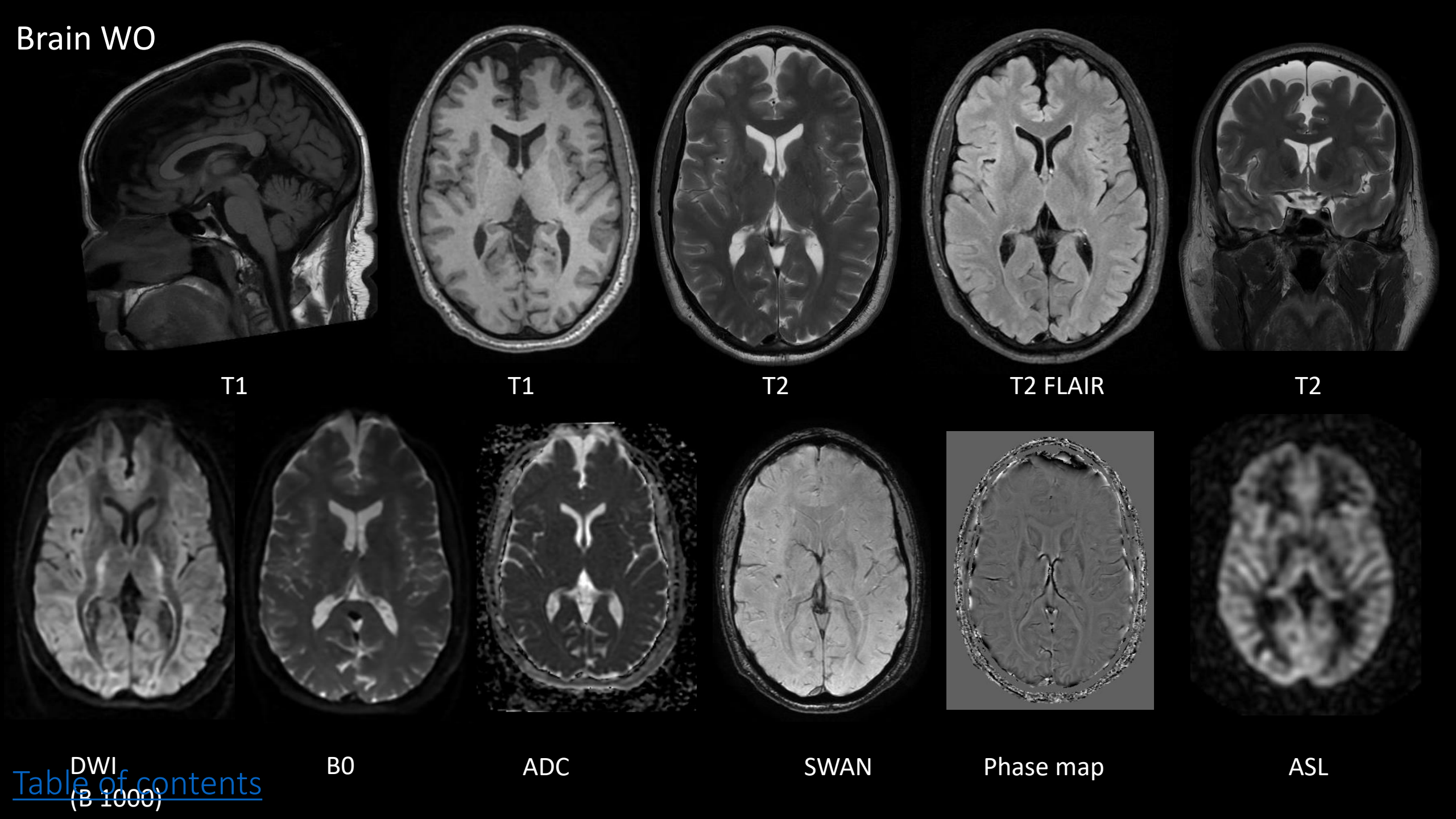

Table of contents

Acute Stroke

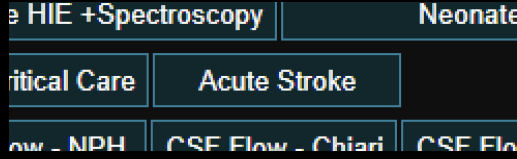

- For patients who are candidates for intervention (in the 6-24 hour or wake-up stroke window)
- Not for “standard” stroke work-up
- **Stroke team** must put in “Acute Stroke Brain MRI” orders

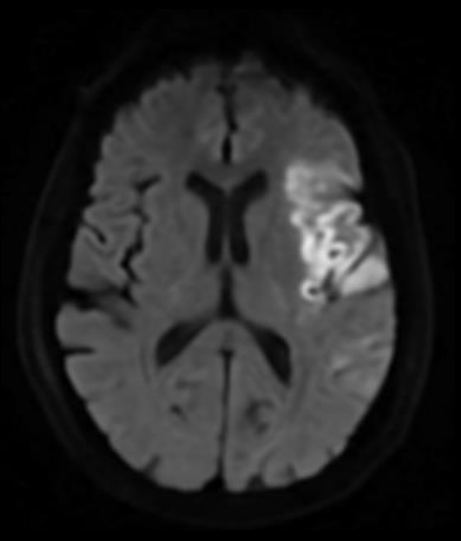

DWI

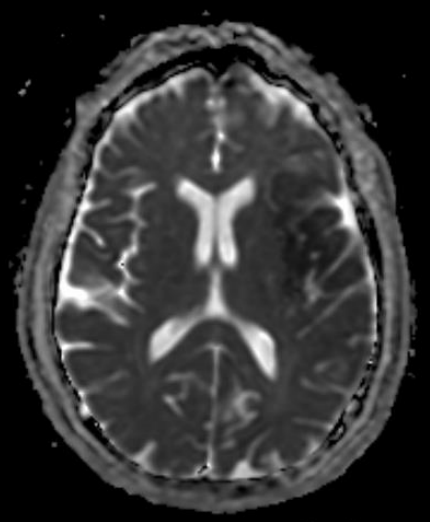

ADC

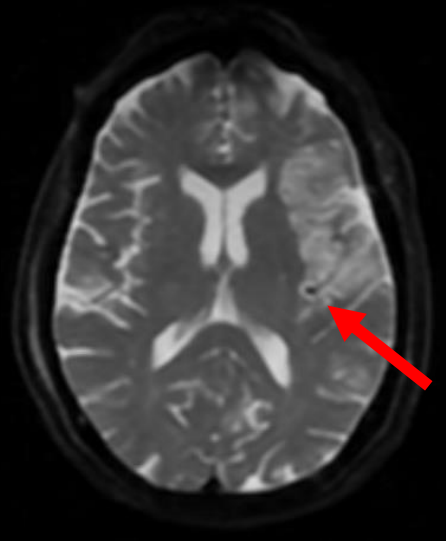

B0

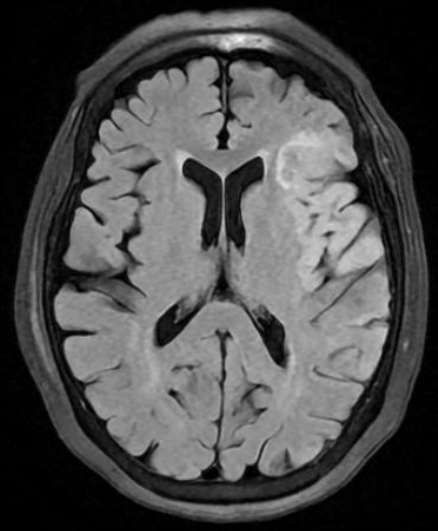

T2 FLAIR

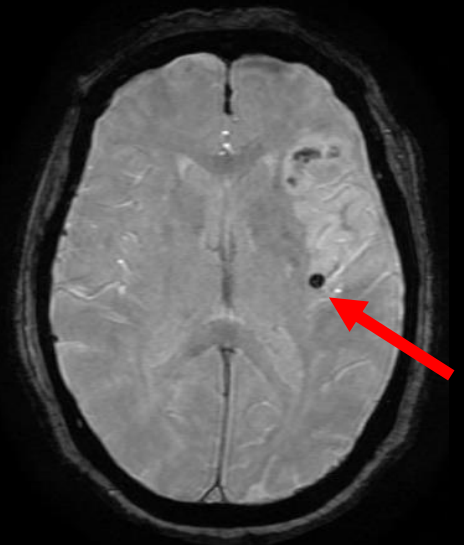

SWAN

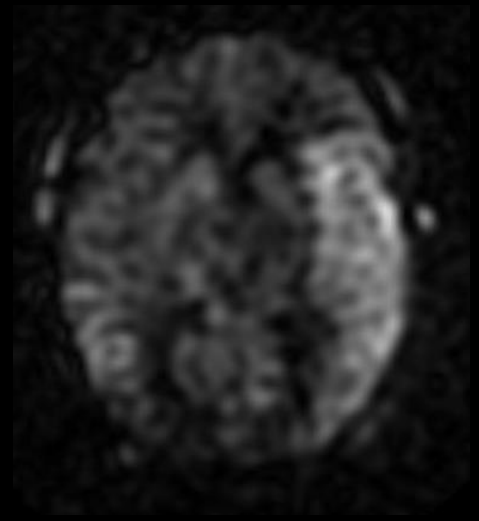

ASL

Table of contents

Which sequence in the routine Brain WO protocol is the fastest sequence to perform?

DWI
~1 min

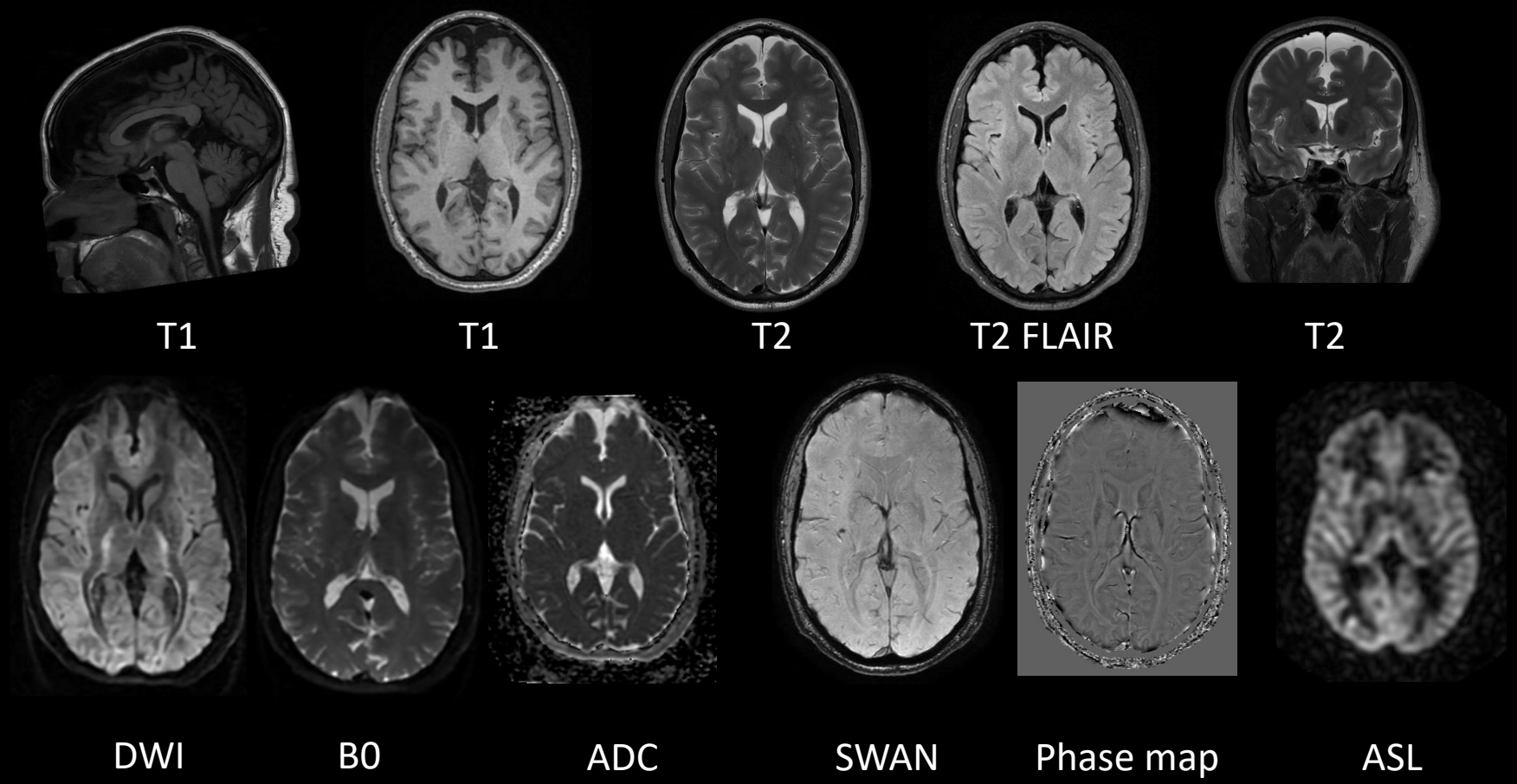

Table of contents

Diffusion weighted imaging

Single-shot echo planar imaging (standard)

- Acquires all of k-space lines with one RF excitation pulse (single TR) per slice
- Fast acquisition (few motion artifacts)
- Prone to susceptibility artifacts (distortion near air-bone interfaces)

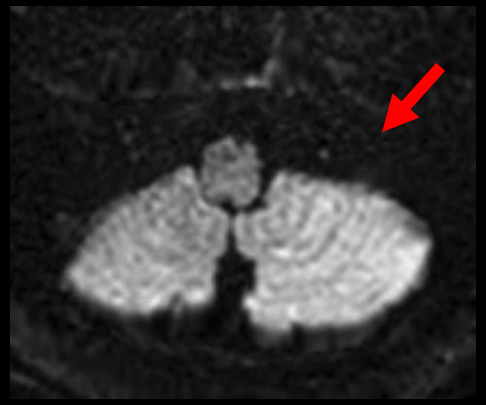



MUSE (Multiplexed Sensitivity-Encoding)

- Multi-shot EPI sequence designed to improve resolution and reduce distortion compared to standard single-shot EP
- Acquires data over multiple shots rather than a single shot
- Higher resolution
- Reduced geometric distortion (better for regions affected by susceptibility artifacts, such as the skull base and orbits)
- Longer scan times, more motion artifact

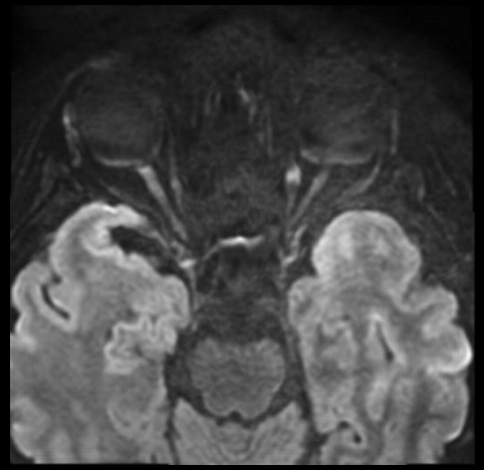

DWI MUSE

DWI PROP

PROPELLER

- Non-EPI DWI (utilizes fast-spin echo), acquires multiple overlapping radial "blades" in k-space and averages them for artifact reduction.
- Significantly reduced motion artifacts
- Lower susceptibility artifacts than ss-EPI (less distortion in air-bone interfaces like the skull base)
- Higher SNR than standard DWI due to multiple overlapping k-space acquisitions.
- Longer scan times

Table of contents

Diffusion weighted imaging

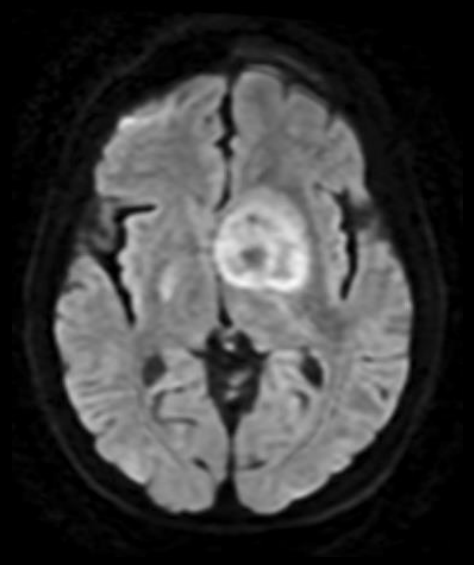

B-1000

÷

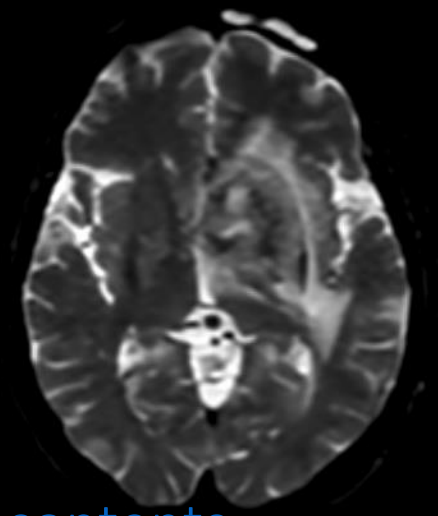

B0

ADC

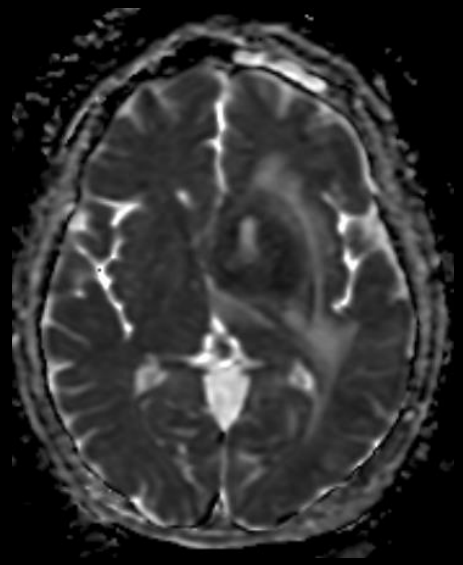

Quantitative

Even more math

eADC

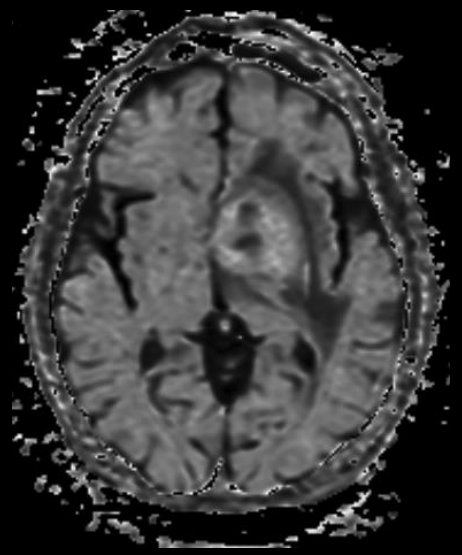

Qualitative

ADC tells you whether diffusion is truly restricted;
eADC just makes restricted areas easier to see

Table of contents

Reason for exam: Stroke, “thin cuts” through the brain stem.

What additional sequence would probably be most helpful for posterior circulation infarct?

A. Coronal DWI
B. Axial thin slice DWI
C. T2 CUBE IAC
D. FIESTA IAC

Table of contents

Reason for exam: Stroke, “thin cuts” through the brain stem.

What additional sequence would probably be most helpful for posterior circulation infarct?

A. Coronal DWI
B. Axial thin slice DWI
C. T2 CUBE IAC
D. FIESTA IAC

A. Coronal DWI

Table of contents

DWI in a different plane (eg, coronal) is often most helpful (if had to pick one)

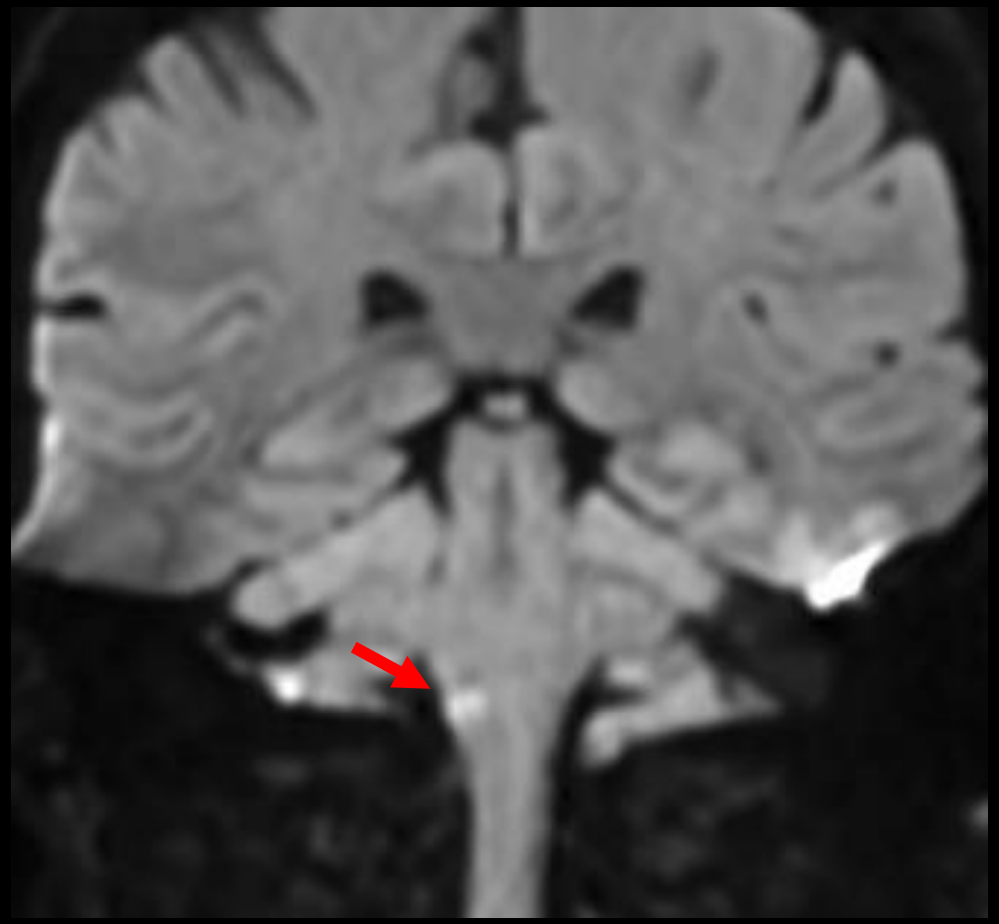

Table of contents

FIESTA

- Slightly higher spatial resolution
- More CSF pulsation artifact
- Faster

T2 CUBE

- Better T2 weighting and tissue contrast
- Less CSF pulsation artifact
- Slower

FIESTA

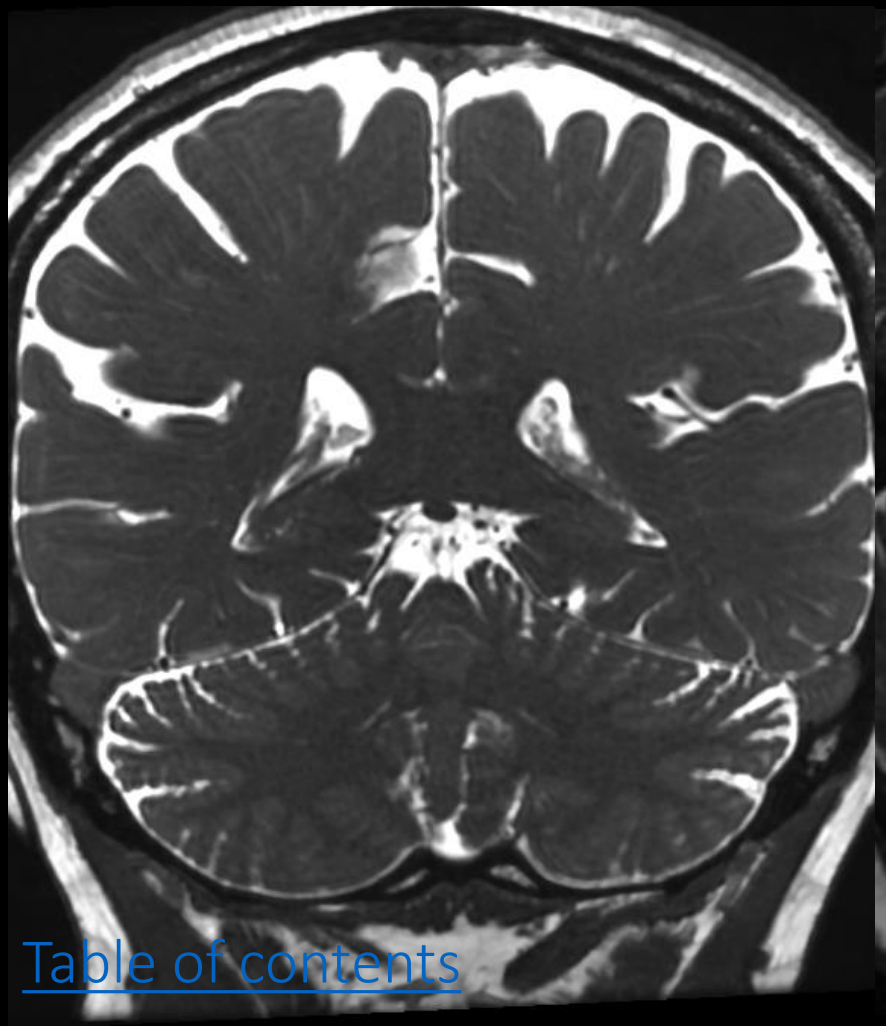

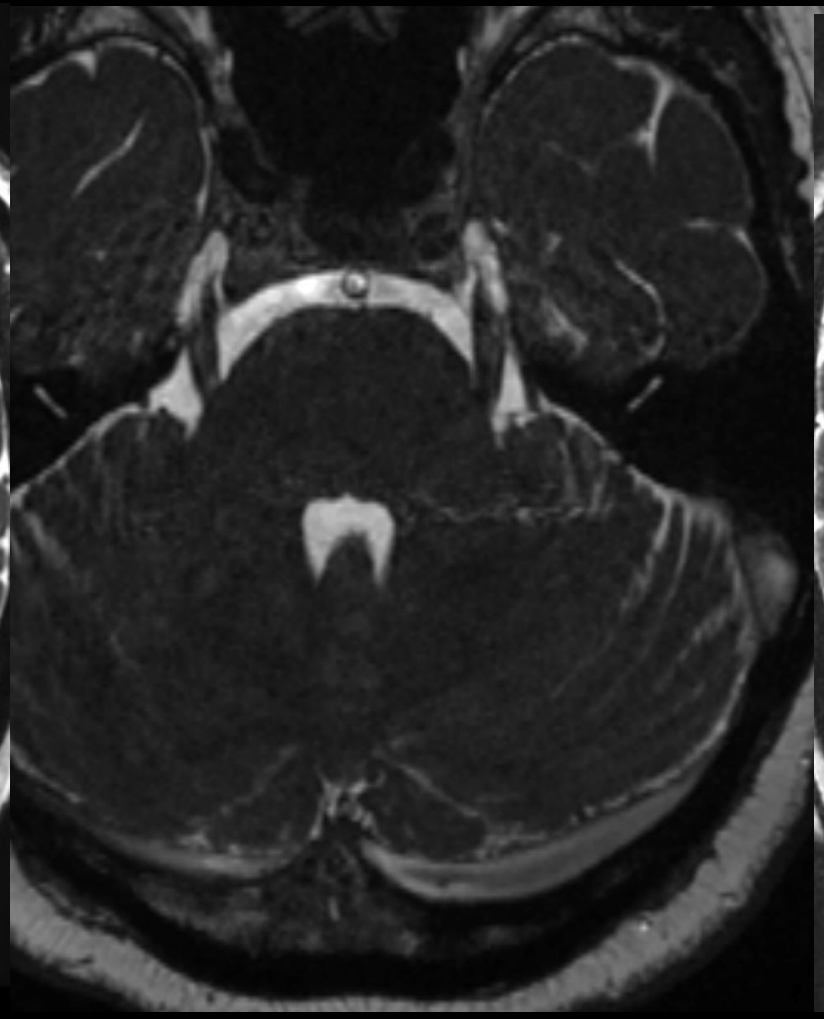

T2 CUBE

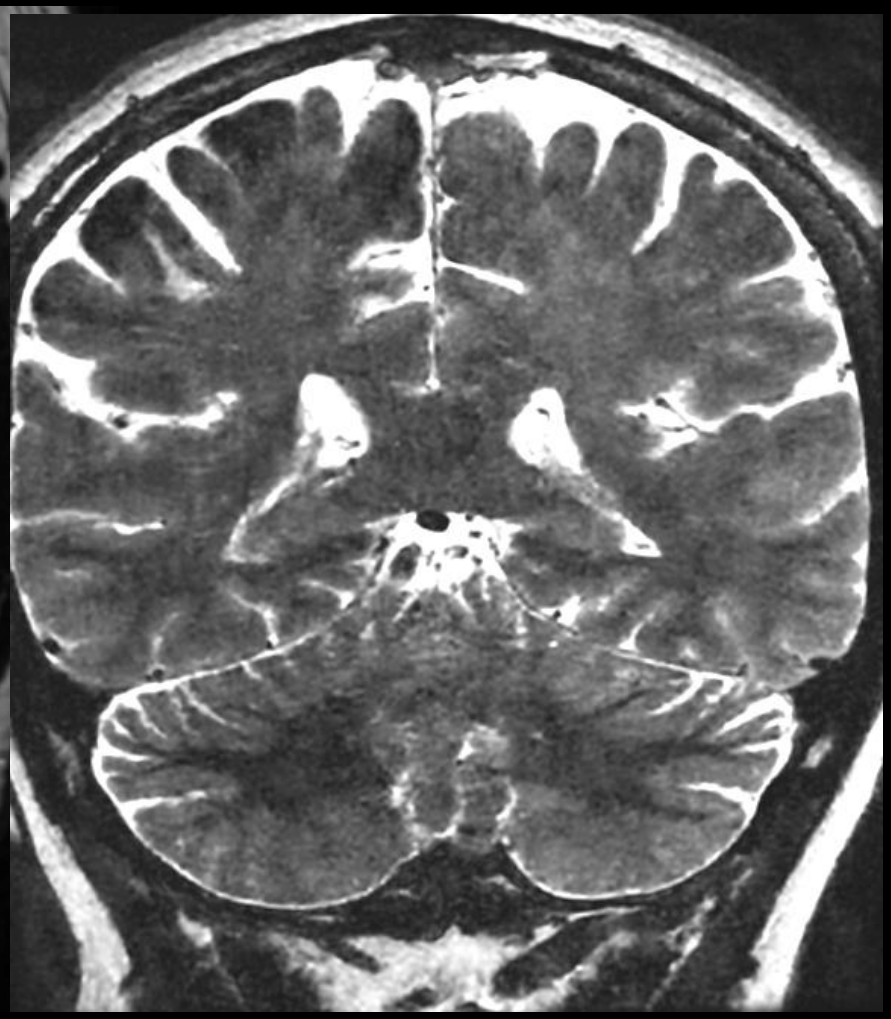

Table of contents

Reason for exam: Headaches, blurred vision, evaluate for pseudotumor cerebri

A. Brain WO
B. Brain C+
C. Brain Mets
D. Head MRV WO

Table of contents

Brain C+

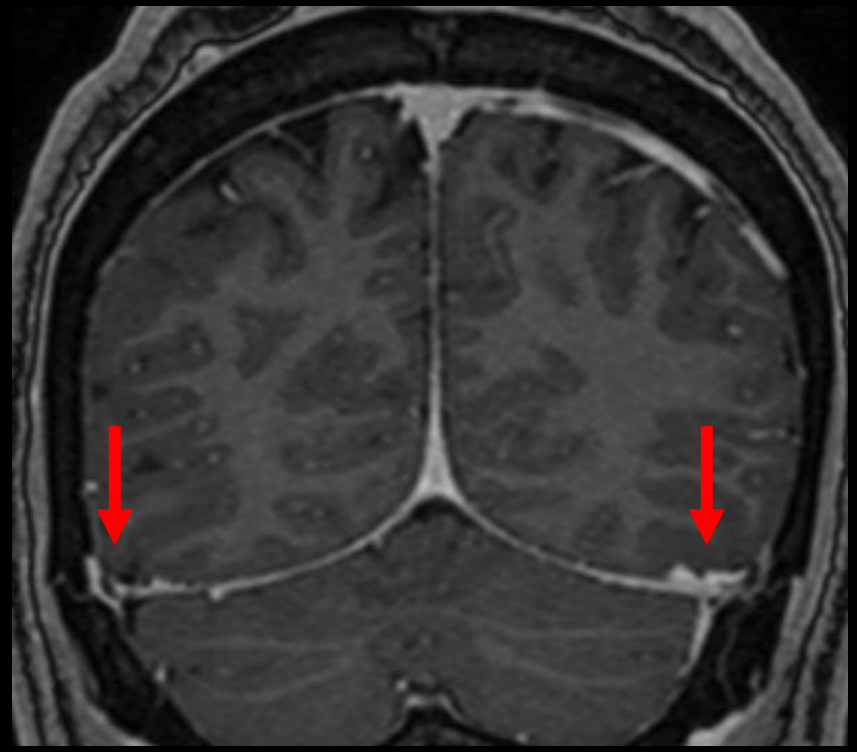

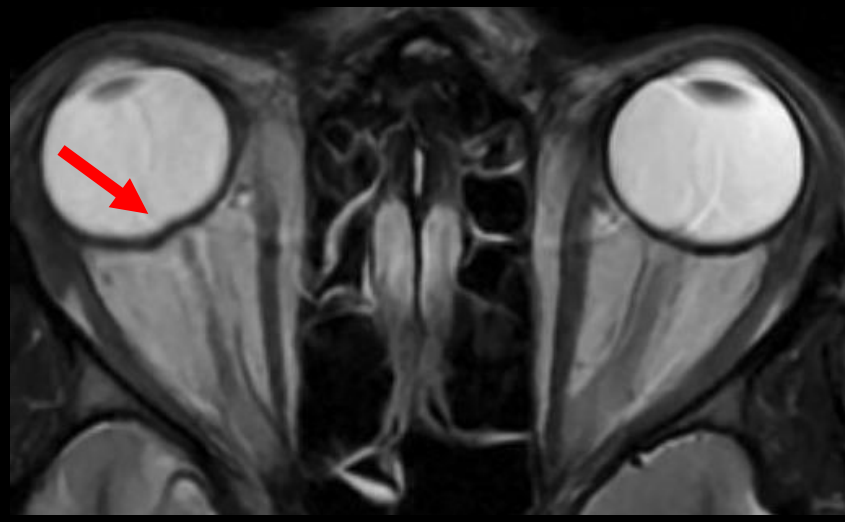

Table of contents

Which of the following pathologies should NOT receive a “Brain Tumor” protocol?

A. Meningioma
B. Glioblastoma
C. Medulloblastoma
D. Hemangioblastoma

Table of contents

Which of the following pathologies should NOT receive a “Brain Tumor” protocol?

A. Meningioma
B. Glioblastoma
C. Medulloblastoma
D. Hemangioblastoma

A. Meningioma

Table of contents

Reason for exam: Meningioma

A. Brain Mets
B. Brain Tumor
C. Brain C+
D. Head MRA

Table of contents

Reason for exam: Meningioma

A. Brain Mets
B. Brain Tumor
C. Brain C+
D. Head MRA

C. Brain C+

Table of contents

Brain C+

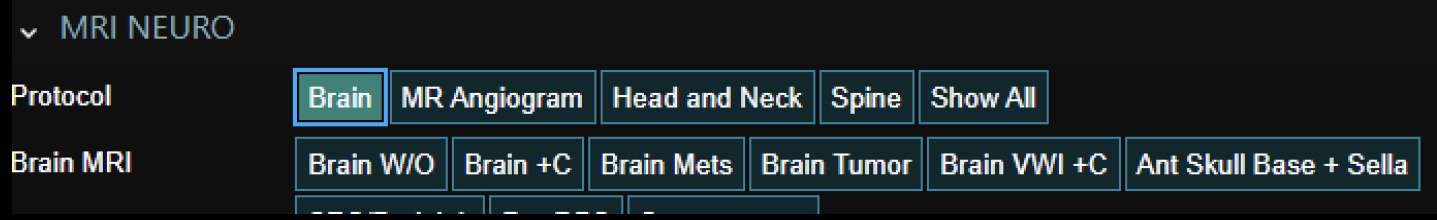

- Brain WO protocol PLUS:

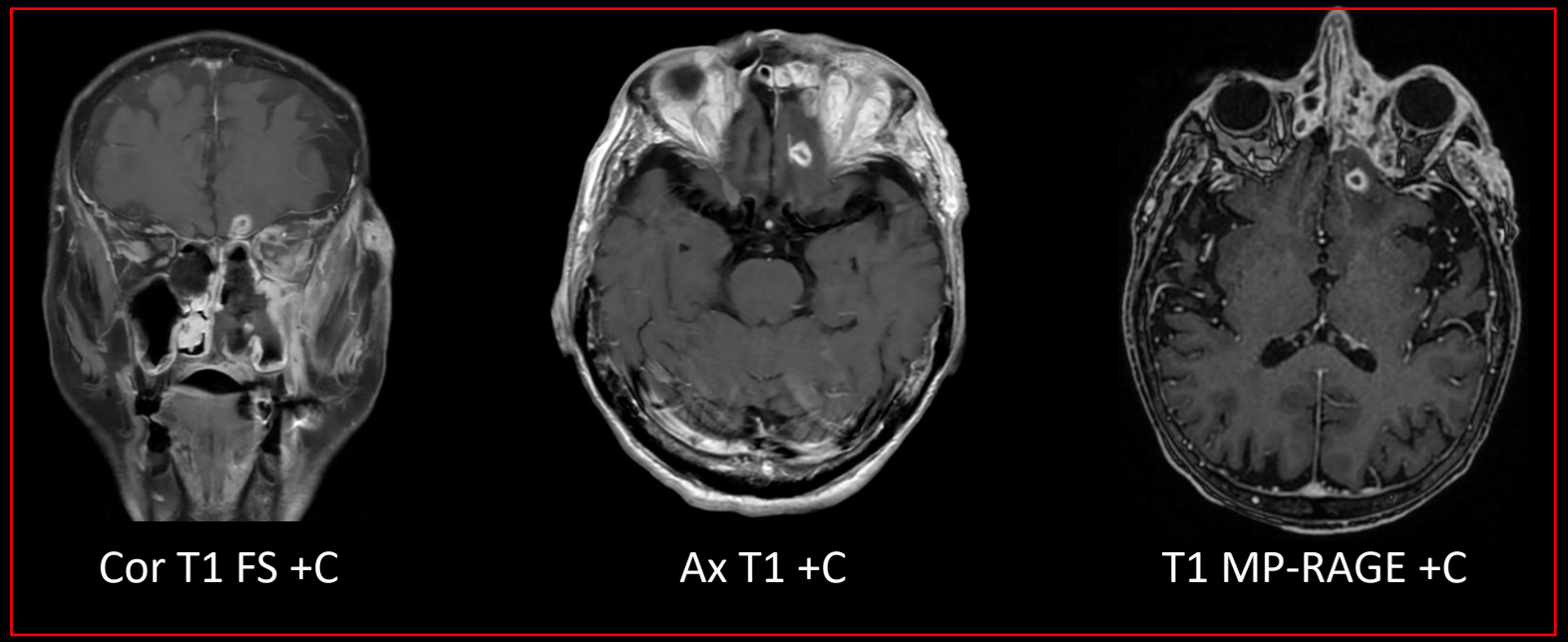

Table of contents

Brain Mets

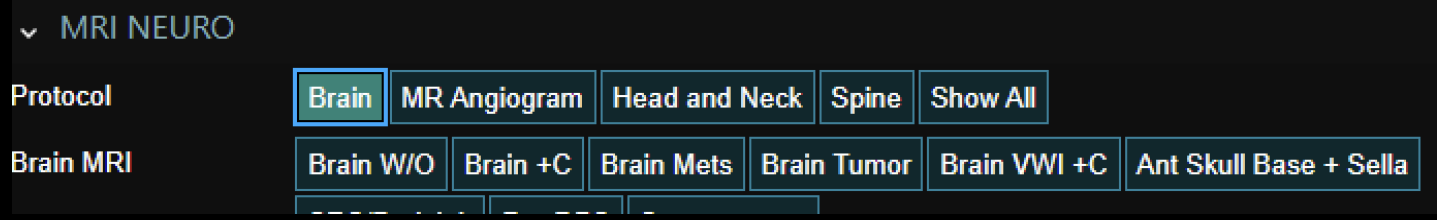

- Brain WO PLUS:

T2 FLAIR CUBE +C

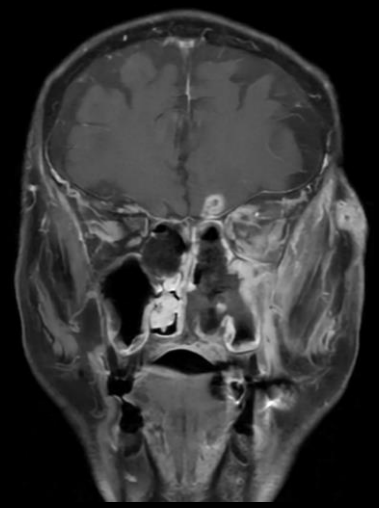

Cor T1 FS +C

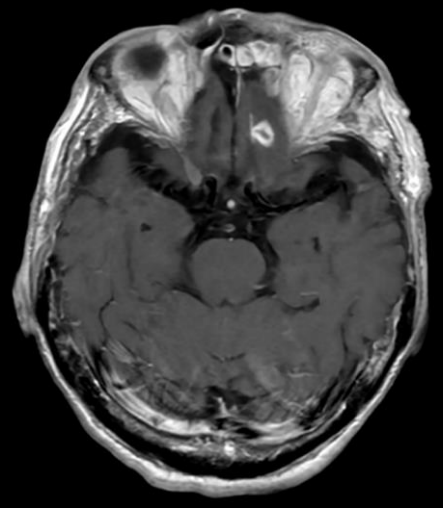

Ax T1 +C

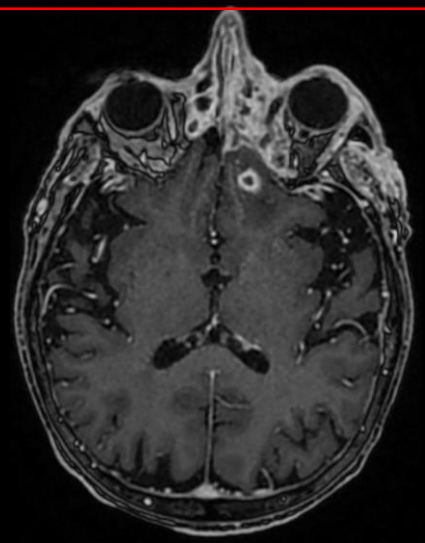

T1 MP-RAGE +C

T2 FLAIR shows contrast enhancement due to mild T1 weighting properties from its long inversion recovery pulse, despite being heavily T2-weighted

Table of contents

Brain Tumor

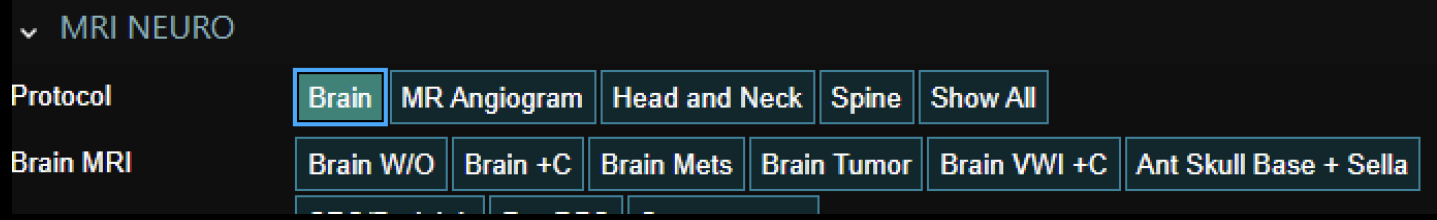

- Brain WO PLUS:

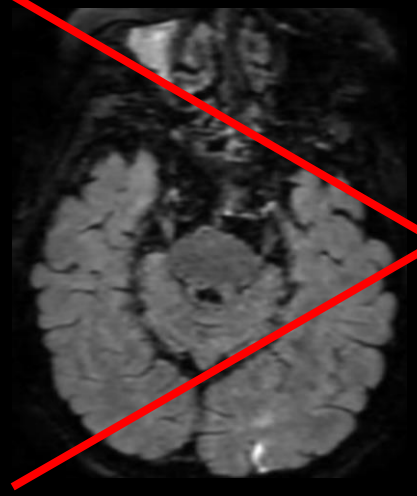

T2 FLAIR CUBE +C

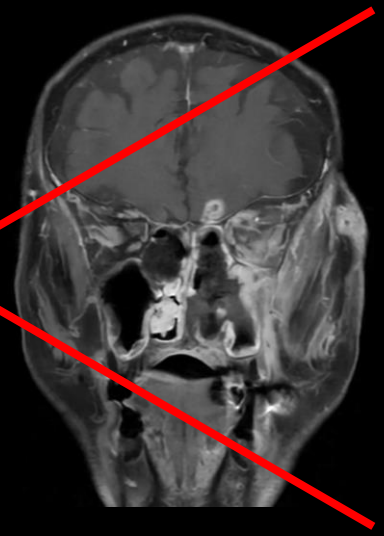

Cor T1 FS +C

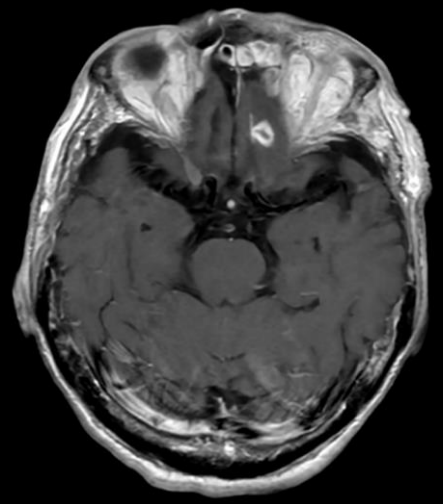

Ax T1 +C

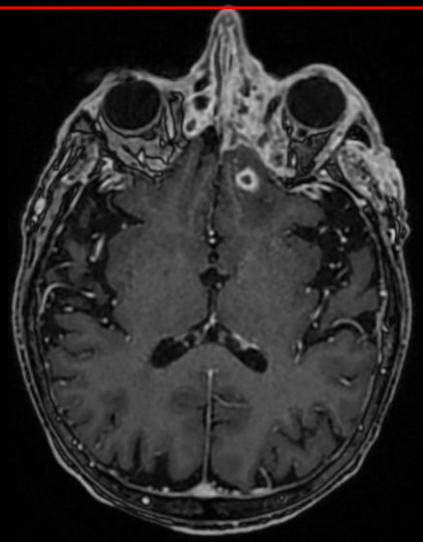

T1 MP-RAGE +C

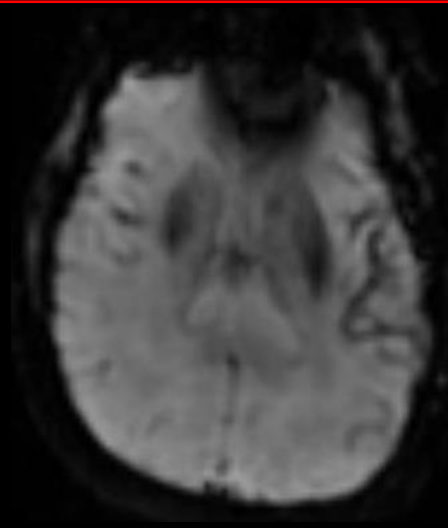

DSC Perfusion C+

Table of contents

Post-contrast Brain protocols

Brain C+	Default
Brain Mets	Leptomeningeal (infection, mets)
Brain Tumor	Primary* brain tumor (glioma)

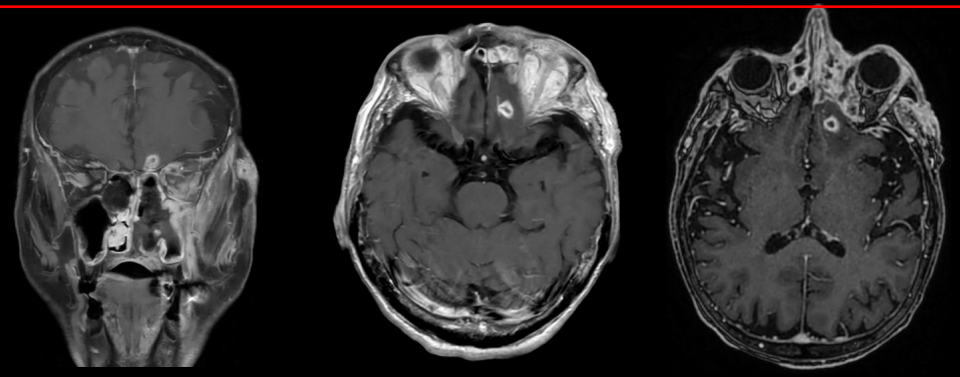

Cor T1 FS +C | Ax T1 +C | T1 MP-RAGE +C

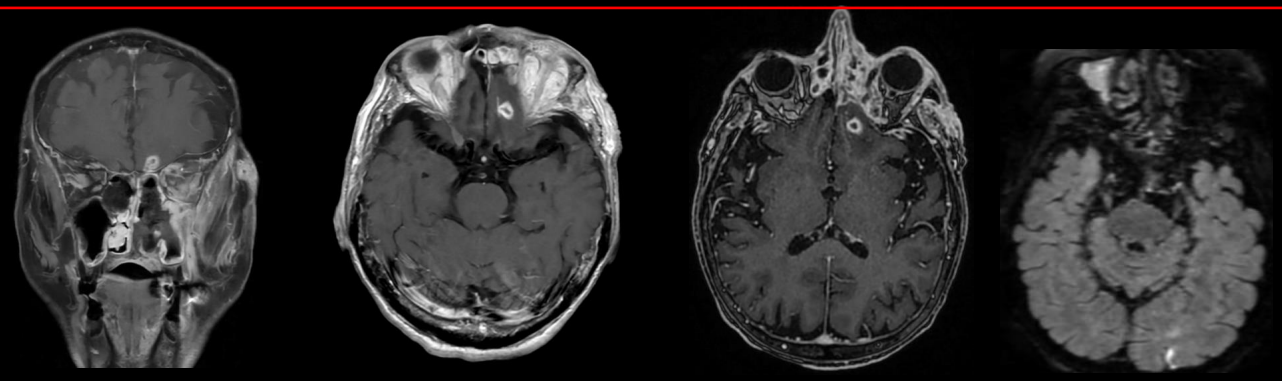

Cor T1 FS +C | Ax T1 +C | T1 MP-RAGE +C | T2 FLAIR CUBE +C

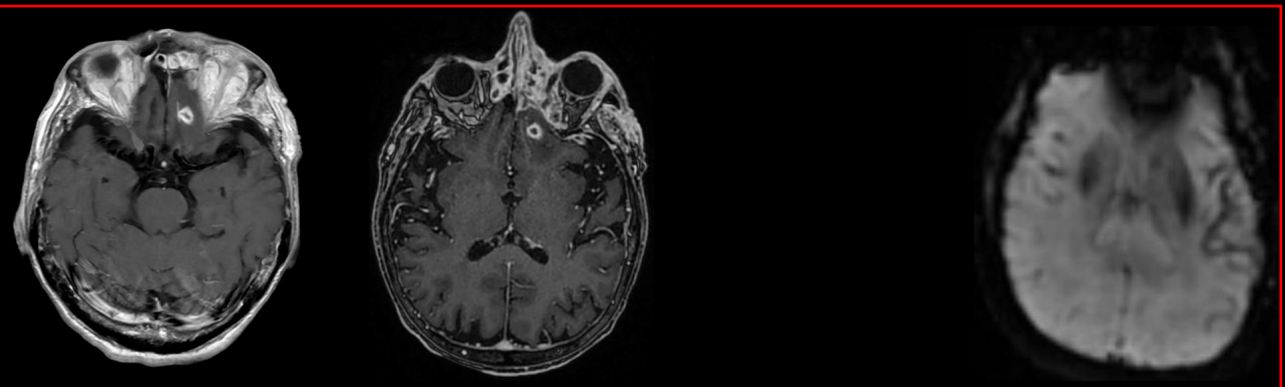

Ax T1 +C | T1 MP-RAGE +C | DSC Perfusion C+

Table of contents

Which of the following is NOT an indication for MRI spine survey?

A. Prostate Cancer
B. Trauma
C. Non-localized infection
D. Drop metastases

Table of contents

Which of the following is NOT an indication for MRI spine survey?

A. Prostate Cancer
B. Trauma
C. Non-localized infection
D. Drop metastases

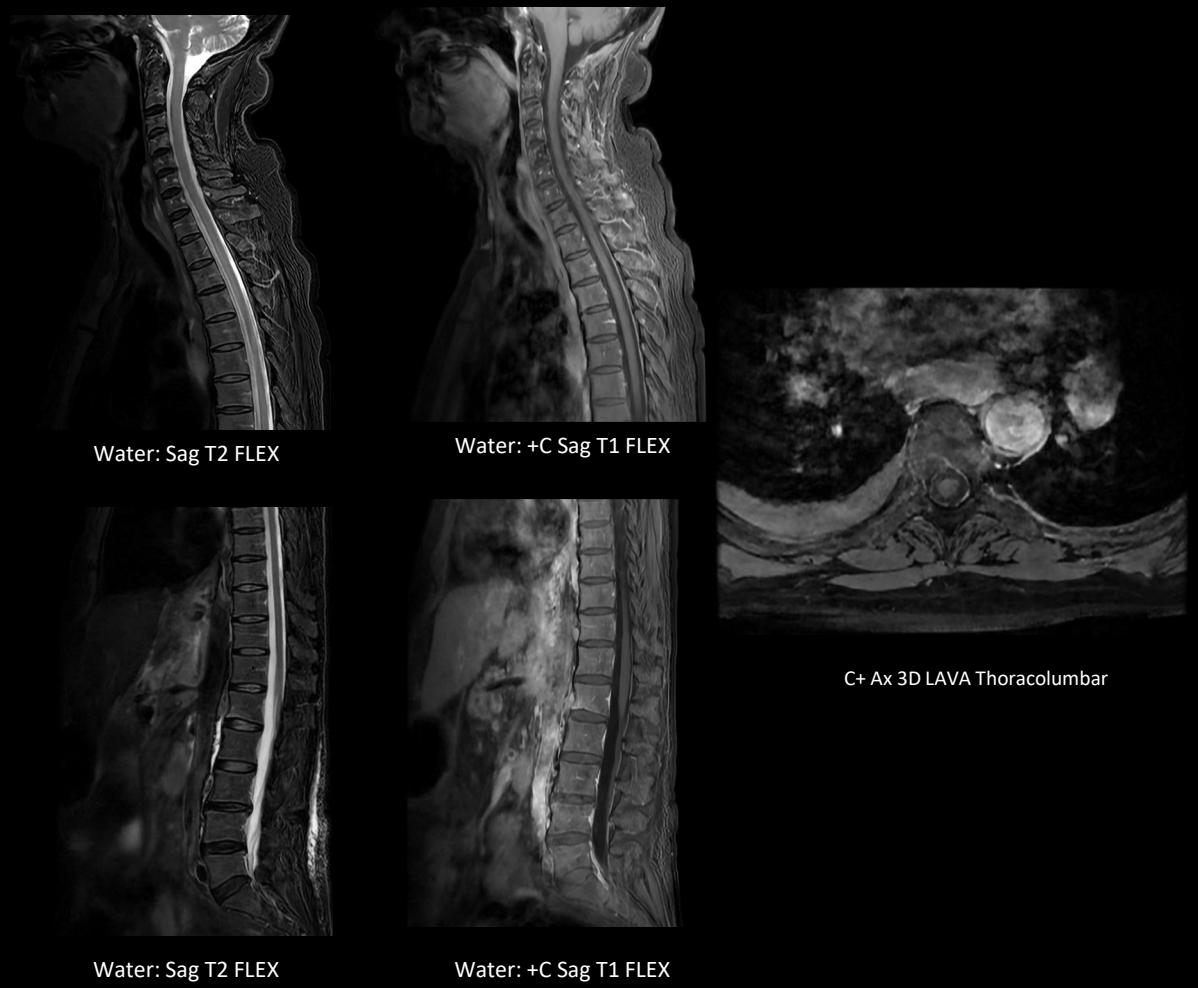

B. Trauma

Spine survey has large FOV and does not provide axial T2/T1 precontrast
Contrast unnecessary for trauma

Table of contents

Reason for exam: AMS with first time seizure

A. Brain WO
B. Brain WO/W
C. Epilepsy C+
D. More info

Table of contents

Reason for exam: AMS with first time seizure

A. Brain WO
B. Brain WO/W
C. Epilepsy C+
D. More info

Epilepsy imaging is best at high magnet strength 3T – no inpatient 3T scanner at JMC

Epilepsy imaging requires high-quality images and patient remaining still

Epilepsy protocol does NOT come with MP-RAGE

B. Brain WO/W

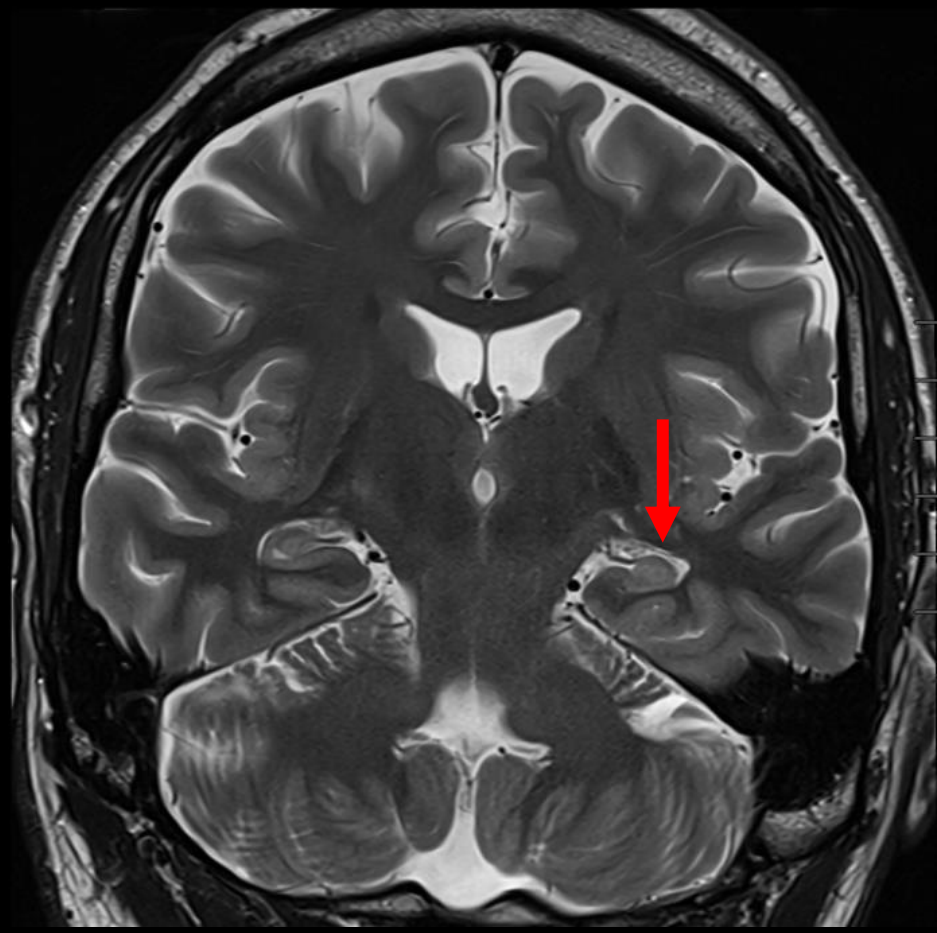

Table of contents

Reason for exam: Cervical spine fracture, C2

A. Cervical spine WO
B. Cervical spine CCJ
C. Spine Survey
D. Cervical Spine MS

Table of contents

Reason for exam: Cervical spine fracture, C2

A. Cervical spine WO
B. Cervical spine CCJ
C. Spine Survey
D. Cervical Spine MS

B. Cervical Spine CCJ

Table of contents

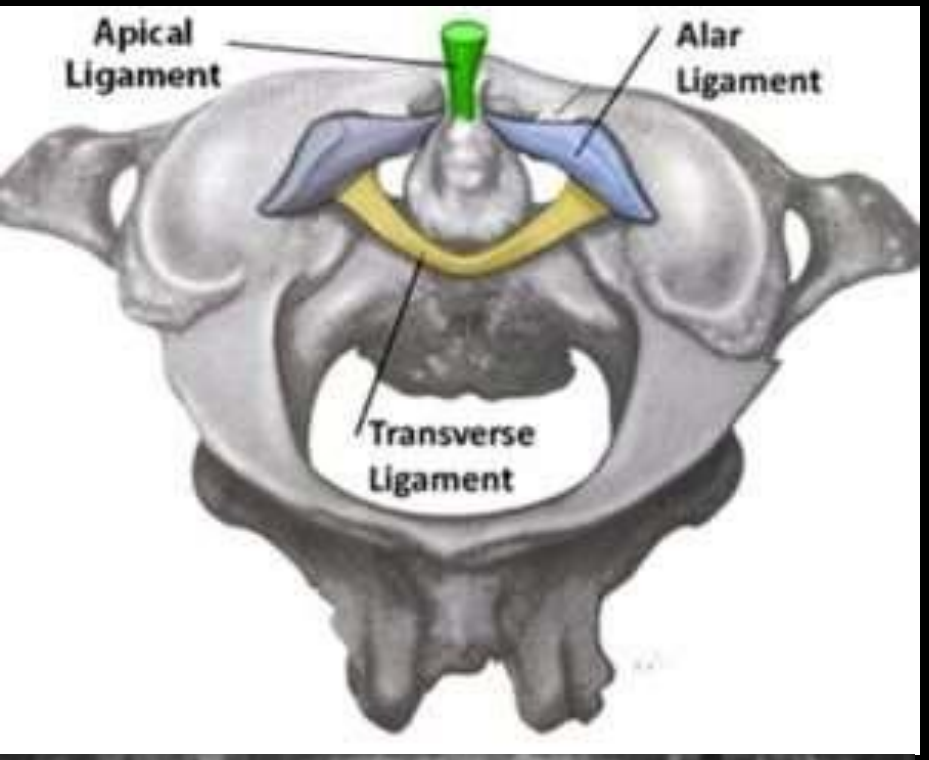

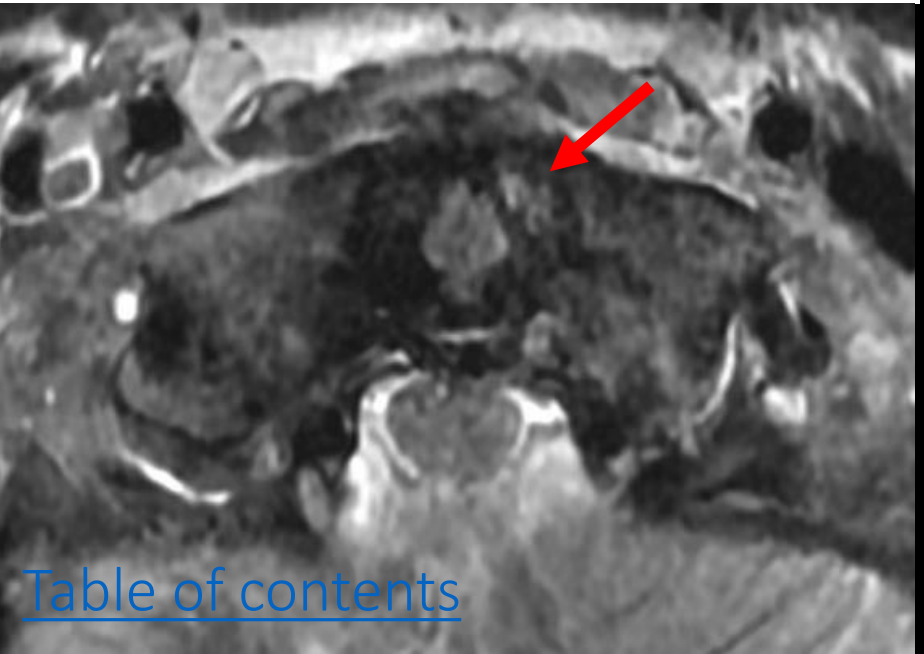

Table of contents

Reason for exam: Status post EEA, Dr. Beaumont protocol

A. Ant Skull Base + Sella
B. Brain C+
C. Maxillofacial C+
D. IAC C+

Table of contents

Reason for exam: Status post EEA, Dr. Beaumont protocol

A. Ant Skull Base + Sella
B. Brain C+
C. Maxillofacial C+
D. IAC C+

A. Ant Skull Base + Sella

Table of contents

Reason for exam: Lesion localizing to cavernous sinus

A. CT venogram
B. MRI Sella WO/W
C. MRI Orbits WO/W
D. MRI Brain Mets

C. MRI Orbits WO/W (OK to add MRI brain mets as it includes ASL)

Table of contents

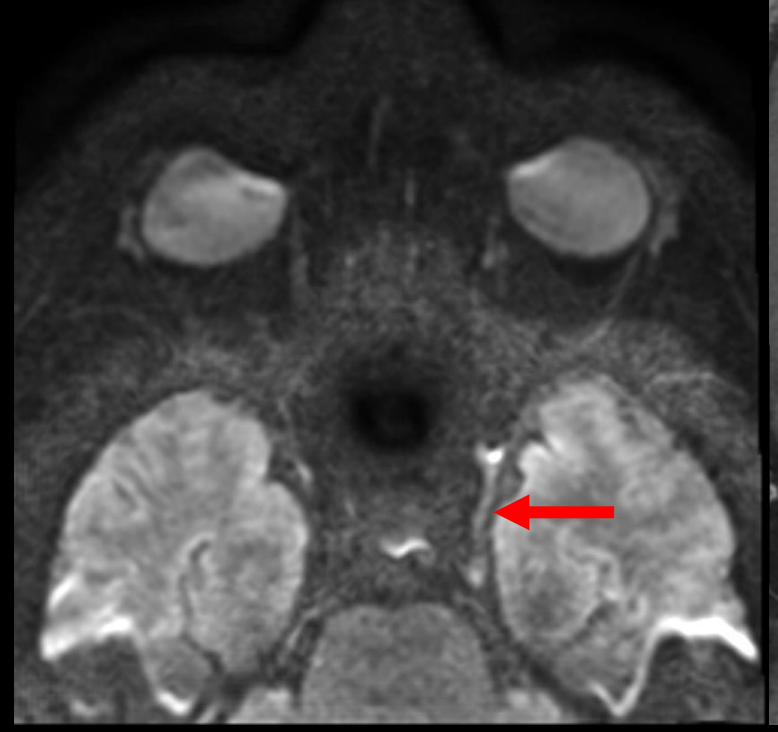

DWI MUSE

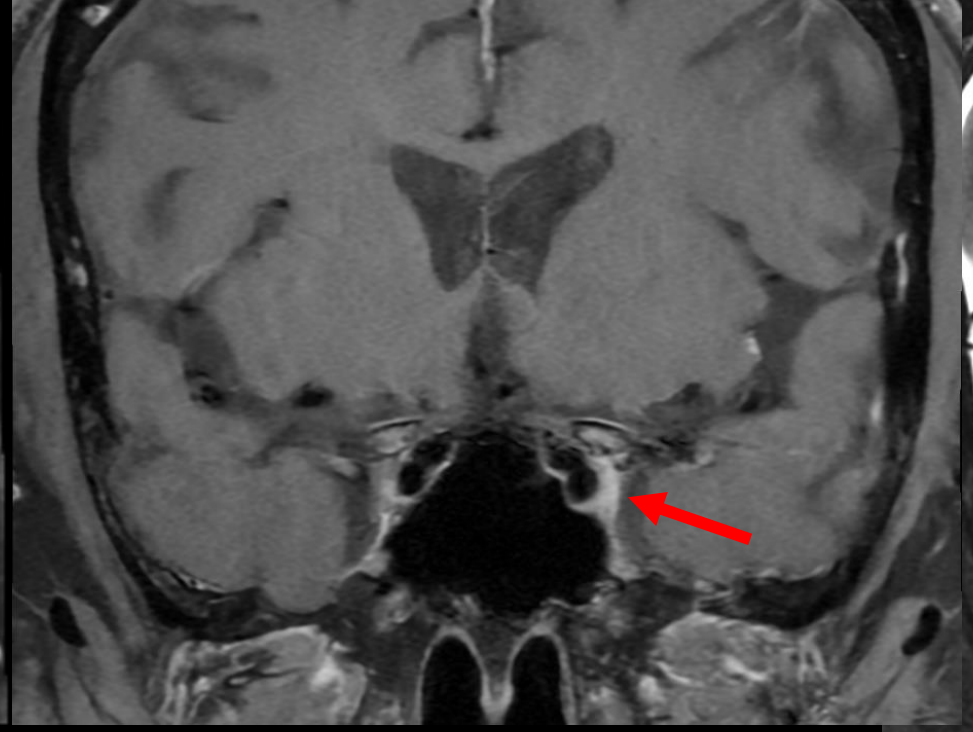

T1 C+

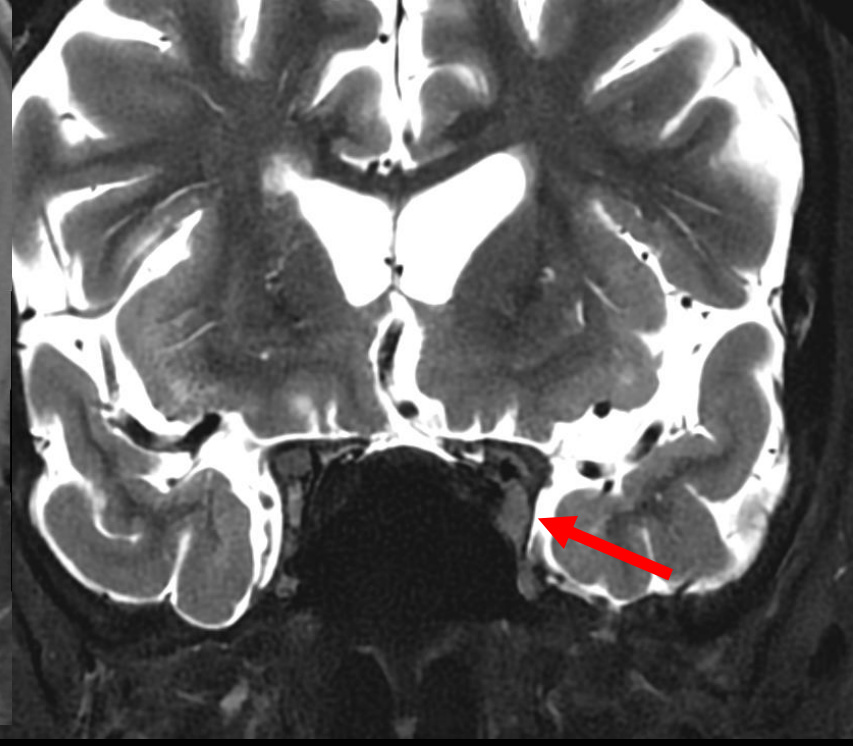

T2

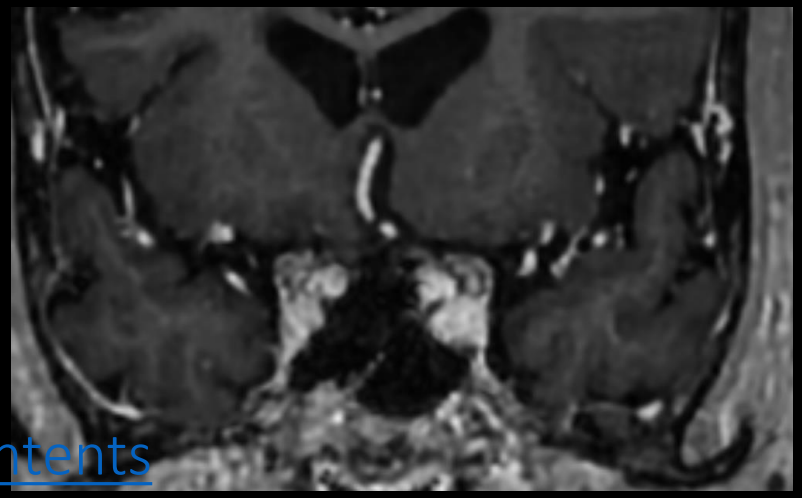

Lesion nearly invisible on MRI Brain MP-RAGE

Table of contents

Reason for exam: MRA with multifocal intracranial arterial narrowing. Concern for intracranial vasculitis.

A. CTA Head and Neck
B. MRI Brain C+
C. MR Vessel Wall Imaging (VWI)
D. MR Perfusion

Table of contents

Reason for exam: MRA with multifocal intracranial arterial narrowing. Concern for intracranial vasculitis.

A. CTA Head and Neck
B. MRI Brain C+
C. MR Vessel Wall Imaging (VWI)
D. MR Perfusion

C. MR Vessel Wall Imaging (VWI)

Table of contents

Vessel Wall Imaging Protocol

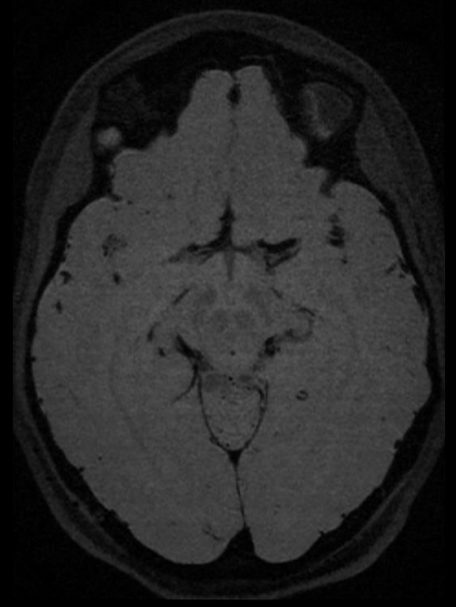

3D MDSE

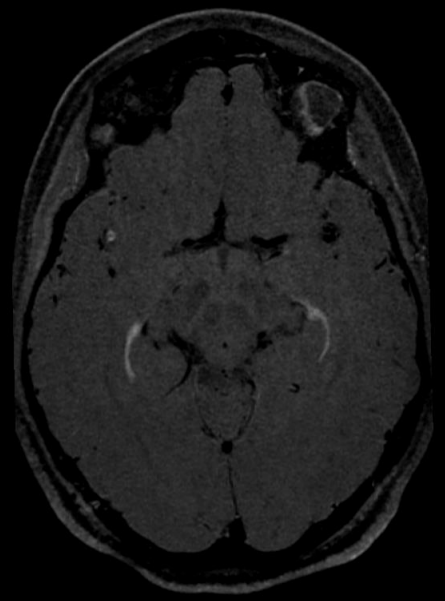

3D MDSE C+

MRA TOF

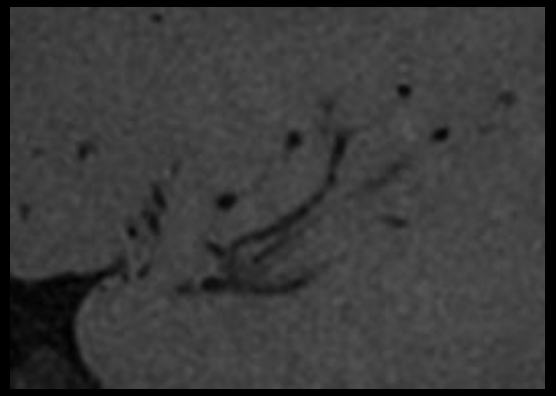

3D MDSE

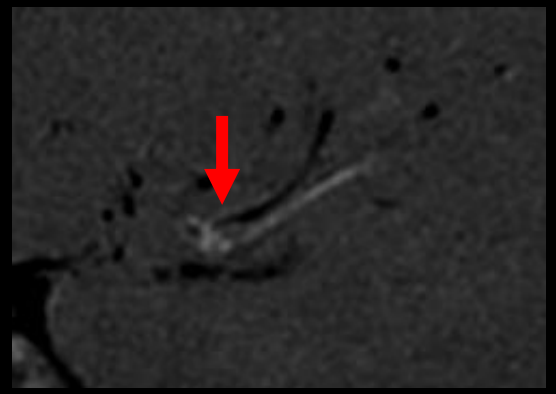

3D MDSE C+

MRA TOF

Enhancement patterns:

- Vasculitis – Concentric with positive remodeling
- ICAD – Eccentric
- Moyamoya – Concentric with negative remodeling
- RCVS – No enhancement

Table of contents

Circumferential vessel wall enhancement